www.realworldECGs.com

Podrid's Real-World ECGs

A Master's Approach to the Art and Practice of Clinical ECG Interpretation

Volume 2 Myocardial Abnormalities

Philip Podrid, MD · Rajeev Malhotra, MD, MS
Rahul Kakkar, MD · Peter A. Noseworthy, MD

Forewords by: Hein J. Wellens, MD · Roman DeSanctis, MD

cardiotext

Podrid's Real-World ECGs

A Master's Approach to the Art and Practice of Clinical ECG Interpretation

Volume 2 Myocardial Abnormalities

Podrid's Real-World ECGs

A Master's Approach to the Art and Practice of Clinical ECG Interpretation

Volume 2 Myocardial Abnormalities

Philip Podrid, MD

Professor of Medicine
Professor of Pharmacology and Experimental Therapeutics
Boston University School of Medicine

Lecturer in Medicine
Harvard Medical School
Boston, Massachusetts

Attending Physician
West Roxbury VA Hospital
West Roxbury, Massachusetts

Rajeev Malhotra, MD, MS

Instructor in Medicine
Cardiology Division
Massachusetts General Hospital
Harvard Medical School
Boston, Massachusetts

Rahul Kakkar, MD

Cardiology Fellow
Massachusetts General Hospital
Harvard Medical School
Boston, Massachusetts

Peter A. Noseworthy, MD

Cardiology Fellow
Massachusetts General Hospital
Harvard Medical School
Boston, Massachusetts

cardiotext PUBLISHING
Minneapolis, Minnesota

© 2013 Philip Podrid, Rajeev Malhotra, Rahul Kakkar, and Peter A. Noseworthy

Cardiotext Publishing, LLC
3405 W. 44th Street
Minneapolis, Minnesota, 55410
USA
www.cardiotextpublishing.com

Any updates to this book may be found at:
www.cardiotextpublishing.com/titles/detail/9781935395034

Comments, inquiries, and requests for bulk sales can be directed to the publisher at:
info@cardiotextpublishing.com.

All rights reserved. No part of this book may be reproduced in any form or by any means without the prior permission of the publisher.

All trademarks, service marks, and trade names used herein are the property of their respective owners and are used only to identify the products or services of those owners.

This book is intended for educational purposes and to further general scientific and medical knowledge, research, and understanding of the conditions and associated treatments discussed herein. This book is not intended to serve as and should not be relied upon as recommending or promoting any specific diagnosis or method of treatment for a particular condition or a particular patient. It is the reader's responsibility to determine the proper steps for diagnosis and the proper course of treatment for any condition or patient, including suitable and appropriate tests, medications or medical devices to be used for or in conjunction with any diagnosis or treatment.

Due to ongoing research, discoveries, modifications to medicines, equipment and devices, and changes in government regulations, the information contained in this book may not reflect the latest standards, developments, guidelines, regulations, products or devices in the field. Readers are responsible for keeping up to date with the latest developments and are urged to review the latest instructions and warnings for any medicine, equipment or medical device. Readers should consult with a specialist or contact the vendor of any medicine or medical device where appropriate.

Except for the publisher's website associated with this work, the publisher is not affiliated with and does not sponsor or endorse any websites, organizations or other sources of information referred to herein.

The publisher and the authors specifically disclaim any damage, liability, or loss incurred, directly or indirectly, from the use or application of any of the contents of this book.

Unless otherwise stated, all figures and tables in this book are used courtesy of the authors.

Cover design by Caitlin Crouchet Altobell and Elizabeth Edwards;
interior design by Elizabeth Edwards

Library of Congress Control Number: 2013930909

ISBN: 978-1-935395-03-4

Printed in the United States of America

These workbooks are dedicated first to my wife Vivian and son Joshua, whose patience, tolerance, support, and love over the years have been limitless, exceptional, and inspirational. They are also dedicated to the many cardiology fellows, house staff, and medical students whom I have had the pleasure and honor of teaching over the past three decades and who have also taught me so very much.

Philip Podrid

To my wife Cindy and daughter Sapna, for all their love, support, and encouragement.

Rajeev Malhotra

To my darling daughters, Mia and Eila, whom I love to infinity.

Rahul Kakkar

For Katie and Jack

Peter A. Noseworthy

Contents

Foreword
by Roman W. DeSanctis, MD ..... **ix**

Foreword
by Hein J. Wellens, MD ..... **xi**

Preface ..... **xiii**

Introduction
Myocardial Abnormalities **1**

Core ECGs
1–50 ..... **11**

Practice ECGs
51–92 ..... **233**

Index **411**

Foreword

The invention of the electrocardiogram (ECG) by Dr. Willem Einthoven, first reported in 1901, ranks as one of the all-time great discoveries in medicine. Einthoven's landmark achievement was duly recognized in 1924, when he was awarded the Nobel Prize in Medicine.

By the early 1940s, all of the components of the 12-lead ECG that we use today were in place. When I finished my cardiology training 50 years ago, the ECG was one of very few cardiodiagnostic tools available to us. As a result, we received an intensity of training in electrocardiography that is generally not encountered in many of today's cardiology fellowship programs, where the emphasis has shifted toward the newer high-tech diagnostic modalities. Yet the ECG remains a major pillar in the evaluation of disorders of the heart. In a patient with a cardiac arrhythmia, what diagnostic information does the treating physician want the most? Of course—the ECG. Although the medical world progresses rapidly and changes constantly, the body of knowledge surrounding the ECG is virtually timeless. What was true 50 years ago is largely true today, and will remain so 50 years from now.

This wonderful series of ECG workbooks, appropriately entitled "Real-World ECGs," by Dr. Philip Podrid and three outstanding young cardiologists from Massachusetts General Hospital—Dr. Rajeev Malhotra, Dr. Rahul Kakkar, and Dr. Peter Noseworthy—offers a splendid opportunity for self-education in electrocardiography (and a bit of fun at the same time). An esteemed academic cardiologist, Dr. Podrid has had a career-long interest in electrocardiography. Over many years he has collected and saved thousands of ECGs for teaching purposes, and it is a portion of his incredible collection that has been used to spawn these books.

There are scores of textbooks on electrocardiography, but what sets these volumes apart is that every ECG is tied directly to an actual clinical case. Each ECG is initially presented in a visually attractive and readable format accompanied by a clinical vignette. On the next page, the salient features of the ECGs are highlighted, dissected, and discussed in meticulous detail, followed by a summary of the patient's clinical problem and treatment, particularly as they relate to the ECG findings.

The first volume in this unique series covers electrocardiography basics. It is followed by five more volumes covering the entire spectrum of electrocardiography: myocardial abnormalities, conduction abnormalities, arrhythmias, narrow and wide complex tachycardias, and a sixth volume amalgamating a potpourri of paced rhythms, congenital abnormalities, and electrolyte disturbances. As I perused one of the workbooks, I truly enjoyed the experience. It is fun to try to guess the clinical problem from the ECG. In fact, on my teaching rounds, that is often exactly what I do. I will ask the trainee to present first just the ECG and with other trainees try to deduce from it what might be going on clinically. For example, in an adult with marked left ventricular hypertrophy and strain, one of three conditions is almost always present: severe aortic valve disease, hypertrophic cardiomyopathy, or hypertensive heart disease.

continues

These books should prove to be valuable for the teaching and learning of electrocardiography at all levels—from nursing and medical students to residents to cardiology fellows to practicing internists and cardiologists. They should be especially helpful for those seeking board certification or recertification in cardiovascular diseases, where knowledge of electrocardiography still is given a very high priority.

There is one further important dividend for those who utilize this series. In addition to the six workbooks, hundreds of other ECGs handled in a similar format are available online. From clinical diagnoses to interactive questions to patient management, realworldECGs.com offers ECG-centric clinical cases for the viewer to further master the art of ECG interpretation.

Anyone who reads these books and views the auxiliary electronic material cannot help but be impressed by the prodigious amount of work that went into their 272preparation. Drs. Podrid, Malhotra, Kakkar, and Noseworthy should be justifiably proud of the final results of their Herculean efforts. I am confident that other readers will find these books and their electronic supplement as informative and enjoyable as I did.

Roman W. DeSanctis, MD
Physician and Director of Clinical Cardiology, Emeritus
Massachusetts General Hospital
James and Evelyn Jenks and Paul Dudley White Professor of Medicine
Harvard Medical School

Foreword

The electrocardiogram (ECG) was born in the Netherlands at the beginning of the 20th century when physiologist Willem Einthoven made the first recording of the spread of electrical activity in the beating heart from the surface of the body in a living human being. Since then, the ECG has become the indispensable "workhorse" in the management of patients suspected to have a cardiac problem.

The reasons are obvious. An ECG can be obtained anywhere. A recording is easily and quickly made, noninvasive, inexpensive, reproducible, and patient-friendly. The ECG gives instantaneous diagnostic information, is essential in selecting appropriate management, and allows documentation of the effect of treatment in cases of acute and chronic cardiac ischemia, rhythm and conduction disturbances, structural changes in the cardiac chambers, electrolyte and metabolic disorders, medication effects, and monogenic ECG patterns indicating the likelihood of cardiac abnormalities. The ECG is also a valuable tool for epidemiologic studies and risk stratification of the cardiac patient.

In the 110 years during which the ECG has been in use, we have seen continual improvements in its value in light of information gleaned from other invasive and noninvasive diagnostic techniques, such as coronary angiography, intracardiac localization of abnormal impulse formation and conduction disturbances, echocardiography, MRI, and genetic evaluation. This means that not only does the novice health care professional need to be informed about all the information currently available from the ECG, but the more senior physician also needs to stay up-do-date with ever-evolving new developments.

Dr. Philip Podrid is known worldwide as an expert in electrocardiography. He is also a superb teacher. When you combine his input with beautiful ECGs, not surprisingly, you will have a series of "Real-World ECGs" that demonstrate the art and practice of clinical ECG interpretation as only a real master can. I hope that many readers will profit from this exceptional educational exercise.

Hein J. Wellens, MD
Professor of Cardiology
Cardiovascular Research Institute Maastricht
Maastricht, The Netherlands

Preface

The electrocardiogram (ECG) is one of the oldest technologies used in medicine and remains one of the most frequently obtained tests in the physician's office, outpatient clinic, emergency department, and hospital. ECGs continue to play an essential role in the diagnosis of many cardiac diseases and in the evaluation of symptoms believed to be of cardiac origin. The ECG is also important in the diagnosis of many noncardiac medical conditions.

Like any other skill in medicine, the art of ECG interpretation requires frequent review of the essentials of ECG analysis and continual practice in reading actual ECGs. However, many health care providers who wish to augment their expertise in the interpretation of ECGs and develop the skills necessary to understand the underlying mechanisms of ECG abnormalities have realized that the currently available resources do not adequately meet their needs.

Teaching in medical schools and house staff programs does not typically emphasize ECG analysis. Consequently, many physicians do not feel adequately trained in interpreting the ECG. The currently available textbooks used for teaching ECG analysis are based on pattern recognition and memorization rather than on understanding the fundamental electrophysiologic properties and clinical concepts that can be applied to an individual ECG tracing, regardless of its complexity. The physician is not, therefore, trained in the identification of important waveforms and subtle abnormalities.

The workbooks and website of *Podrid's Real-World ECGs* aim to fill the gap in ECG education. These unique teaching aids prepare students and health care providers of all levels for the spectrum of routine to challenging ECGs they will encounter in their own clinical practice by providing a broad and in-depth understanding of ECG analysis and diagnosis, including discussion of relevant electrophysiologic properties of the heart, associated case scenarios, and clinical management.

The Workbooks

Each of the six volumes in *Podrid's Real-World ECGs* teaches the art of ECG interpretation by careful analysis of specific examples and identification of important waveforms. Each ECG is taken from a real clinical case and incorporates a discussion of important diagnostic findings and essential associated electrophysiologic mechanisms, as well as critical clinical management decisions. The purpose of the series is to provide readers from all fields of medicine with a systematic approach to ECG interpretation using a concise, case-based format.

Volume 1 provides an essential introduction to the basics of ECG reading, outlining the approaches and tools that are utilized in the

continues

interpretation of all ECGs. Volume 2 discusses the diagnosis of hypertrophy of the atria and ventricles, acute myocardial ischemia, acute and chronic myocardial infarction, and pericarditis. The subsequent volumes focus on other disease entities for which the ECG is useful:

- Atrioventricular (AV) and intraventricular conduction disturbances and enhanced AV conduction
- Sinus, atrial, junctional, and ventricular arrhythmias
- Narrow and wide complex tachycardias and forms of aberration
- Recording methods and miscellaneous conditions, including pacemakers, electrolyte disorders, and acquired and congenital cardiac conditions

Each volume in the series starts with a didactic introduction that addresses the important ECG findings associated with each clinical category. This is followed by core illustrative case-based ECGs that lead the reader through identification of the important ECG findings associated with the specific abnormalities being discussed and provide information about the basic electrophysiologic mechanisms involved. This section is followed by a random assortment of topic-related ECGs and clinical scenarios to further enhance the student's skills at ECG analysis. Importantly, each case presentation is followed by an in-depth discussion of the ECG findings, with the important waveforms on the ECG highlighted.

The Website: realworldECGs.com

In addition to the didactic ECG cases found in the workbooks, the website (www.realworldECGs.com) offers easy access to a large, searchable repository of supplementary case-based ECGs. This ancillary material offers further practice in ECG interpretation using interactive case studies with Q&A that includes feedback and discussion about the important findings and clinical issues involved.

The benefit of a Web-based program is that many more ECGs can be presented and ECGs demonstrating specific abnormalities can be accessed quickly. In addition, the ECGs can be read using an approach that is similar to how they are analyzed in clinical practice—by identifying the waveforms important for diagnosis. Each of the relevant features is highlighted independently, providing a useful way to approach ECG reading.

This versatile Web-based program allows the user either to interpret ECGs in random fashion or to focus attention on a specific topic or ECG finding. This approach allows ECG interpretation to be performed in a way that is most effective for the user.

Philip Podrid, MD
Rajeev Malhotra, MD, MS
Rahul Kakkar, MD
Peter A. Noseworthy, MD

Introduction
Myocardial Abnormalities

The surface electrocardiogram (ECG) is often used to diagnose abnormalities of the atrial and ventricular myocardium, including hypertrophy, ischemia, infarction, and inflammation (myocarditis/pericarditis).

Hypertrophy

Left Ventricular Hypertrophy

A number of criteria have been proposed for diagnosing left ventricular hypertrophy (LVH) on the surface ECG (FIGURE 1). An important limitation is related to factors that may influence the transmission of the electrical impulse to the surface of the body, including body habitus (especially obesity), pulmonary disease, and pericardial thickening or effusion. Therefore, the ECG may not accurately reflect the presence of LVH.

The following criteria have been proposed for diagnosing LVH:

- S-wave depth in lead V1 or V2 + R-wave amplitude in lead V5 or V6 ≥ 35 mm (small boxes) if over age 45 or ≥ 45 mm if under age 45 (Sokolow-Lyon criterion)
- Deepest S wave + tallest R wave (in mm) in any two precordial leads ≥ 35 mm (or ≥ 45 mm if age under 45)
- S-wave depth or R-wave amplitude (in mm) in any one precordial lead ≥ 25 mm

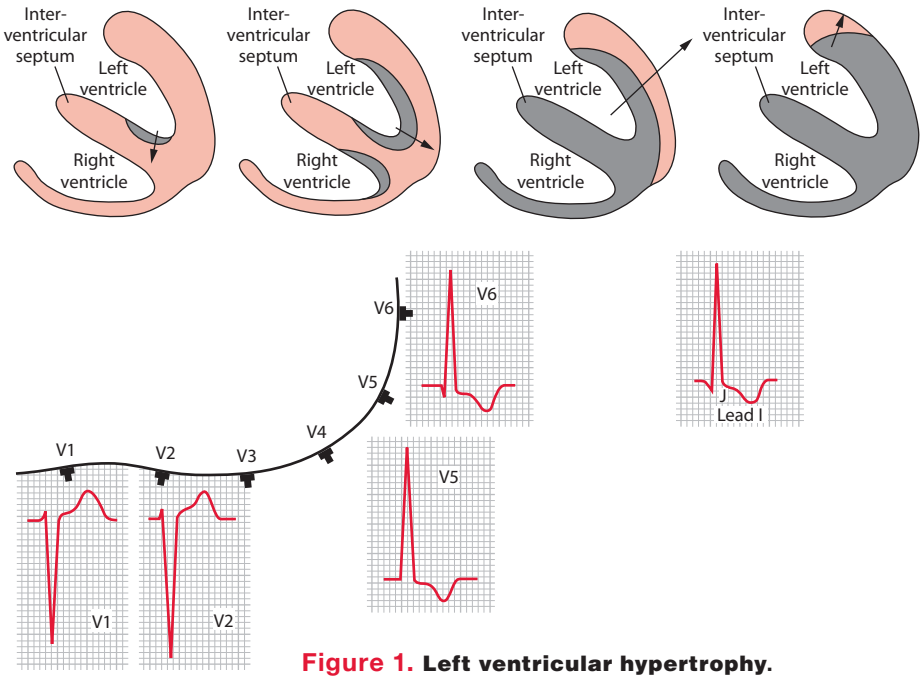

Figure 1. Left ventricular hypertrophy. Note the deep S wave in leads V1-V2 and the tall R wave in leads I and V5-V6 (which are due to left ventricular depolarization in these leads). The R wave may also be tall in the limb leads, especially lead aVL. The axis is often leftward. The *arrows* indicate the direction of ventricular activation. Left ventricular activation begins in the interventricular septum, going in a left-to-right direction. This is followed by left ventricular depolarization (apex, anterolateral, and high lateral wall) going in a right-to-left direction.

- R-wave amplitude in lead aVL ≥ 11 mm (≥ 18 mm in presence of left axis deviation) (Sokolow-Lyon criterion)
- R-wave amplitude in any one limb lead ≥ 20 mm
- R-wave amplitude in lead aVL + S-wave depth in lead V3 ≥ 28 mm for men or ≥ 20 mm for women (Cornell criteria)

The voltage criteria are based on the ECG recorded at normal standardization (*ie*, 1 mV = 10 mm or 10 small boxes in height). If the ECG is recorded at half-standard (*ie*, 1 mV = 5 mm or five small boxes), the measured QRS amplitude is half of the actual value and hence the number is doubled. If the ECG is recorded at double standard (*ie*, 1 mV = 20 mm or 20 small boxes), the measured QRS amplitude is twice normal and the number must be reduced by half.

LVH may be associated with other changes on the ECG as well, including:

- Intraventricular conduction delay (IVCD) due to slow activation of the thickened myocardium
- Delay or a slurring in the upstroke of the QRS complex. This is called delayed intrinsicoid deflection, which is measured from the beginning of the QRS complex to the peak of the R wave. An intrinsicoid deflection longer than 0.05 second is considered delayed.
- Physiologic left axis deviation, between 0° and –30° (positive QRS complex in leads I and II and negative QRS complex in lead aVF)
- Left atrial hypertrophy (or abnormality), called a P mitrale, defined as a P wave that is broad (> 0.12 sec in duration) and notched (with a tall second component). In lead V1, and often in lead V2, the P wave is entirely negative (rather than biphasic).
- Associated ST-T wave abnormalities (*ie*, J-point and ST-segment depression and/or T-wave inversions), which represent repolarization abnormalities, most likely due to subendocardial ischemia. These abnormalities are most often seen leads I, aVL, and V4-V6. The ST-T wave changes often seen with LVH have been called a "strain pattern." However, they actually reflect repolarization abnormalities as a result of subendocardial ischemia. The last part of the myocardium to receive blood supply (or oxygen supply) is the subendocardium. When LVH is present, the blood supply to the subendocardium may be limited and reduced; hence it is chronically ischemic.
- J-point and ST-segment elevation, termed early repolarization, which is most often seen in leads V4-V6. This may be seen when the QRS complex voltage is increased, even if LVH is not present.

As indicated, QRS amplitude is affected by a number of conditions; therefore, LVH may be present even if QRS amplitude criteria are not met but other associated changes are seen. This is the basis for the Romhilt-Estes scoring system, which assigns a point score to various ECG abnormalities seen with LVH.

Romhilt-Estes Scoring System

Romhilt-Estes Criterion	Points
R-wave height or S-wave depth in any limb lead ≥ 20 mm	3
OR	
S-wave depth in lead V1 or V2 ≥ 30 mm	
OR	
R-wave height in lead V5 or V6 ≥ 30 mm	
ST-T wave changes typical of LVH	
Taking digoxin	1
Not taking digoxin	3
Left atrial hypertrophy	
(terminal force in lead V1 ≥ 1 mm in depth and > 0.04 sec in duration)	3
Left axis deviation (< –30°)	2
QRS duration ≥ 90 ms (*ie*, IVCD)	1
Intrinsicoid deflection in lead V5 or V6 > 0.05 sec	1

A point score of ≥ 5 indicates definite LVH; a point score of 4 is probable LVH.

Right Ventricular Hypertrophy

The mass of the left ventricular myocardium is far greater than that of the right ventricle. Hence the QRS complex primarily reflects depolarization of the left ventricular myocardium. Since depolarization occurs simultaneously in the left and right ventricles, manifestations of right ventricular depolarization are not usually seen. However, evidence of right ventricular depolarization may be seen when there is a significant increase in right ventricular myocardial mass (*ie*, right ventricular hypertrophy, RVH). The diagnosis of RVH can be established on the surface ECG, although as with LVH, the absence of evidence of RVH on the surface ECG does not exclude its presence (FIGURE 2).

The criteria for RVH include:

- R-wave amplitude (in mm) in lead V1 > 7 mm
- R/S ratio in lead V1 > 1
- S/R ratio in lead V6 (or V5) > 1

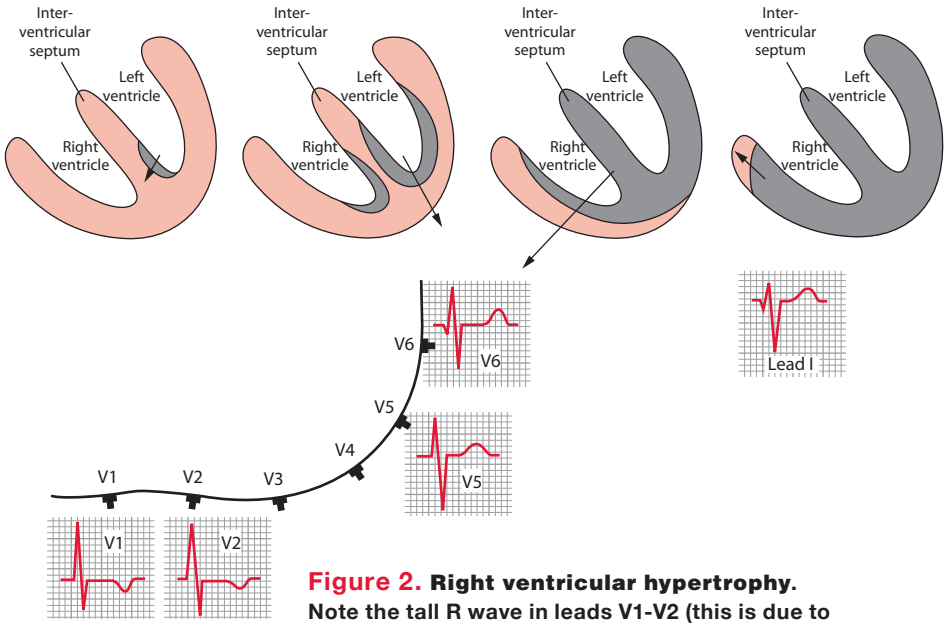

Figure 2. Right ventricular hypertrophy. Note the tall R wave in leads V1-V2 (this is due to right ventricular depolarization, which is augmented by the RVH) and the deep S wave in leads I and V5-V6 (this is due to the last part of ventricular activation, which is directed from left to right as a result of RVH). The axis is often rightward. The *arrows* indicate the direction of ventricular activation. Left ventricular activation begins in the interventricular septum, which goes in a left-to-right direction. This is followed by early activation of the left ventricle going from right to left. However, as a result of RVH, the terminal portion of ventricular activation goes from left to right.

Other ECG findings may help confirm the diagnosis:

- Right axis deviation (≥ +90°)
- Right atrial hypertrophy (or abnormality), termed P pulmonale. This is identified by a P wave that is narrow, tall, and peaked in the limb leads (> 2.5 mm of height in lead II) and primarily positive in lead V1 (and often V2).
- Associated ST-T wave abnormalities in leads V1-V3. As with LVH, ST-T wave abnormalities represent chronic ischemia of the subendocardial layer of the right ventricle.

However, other causes for a tall R wave in lead V1 need to be considered and excluded before diagnosing RVH. These include a posterior wall myocardial infarction (MI, usually associated with an inferior wall MI), Wolff-Parkinson-White pattern (short PR interval and widened QRS-delta wave), hypertrophic cardiomyopathy (septal hypertrophy with prominent septal Q waves in other leads), early transition (counterclockwise rotation), Duchenne muscular dystrophy (posterolateral infarction pattern), dextrocardia (reverse R-wave progression in leads V1-V6, right axis deviation, negative P wave in lead I), lead switch (leads V1, V2, V3), recording of right-sided leads (reverse R-wave progression in leads V1-V6), and a normal variant.

Normal P Wave

The P wave reflects depolarization of the right followed by the left atrium (FIGURES 3, 4, AND 5). When the impulse is generated by the sinus node, the direction of transmission is from right to left and from the arms to the legs (downward direction), and the normal P wave is positive (upright) in leads I, II, aVF, and V5-V6 and negative in lead aVR. There is often a slight notch, reflecting right followed by slightly delayed left atrial depolarization. The P-wave duration is 0.12 second or less, and the amplitude is usually 0.25 mV (2.5 small boxes) or less. The P wave is often biphasic (positive–negative) in lead V1 (FIGURE 4). Since lead V1 sits over the right ventricle and right atrium, the initial portion is positive, reflecting right atrial depolarization going toward lead V1 (positive) and then left atrial depolarization going away from lead V1 (negative).

Left Atrial Hypertrophy/Abnormality

When left atrial hypertrophy (or a left atrial conduction abnormality) is present, the P wave is broad (≥ 0.12 sec) with prominent notching, reflecting depolarization of the right atrium followed by delayed depolarization of the hypertrophied left atrium. The left atrial waveform (second component of the P wave) has an increased amplitude,

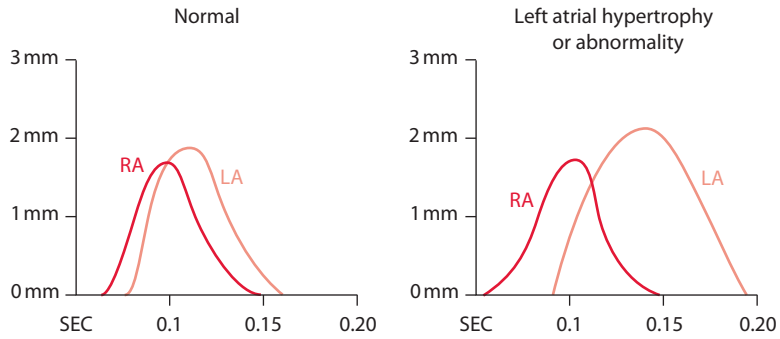

Figure 3. The P wave in left atrial hypertrophy (or abnormality) is broad and notched. This is due to delayed activation of the left atrium as well as an increased amplitude of the waveform as a result of the hypertrophy. This is termed P mitrale.

reflecting the hypertrophy (FIGURES 3 AND 4). This has been termed P mitrale. It is seen in conditions that cause left atrial hypertrophy, such as systemic hypertension, aortic stenosis, or mitral valve disease (especially mitral stenosis).

Also seen with left atrial hypertrophy is a P wave in lead V1 that is predominantly negative (*ie*, left atrial forces going away from lead V1) (FIGURE 4); a prominent negative component of the P wave may be seen also in leads V2-V3.

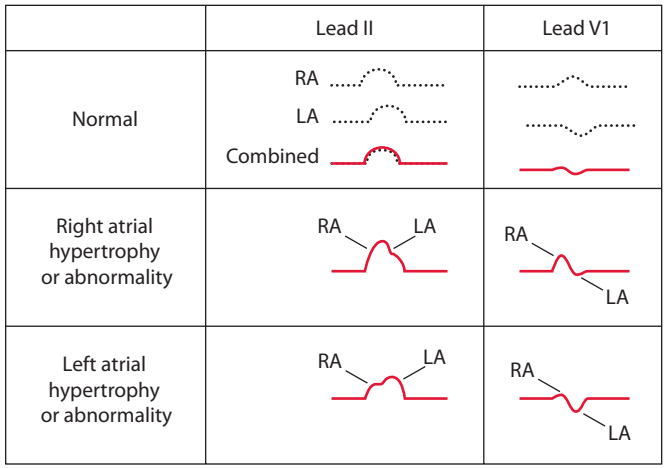

Figure 4. Appearance of the P wave in leads II and V1 in right and left atrial hypertrophy. The normal P wave in lead V1 is biphasic as the initial force (depolarization) is from the right atrium, going toward lead V1 (and hence a positive deflection), while left atrial depolarization is slightly later, going away from lead V1 and hence generating a negative waveform. With right atrial hypertrophy or abnormality, the depolarization is primarily toward lead V1, thereby generating a positive waveform. With left atrial hypertrophy or abnormality, the depolarization is primarily away from V1, thereby generating a negative waveform.

Right Atrial Hypertrophy/Abnormality

With right atrial hypertrophy, depolarization of the hypertrophied right atrium is delayed, occurring simultaneously with left atrial depolarization. The superimposed atrial waveforms result in a P wave that is narrow, tall, and peaked as the right atrial waveform has an increased amplitude, reflecting the hypertrophy (FIGURES 4 AND 5). This has been termed P pulmonale. The etiology is either right-sided valvular disease or pulmonary artery hypertension (primary or secondary from lung disease or left ventricular abnormalities).

Also seen with right atrial hypertrophy is a P wave in lead V1 that is predominantly positive (due to a right atrial impulse that is directed toward lead V1) (FIGURE 4); this P-wave morphology may also be seen in lead V2.

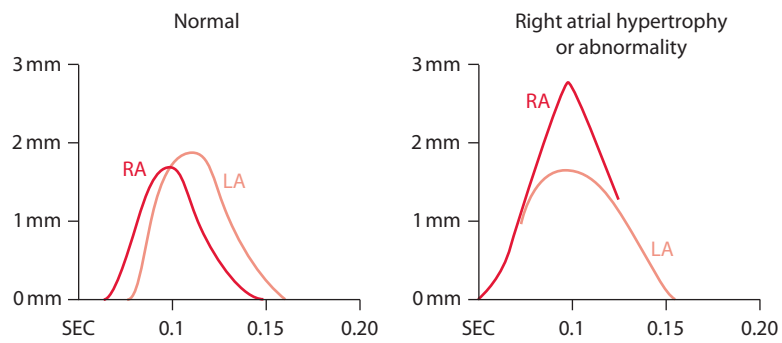

Figure 5. The P wave in right atrial hypertrophy (or abnormality) is tall, narrow, and peaked. This is due to delayed activation of the right atrium and activation is superimposed on left atrial activation. As there is increased muscle mass, the amplitude of the right atrial waveform is also increased. This is termed P pulmonale.

Low QRS Complex Voltage

Low QRS complex voltage is defined as a QRS amplitude ≤ 5 mm in each limb lead and/or ≤ 10 mm in each precordial lead. The low voltage reflects reduced electrical activity measured at the surface of the body and may be due to loss of myocardial muscle mass, pericardial effusion, thickened pericardium, lung disease, or obesity.

ST-segment Changes

The normal ST segment is slightly concave and is at baseline, which is always the TP segment. ST-segment flattening is a nonspecific change. ST-segment depression or ST-segment elevation is of importance.

J-point and ST-segment depression (upsloping, horizontal, downsloping) are due to ischemia of the subendocardium, which is the first part of the myocardium to become ischemic. There are a number of causes of J-point and ST-segment elevation:

- *Transmural ischemia:* ST-segment elevation in the absence of Q waves; in the presence of Q waves (indicating a prior transmural MI), ST-segment elevation most likely indicates a wall motion abnormality
- *Acute MI:* Localized ST-segment elevation; reciprocal ST-segment depressions may be seen in other leads (*ie*, the ST-segment change viewed from another direction); hyperacute T waves (tall, peaked, and symmetric) are often present
- *Aneurysmal segment:* Persistent ST-segment elevation after an MI
- *Pericarditis:* Diffuse concave ST-segment elevation in all or most leads; there are no reciprocal ST-segment changes and the T waves are normal (asymmetric)
- *Early repolarization:* Most common in left precordial leads V4-V6; early repolarization is seen in healthy individuals as a normal variant, with LVH, or when there is high QRS voltage; ST segments are concave and T waves have normal morphology.

Mechanism for ST-segment Changes

The ST-segment depression associated with subendocardial ischemia is actually caused by elevation of the baseline TP segment, which is the baseline or isoelectric plane. Under normal situations, this segment is at zero potential as it represents a period of time between QRS complexes when there is no movement of electrical current. With subendocardial ischemia, there is a loss of membrane integrity and leakage of potassium from the cell to the extracellular region, moving down its concentration gradient. As a result, the resting membrane potential becomes less negative, or more positive. The remaining portion of the myocardium is normal, with a resting membrane potential of –90 mV. Since current travels from positive to negative voltage, the ischemic region generates electrical currents that travel away from this region and toward the overlying normal epicardial myocardium. The net effect is that there are positive currents directed toward the overlying electrode, which will result in elevation of the baseline or TP segment. With depolarization at the time of the QRS complex generation, the entire myocardium becomes depolarized, and hence the ST segment is at zero potential or voltage. When compared with the elevated TP segment, it appears that there is ST-segment depression.

When transmural ischemia is present, as occurs with a Q-wave MI, there is a similar loss of membrane integrity and leakage of potassium ions from the cell to the extracellular region, moving down its

concentration gradient. As a result, the resting membrane potential becomes less negative, or more positive, in the injured tissue. The adjacent normal myocardium has a normal resting membrane potential of –90 mV. Since current travels from positive to negative voltage, the ischemic region generates positive currents that travel away from the entire ischemic region toward the normal myocardium. Hence the electrical current travels away from the overlying electrode. In this situation the baseline voltage, and hence the TP segment, will be more negative (*ie*, there will be depression of the TP segment) in the leads overlying the injured myocardium. With depolarization at the time of the QRS complex, the entire myocardium becomes depolarized, and hence the ST segment is at zero potential or voltage. When compared with the depressed TP segment, it appears that there is ST-segment elevation.

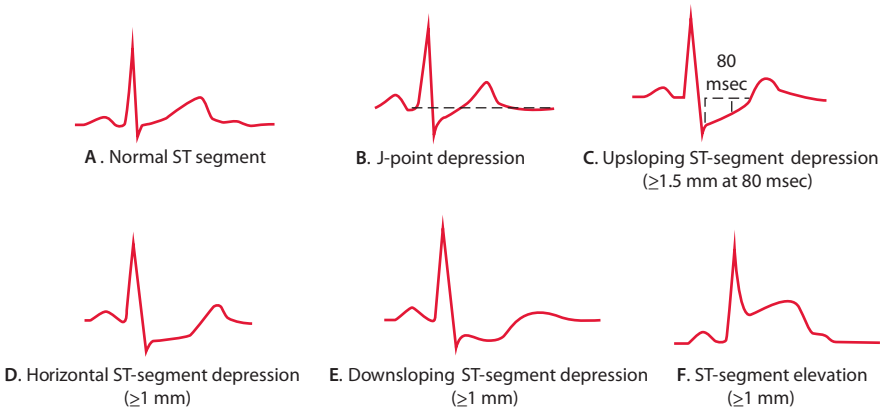

Figure 6. Types of ST segment shifts. (A) Normal ST segment. The normal J point and ST segment are at baseline, which is established by the TP segment (*ie*, from the T wave of the preceding complex to the P wave). (B) A depressed J point. (C) Upsloping ST-segment depression; the J point is depressed and the ST segment slopes upward toward baseline. (D) Horizontal ST-segment depression; the J point is depressed and the ST segment is flat or horizontal. (E) Downsloping ST-segment depression; the J point is depressed and the ST segment slopes downward. (F) ST-segment elevation; the J point and ST segment are above the baseline TP segment.

Myocardial Ischemia

Myocardial ischemia (regardless of etiology) is diagnosed by the presence of J-point and ST-segment depression, which reflects subendocardial ischemia. Since myocardial blood flow is from epicardium to endocardium, the subendocardium is the last layer to receive blood. As a result, it is the first part of the myocardium to become ischemic when there is an increased oxygen demand or reduced oxygen supply. The ST segment is compared with the baseline or 0 potential on the ECG (*ie*, TP segment). If the TP segment is not obvious (as may happen with a sinus tachycardia where the T wave and P wave merge), the PR segment can be used. Three types of ST-segment depression may be seen (FIGURE 6):

- *Upsloping ST-segment depression*. Upsloping ST-segment depression is the least specific for ischemia as it may be a normal finding during sinus tachycardia. It should be remembered that atrial repolarization (*ie*, the T wave of the P wave) occurs during the QRS complex and hence is normally not seen. However, when the sinus rate increases the PR segment shortens (due to sympathetic enhancement of conduction through the atrioventricular [AV] node) and this causes the T wave of the P wave to move out from the QRS complex and become superimposed on the J point, causing both the J point and ST segment to be depressed. The ST segment, therefore, slopes upward to return to baseline. Hence when upsloping ST-segment depression is present, it is standard practice to evaluate the degree of ST-segment depression present

at 80 msec (two small boxes) past the J point, which eliminates any effect from the atrial T wave on the J point and ST segment. If the ST segment at 80 msec past the J point is still depressed 1.5 mm or more below baseline (the TP segment or, if not obvious, the PR segment), then subendocardial ischemia is likely present.

- *Horizontal ST-segment depression*. The J point and ST segment are depressed (≥ 1 mm below baseline) and are flat thereafter.
- *Downsloping ST-segment depression*. The J point is depressed below baseline (≥ 1 mm), and the ST segment slopes downward. This is the most specific pattern for ischemia.

Although the usual criterion for ischemia is ST-segment depression more than 1 mm below baseline, specificity for ischemia increases as the degree of ST-segment depression increases. However, sensitivity for the diagnosis of ischemia decreases. In addition, specificity increases with an increased number of leads showing ST-segment depression. The location of ischemia based on the leads that show ST-segment depression does not always identify the region of subendocardium involved.

Myocardial Infarction

Acute Infarction

Acute infarction is the result of a total cessation of blood flow and oxygen supply to the myocardium. This causes loss of membrane integrity and loss of the normal sodium–potassium–ATPase pump, which is energy dependent and requires an oxygen supply. Potassium leaks out of the cell, based on its electrochemical gradient (intracellular potassium levels are normally higher than extracellular levels as maintained by this ATPase pump). Since there is no blood flow into or out of the region of infarction, potassium remains in this area, producing local hyperkalemia.

Therefore, the earliest change with a transmural or ST-segment elevation MI (STEMI) is a hyperacute (tall, peaked, and symmetric) T wave seen in the area of the involved myocardium (FIGURE 7). The hyperacute T wave occurs even before there are any ST-segment changes (if the ECG is obtained shortly after the onset of symptoms). Thereafter, the ST segment begins to elevate, maintaining its normal concave morphology; hyperacute T waves are still present. The ST segment elevates farther and is still concave; hyperacute T waves are also still present. ST segments continue to elevate and become convex, merging with the T wave. The amplitude of the R wave decreases. When the ST segment and T waves merge and the R wave is no longer obvious, the complex has the morphology of a "current of injury." It resembles the fast, sodium ion–mediated action potential. This ECG pattern of an acute infarction has been referred to as "tombstoning," as the QRS complex looks like a tombstone. The ST segment begins to return to baseline, Q waves develop, and T waves begin to invert, resulting in a chronic infarct pattern (*ie*, Q-wave and T-wave inversion). In addition to ST-segment elevation, there are reciprocal changes (*ie*, ST-segment depressions in other leads). This actually represents the ST-segment elevation observed from another angle. Persistent ST-segment elevation, present weeks to years after an acute event, indicates the presence of an aneurysm in the area of the previous infarction.

The location of these changes identifies the region of the myocardium involved; it may not identify which coronary artery is the "culprit":

- *Inferior wall MI*: ST-segment elevation in leads II, III, and aVF. The right ventricle is often involved in an inferior wall MI; this is suggested by the presence of ST-segment elevation in lead V1 and ST-segment depression in lead aVR (which actually represents ST-segment elevation) and is confirmed by obtaining right-sided leads and seeing ST-segment elevation in right-sided leads V3R-V4R. There may also be involvement of the posterior wall, which is suggested by the presence of ST-segment depression in leads V1-V2. Posterior leads placed on the back below the left scapula (V7-V8) showing ST-segment elevation help support the diagnosis of a posterior wall MI.
- *Anteroseptal MI*: ST-segment elevation in leads V1-V2
- *Anteroapical MI*: ST-segment elevation in leads V3-V4
- *Anterolateral MI*: ST-segment elevation in leads V5-V6
- *Anterior wall MI*: ST-segment elevation in two or more contiguous leads across the precordium (*ie*, leads V1-V6)
- *Lateral MI*: ST-segment elevation in leads I and aVL

Chronic Infarction

A chronic or old MI is identified by the presence of abnormal Q waves, defined as any Q wave in leads V1-V3 or a Q wave in leads I, II, aVF, or V4-V6 (in two or more contiguous leads) that is 0.04 second or longer

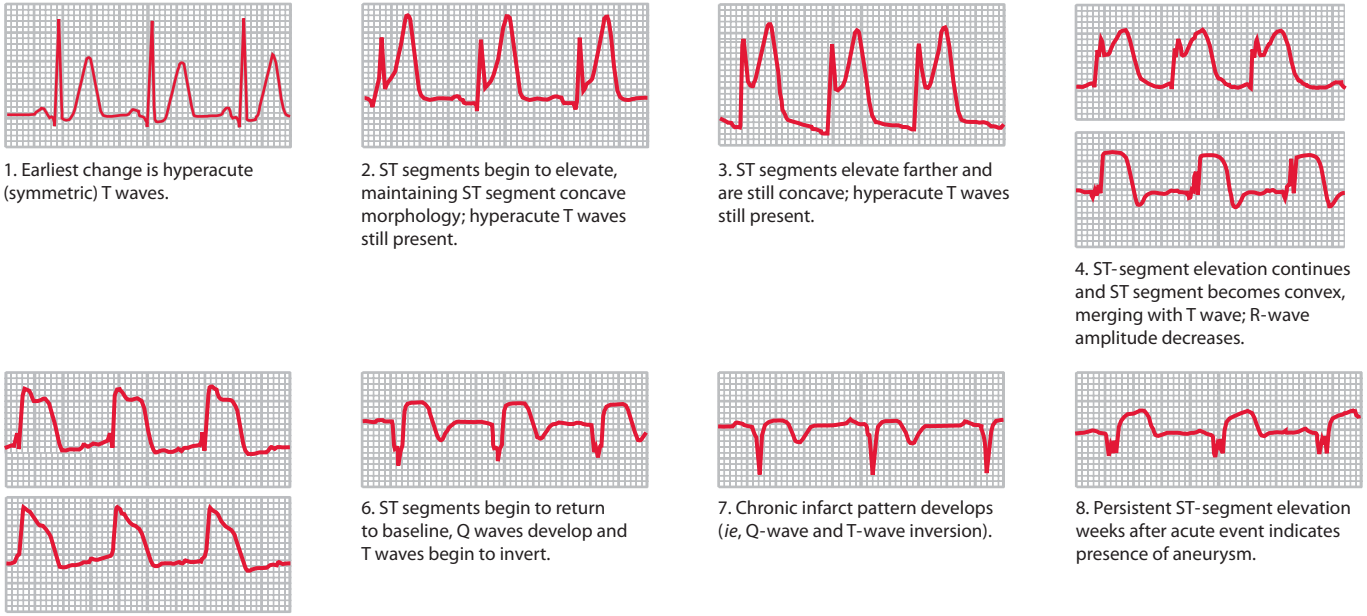
1. Earliest change is hyperacute (symmetric) T waves.
2. ST segments begin to elevate, maintaining ST segment concave morphology; hyperacute T waves still present.
3. ST segments elevate farther and are still concave; hyperacute T waves still present.
4. ST-segment elevation continues and ST segment becomes convex, merging with T wave; R-wave amplitude decreases.
5. ST segments and T waves merged; R wave lost; complex has morphology of a "current of injury" and resembles the fast action potential.
6. ST segments begin to return to baseline, Q waves develop and T waves begin to invert.
7. Chronic infarct pattern develops (*ie*, Q-wave and T-wave inversion).
8. Persistent ST-segment elevation weeks after acute event indicates presence of aneurysm.

Figure 7. Evolutionary changes in myocardial infarction. The first abnormality seen is hyperacute T waves. This is followed by ST-segment elevation; the ST segments remain concave (the normal morphology). As the ST segments elevate farther, they become convex, merging with the T wave. The R wave disappears. Thereafter, the ST segment begins to return to baseline with the development of a Q-wave and T-wave inversion. Ultimately, the ST segment is at baseline, with Q-wave and T-wave inversion, which represents a chronic infarction pattern. Persistent ST-segment elevation after the infarction indicates the development of a ventricular aneurysm.

in duration (or, as per new guidelines ≥ 0.03 sec, which is difficult to measure) and at least 1 mm in depth. However, Q waves may be normal and are ignored in lead III (unless they are also in leads II and aVF), in lead V1 (unless also in lead V2), and in lead aVL (unless Q-wave depth ≥ 50% R-wave height). A QS complex in leads V1-V2 may also be normal variant, especially in women.

T-wave inversions are usually present in the leads showing Q waves. ST-segment elevation that persists for more than a few weeks after the acute infarction suggests an aneurysm of the involved wall. The location of Q waves identifies the region of the left ventricle that is involved, but not necessarily the vessel that is occluded:

- *Inferior wall MI*: Q waves in leads II, III, and aVF
- *Anteroseptal MI*: Q waves in leads V1-V2
- *Anteroapical MI*: Q waves in leads V3-V4
- *Anterolateral MI*: Q waves leads V5-V6
- *Anterior wall MI*: Q waves in two or more contiguous precordial leads
- *Lateral MI*: Q waves in leads I and aVL
- *Posterior MI*: Tall R wave in lead V1 (R-wave amplitude > 7 mm or R/S > 1) with a duration of 0.04 second or longer (or ≥ 0.03 sec). This is typically seen in association with inferior wall MI, although there may be a true posterior wall MI in which there is no inferior wall involvement. However, other abnormalities associated with a tall R wave in lead V1 need to be considered, including evidence of RVH (usually associated with a right axis deviation and right atrial hypertrophy), Wolff-Parkinson-White pattern (short PR interval and a wide and abnormal QRS complex with a delta wave), dextrocardia (reverse R-wave progression across the precordium with a right axis deviation and negative P waves in leads I and aVL), lead misplacement (V1, V2, V3), recording of right-sided leads (reverse R-wave progression in leads V1-V6), Duchenne muscular dystrophy (a posterolateral infarction pattern), or hypertrophic cardiomyopathy (prominent septal Q waves). On occasion it may be a normal variant or due to counterclockwise rotation (*ie*, early transition).

Pericarditis / Myocarditis

Pericarditis, which is often associated with myocardial inflammation or myocarditis of the epicardium, causes diffuse inflammation and diffuse ECG changes reflecting involvement of all or most of the heart. The characteristic ECG findings with pericarditis include:

- Diffuse ST-segment elevation is seen in all or almost all leads. ST segments have normal concave morphology regardless of the height of ST-segment elevation. There is no change in the ST-segment morphology over time (*ie*, there are no evolutionary changes, as are seen with an acute MI).
- There is no reciprocal ST-segment depression.
- T waves are normal (*ie*, asymmetric).
- PR depression may be seen. However, its absence does not exclude pericarditis.
- T-wave inversion may occur after ST segments return to isoelectric baseline. ■

Core ECGs

A 29-year-old pregnant woman is admitted to the hospital in early labor. She reports fleeting palpitations during the weeks prior to presentation. She is resting comfortably between contractions.

What does her ECG show?

What is the likely diagnosis?

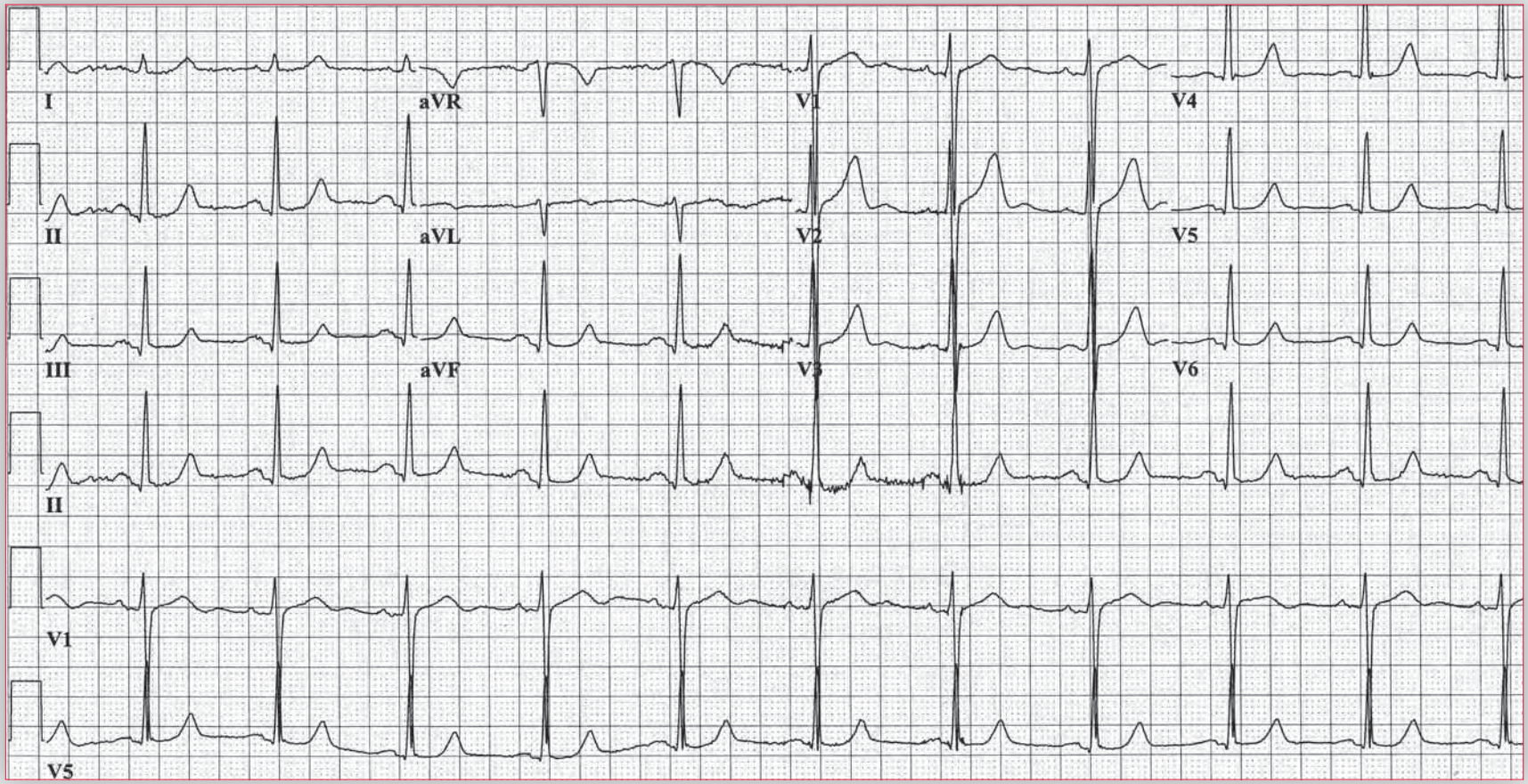

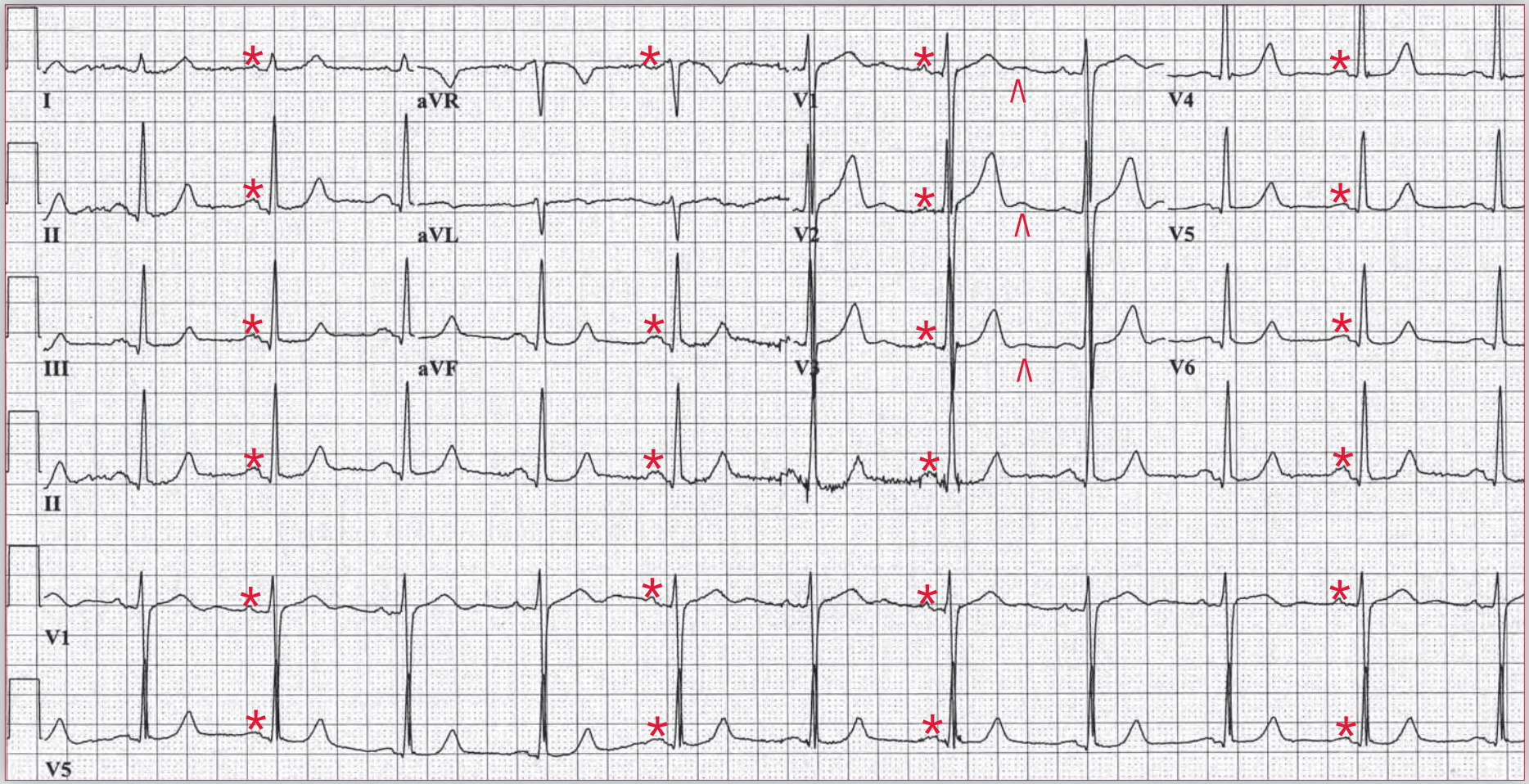

ECG 1 Analysis: Normal sinus rhythm, normal ECG

There is a regular rhythm at a rate of 66 bpm. There is a P wave (*) before each QRS complex, with a stable PR interval (0.16 sec). The P waves are positive in leads I, II, aVF, and V4-V6 and negative in lead aVR. They have a normal morphology. This is a normal sinus rhythm.

The QRS complex duration is normal (0.08 sec), and the axis is normal, between 0° and +90° (positive QRS complex in leads I and aVF). The QT/QTc intervals are normal (400/420 msec). The QRS complex morphology is normal, and there is normal R-wave progression across the precordium. The ST segments are normal in morphology (concave) and are at baseline (the TP segment). The T waves have a normal morphology (*ie*, they are asymmetric and the upstroke is slower than the downstroke). A U wave (^) can be seen after the T wave in leads V1-V3. The U wave is believed to represent delayed repolarization of the His-Purkinje system and hence is usually more prominent in the right precordial leads. This is a normal ECG.

It should be noted that very prominent U waves seen across the precordium can be a sign of hypokalemia. In the context of her palpitations, it would be reasonable to check this woman's electrolytes because hypokalemia causes increased myocardial excitability and could precipitate arrhythmia. ■

Notes

A 55-year-old man presents for an insurance physical examination before starting a new job. He feels well and has no complaints. On exam, his blood pressure is 165/90 mm Hg in both arms. His cardiac exam is notable for an S4 and a sustained but nondisplaced apical impulse.

What does his ECG show?

What is the likely diagnosis?

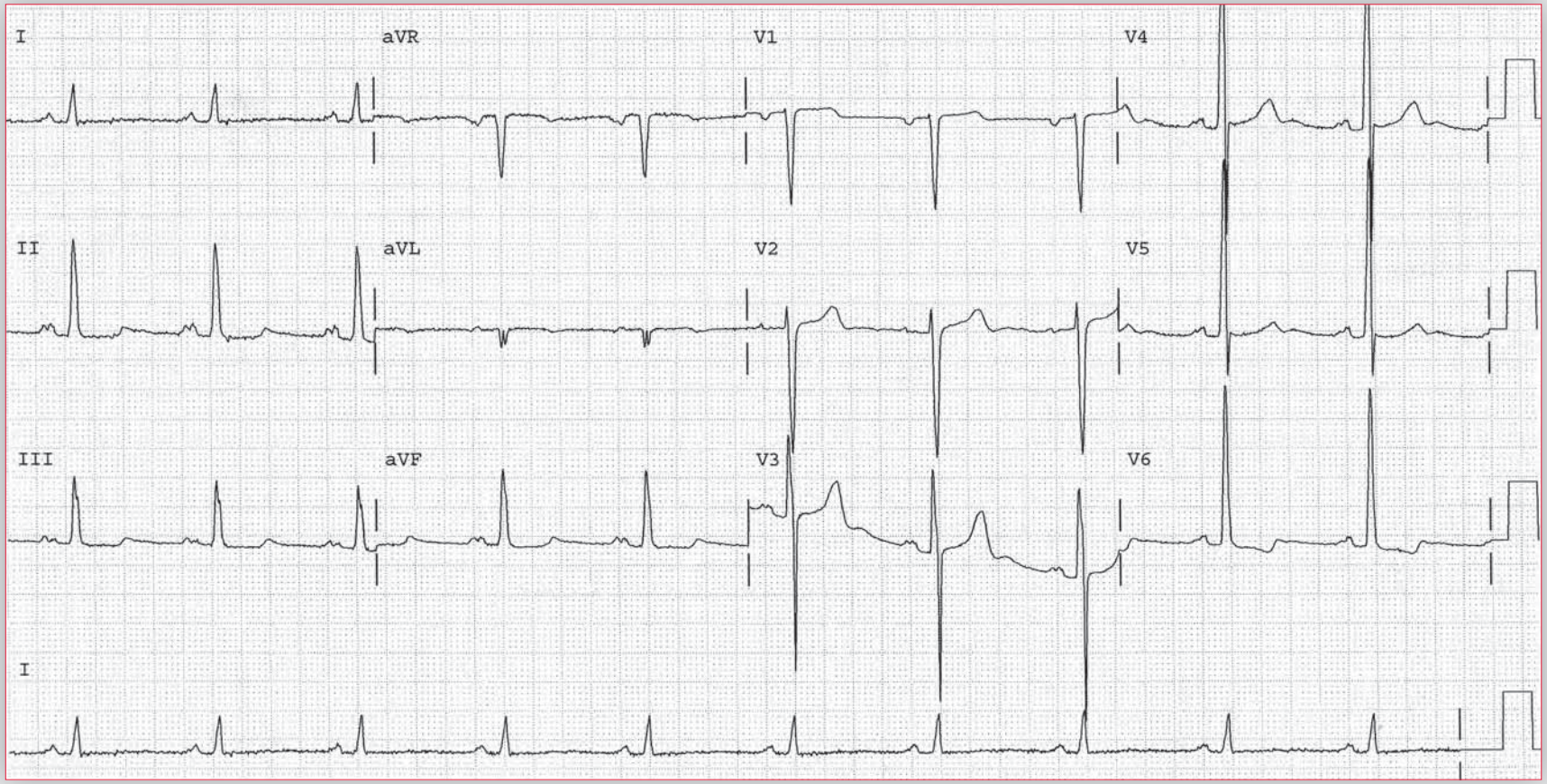

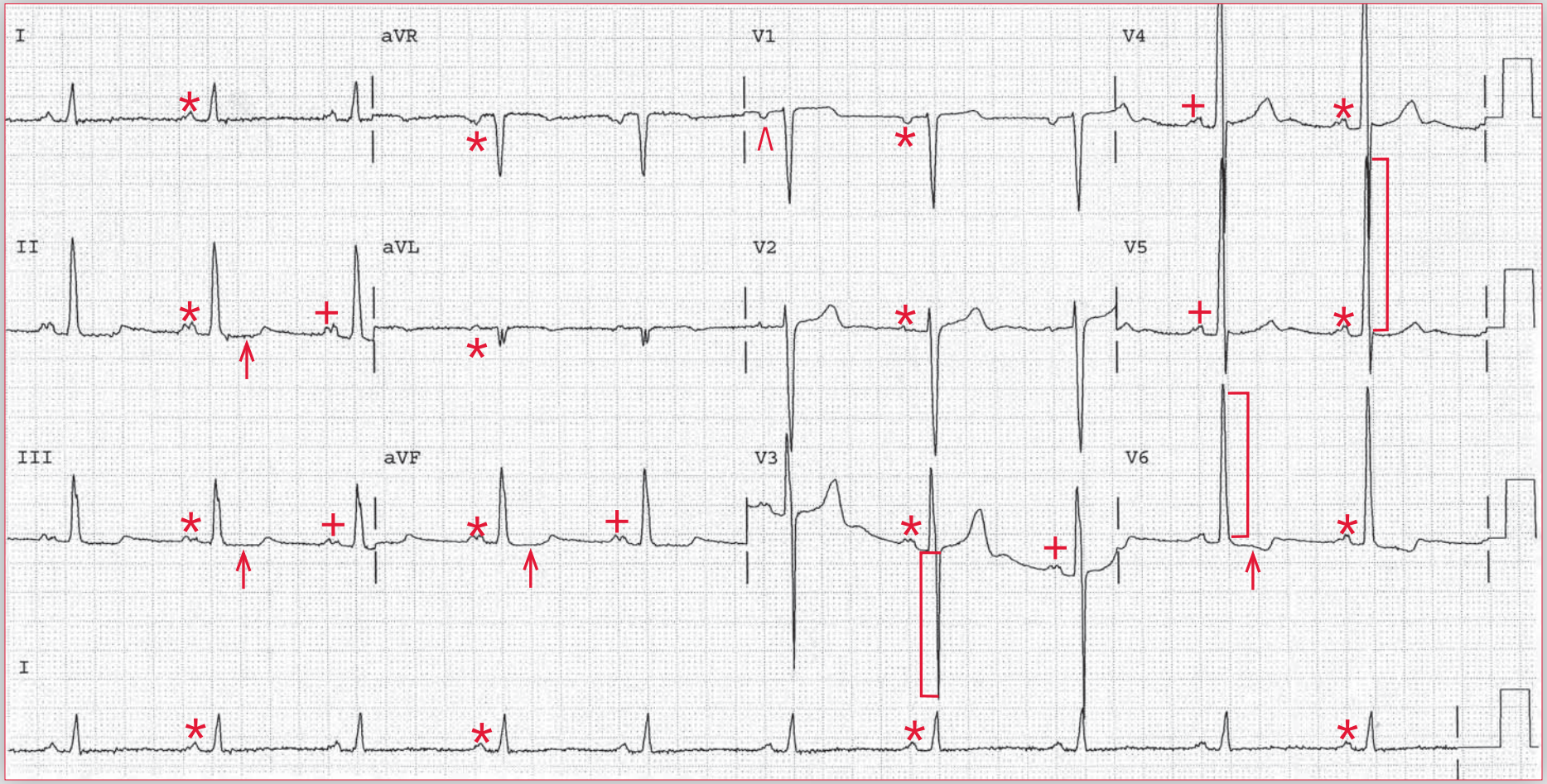

ECG 2 Analysis: **Normal sinus rhythm, left atrial hypertrophy (abnormality), left ventricular hypertrophy (LVH)**

There is a regular rhythm at a rate of 60 bpm. There is a P wave (*) before each QRS complex, and the PR interval is constant (0.20 sec). The P wave is upright in leads I, II, aVF, and V4-V6 and negative in lead aVR. This is a normal sinus rhythm.

However, the P wave is very broad (0.16 sec), with an increased amplitude (0.3 mV) and prominent notching (+), seen best in leads II, III, aVF, and V3-V5. The second component of the P wave has a greater amplitude than the first component. The P-wave morphology has been termed P mitrale. The P wave is completely negative in lead V1 (^). These patterns are characteristic of left atrial hypertrophy (or left atrial abnormality). Although this is often termed left atrial enlargement, it should be remembered that the waveforms on the ECG represent myocardial muscle depolarization and repolarization and hence reflect muscle mass or intraatrial conduction and not chamber size. Left atrial hypertrophy is the result of systemic hypertension, other causes for restrictive left ventricular cardiomyopathy, aortic stenosis, or mitral valve disease.

The QRS complexes are of normal duration (0.08 sec) and have a normal axis, between 0° and +90° (positive QRS complex in leads I and aVF). However, the QRS amplitude (voltage) is markedly increased, especially in leads V4-V6, with an R wave 30 mm in height ( ]). The S-wave depth (voltage) in lead V3 is almost 25 mm ([ ). The sum of these two QRS voltages (S-wave depth in lead V3 + R-wave amplitude in lead V4 = 55 mm) meets one of the criteria for left ventricular hypertrophy (LVH) (*ie*, S-wave depth in any precordial lead + R-wave amplitude in any precordial lead ≥ 35 mm). Associated with the LVH are ST-segment changes, particularly seen in leads II, III, aVF, and V6 (↑). LVH is also present based on the Romhilt-Estes criteria (QRS amplitude, left atrial hypertrophy, and ST-T wave changes [score = 9]). The QT/QTc intervals are normal (420/420 msec).

It is likely that this patient has longstanding hypertension. The increased arterial afterload resulting from the systemic hypertension causes an increase in systolic pressure that is generated by the left ventricle to overcome this increased resistance. This results in LVH. When LVH develops, there is also left ventricular diastolic dysfunction and the left atrium generates a higher pressure to fill the “stiff or rigid” left ventricle. This results in left atrial hypertrophy.

Treatment of hypertension often results in regression of LVH as well as improvement in diastolic dysfunction and left atrial hypertrophy (abnormality). ■

Notes

A 65-year-old woman presents to her primary care physician with exertional chest discomfort and shortness of breath while climbing the stairs to her second-floor apartment. The discomfort is becoming progressively worse and occurring with less effort. She never experiences the discomfort at rest. On exam her blood pressure is 126/72 mm Hg. She has a grade III/VI systolic crescendo–decrescendo murmur at the upper sternum (*ie*, base of the heart) that radiates to the clavicles, and a second murmur with the same timing is audible at the apex.

What does her ECG show?

What is the likely diagnosis?

What further evaluation should be performed?

What therapy would you recommend?

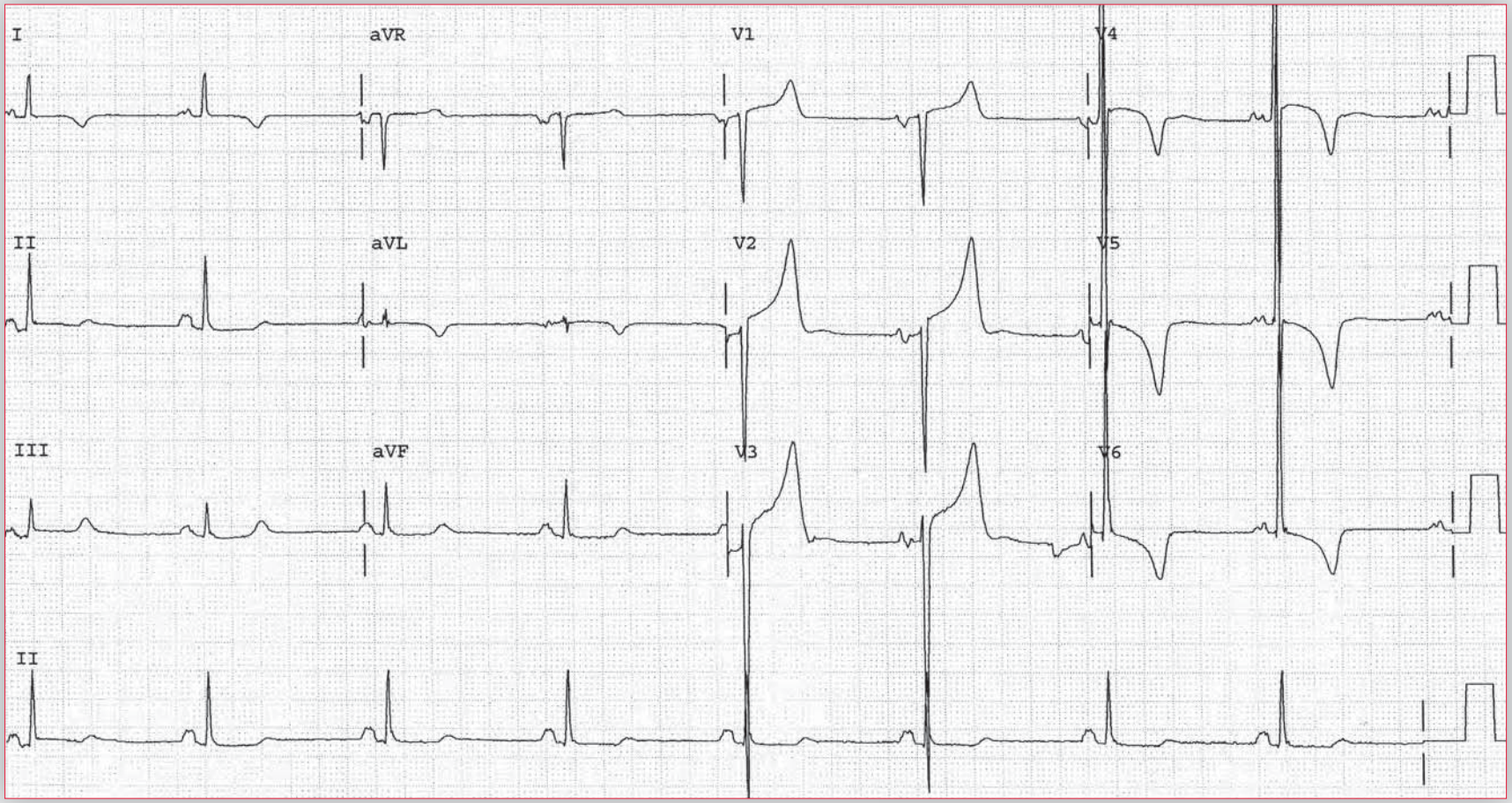

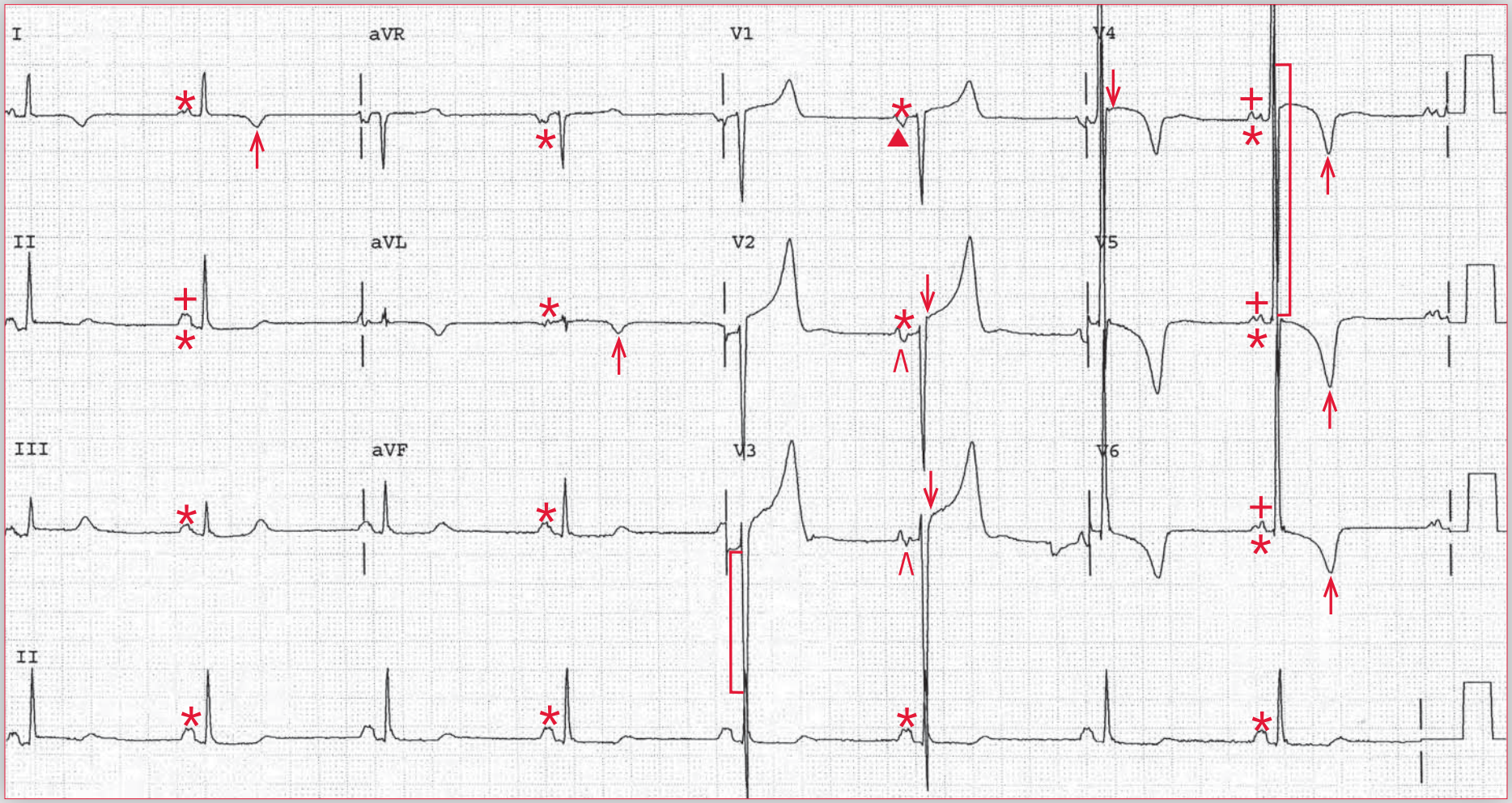

ECG 3 Analysis: **Sinus bradycardia, left atrial hypertrophy, left ventricular hypertrophy (LVH), early repolarization**

There is a regular rhythm at a rate of 48 bpm. There is a P wave (*) before each QRS complex, and the PR interval is stable (0.18 sec). The P wave is upright in leads II, III, aVF, and V4-V6 and negative in lead aVL. This indicates a sinus bradycardia.

The P waves are broad (0.14 sec) and have an increased amplitude (0.35 mV). There is significant notching of the P wave (+), especially prominent in leads II and V4-V6. The second component of the P wave has a greater amplitude than the first. In addition, the P wave in lead V1 (▲) is predominantly negative and there is a significant negative component seen in leads V2-V3 (^). This is characteristic of left atrial hypertrophy (abnormality). The prominently notched P waves are termed P mitrale.

The QRS complex has a normal duration (0.08 sec) and a normal axis, between 0° and +90° (positive QRS complex in leads I and aVF). The QT/QTc intervals are normal (480/430 msec). The amplitude (voltage) of the QRS complex is markedly increased, especially in leads V4-V5 (48 mm) ( ]), and the S-wave depth (voltage) in lead V3 is very increased (27 mm) ([ ); hence the S-wave depth in lead V3 and the R-wave amplitude in lead V5 is 75 mm, which meets one of the voltage criteria for left ventricular hypertrophy (LVH) (*ie*, S-wave depth + R-wave amplitude in any two precordial leads ≥ 35 mm). Also noted is ST-segment elevation in leads V2-V4, which is often seen with LVH and is termed early repolarization (↓). In addition, there are significant ST-T wave abnormalities (↑) seen primarily in leads I, aVL, and V4-V6. The Romhilt-Estes criteria for LVH are also met (QRS voltage, ST-T wave abnormalities, and left atrial hypertrophy; score = 9).

This patient has a murmur that suggests significant aortic stenosis (*ie*, crescendo–decrescendo systolic) at the base (upper sternum) that radiates to the clavicles. The murmur often radiates to the apex, known as the Gallavardin effect. This abnormality was confirmed on echocardiography, which showed severe calcific aortic stenosis (aortic valve area 0.9 cm^2) and mild aortic regurgitation. Mild to moderate aortic regurgitation is often associated with aortic stenosis as a result of inadequate closure of the stenotic leaflets as well as post-stenotic dilation of the aortic root, which results in the high-pressure jet of blood. The presence of concentric LVH was confirmed on echocardiography (left ventricular wall thickness = 14 mm).

continues

As a result of the stenotic aortic valve, there is increased resistance to blood flow as the left ventricle contracts. Hence more pressure is generated by the left ventricle to force blood past the stenotic valve. In order to generate greater pressure and maintain normal wall stress, the left ventricular muscle becomes hypertrophic. As the severity of aortic stenosis increases, the degree of LVH increases. The degree of hypertrophy may increase to a point that the blood and oxygen supply to the myocardium is inadequate, resulting in chronic subendocardial ischemia, which manifests as ST-T wave changes. This may be associated with anginal symptoms. Thus, angina may be seen with LVH and subendocardial ischemia even in the absence of epicardial coronary artery disease and represents a reduction in myocardial reserve from a relative reduction in blood and oxygen supply to the hypertrophied myocardium.

As a result of severe aortic stenosis associated with symptoms, this patient underwent cardiac catheterization, which is usually performed in those with known severe aortic stenosis to evaluate the coronary arteries. The valve area was 0.7 cm^2, confirming the results of the echocardiogram, and there was no coronary artery disease. She underwent aortic valve replacement, which is the only definitive therapy for aortic stenosis. There is often regression of LVH and diastolic dysfunction after aortic valve replacement. ■

A 78-year-old black man is referred to a cardiologist for progressive dyspnea on exertion, orthostatic hypotension, and fatigue. On physical examination, his blood pressure is 88/52 mm Hg, heart sounds are regular, and there is a soft S3 but no murmurs. Chest auscultation reveals reduced breath sounds. There is significant neck vein distension and 3+ peripheral edema to the mid-calf.

What does his ECG show?

What is the likely diagnosis?

Is any further evaluation necessary?

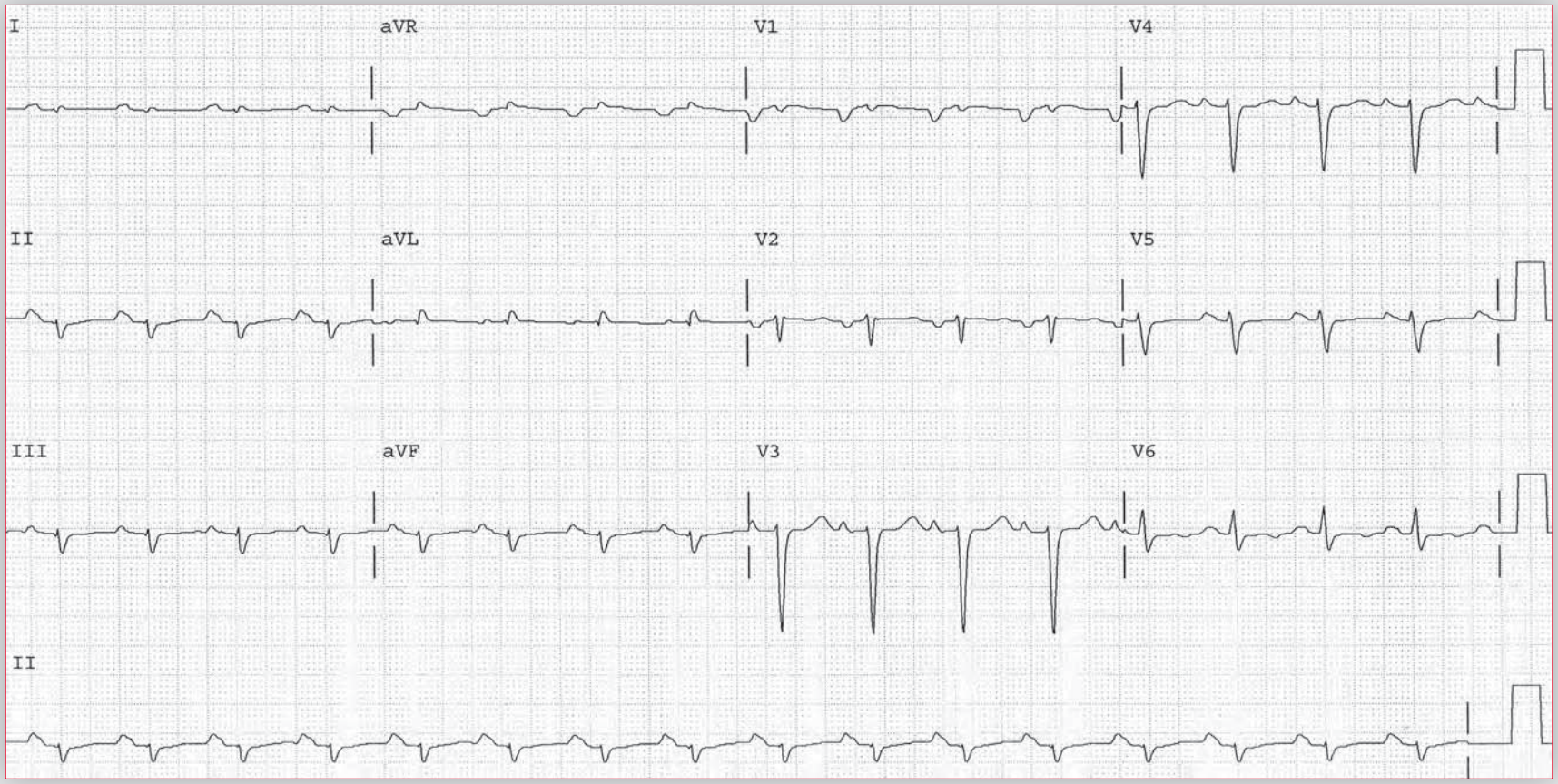

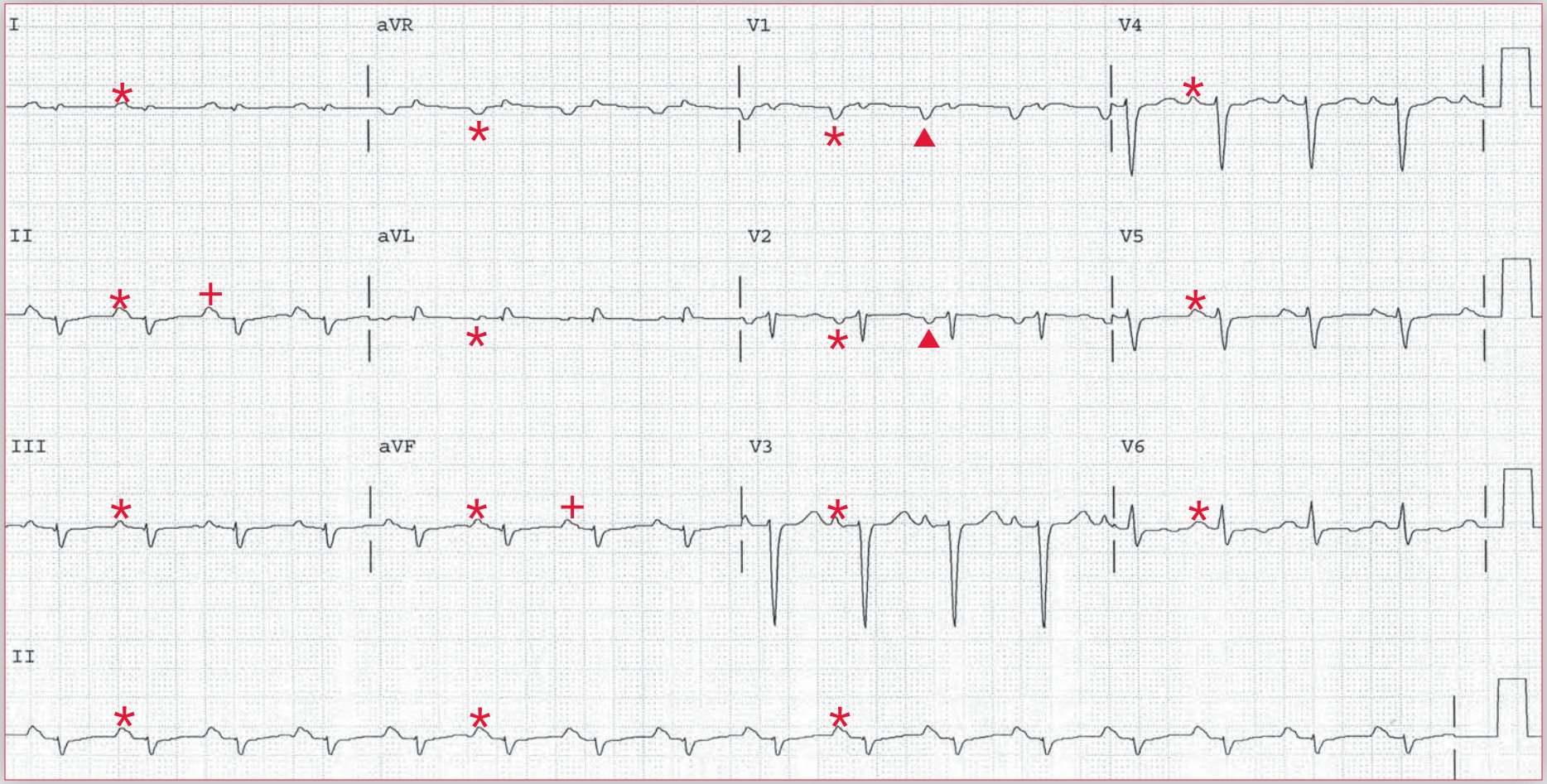

ECG 4 Analysis: Normal sinus rhythm, first-degree AV block, left atrial hypertrophy (abnormality), left anterior fascicular block, low voltage in limb leads, clockwise rotation (late transition)

There is a regular rhythm at a rate of 98 bpm. There is a P wave (*) before each QRS complex, with a stable PR interval (0.22 sec). The P wave is upright in leads I, II, aVF, and V4-V6 and negative in lead aVR. This is a normal sinus rhythm with a first-degree AV block. The P wave is broad (0.16 sec) with some notching seen in leads II and aVF (+). The P wave is significantly negative in leads V1-V2 (▲). These features are characteristic of left atrial hypertrophy or a left atrial abnormality.

The QRS complexes have a normal duration (0.10 sec). However, low amplitude is present in the limb leads (defined as a QRS complex amplitude [voltage] ≤ 5 mm in each limb lead). The axis is extremely leftward in the frontal axis, between –30° and –90° (positive QRS complex in lead I and negative QRS complex in leads II and aVF with an rS morphology). As there is no evidence of an inferior wall myocardial infarction (Q waves in leads II, III, and aVF), which can result in an extreme left axis deviation, the left axis deviation in this case is the result of a left anterior fascicular block. The QT/QTc intervals are prolonged (360/460 msec) but are actually normal when corrected for the slightly widened QRS complex duration (340/430 msec). There is poor R-wave progression in leads V1-V5 with late transition (*ie*, R/S > 1 in lead V6). This is termed clockwise rotation, which reflects the horizontal axis of the heart. This is determined by imagining the heart as viewed from under the diaphragm. With clockwise rotation the left ventricular electrical forces are shifted backward and hence develop late in the lateral precordial leads, accounting for the poor R-wave progression and late transition. With counterclockwise rotation, the electrical forces from the left ventricle are shifted forward and hence they develop earlier in the precordial leads (*ie*, a tall R wave in lead V2).

The presence of low voltage in the limb leads and significant left atrial hypertrophy in a patient who presents with signs of a low cardiac output and evidence of right-sided volume overload should prompt an evaluation for constriction or a restrictive cardiomyopathy, which may be due to an infiltrative disease. In this age group and in a black man, amyloid cardiomyopathy is of particular concern. ■

Notes

A 38-year-old woman with a history of Raynaud's disease presents to her primary care physician with progressive decline in exercise tolerance. Over the past 6 months, she has gone from being able to participate in aerobics twice per week to having dyspnea with walking a single flight of stairs. Her examination is notable for a loud P2, subtle right precordial heave, and trace pedal edema.

What does her ECG show?

What is the likely diagnosis?

What further evaluation would be useful?

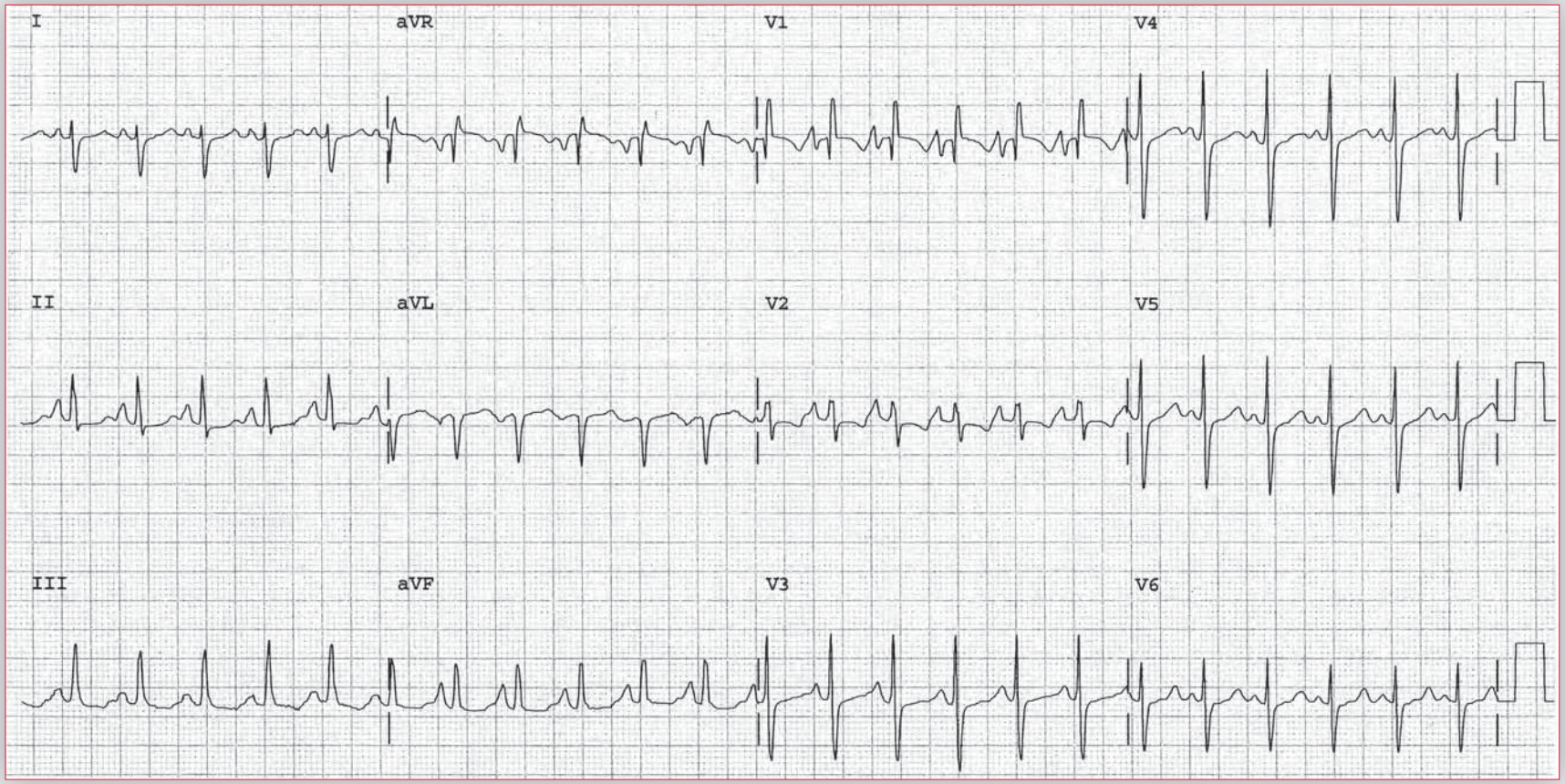

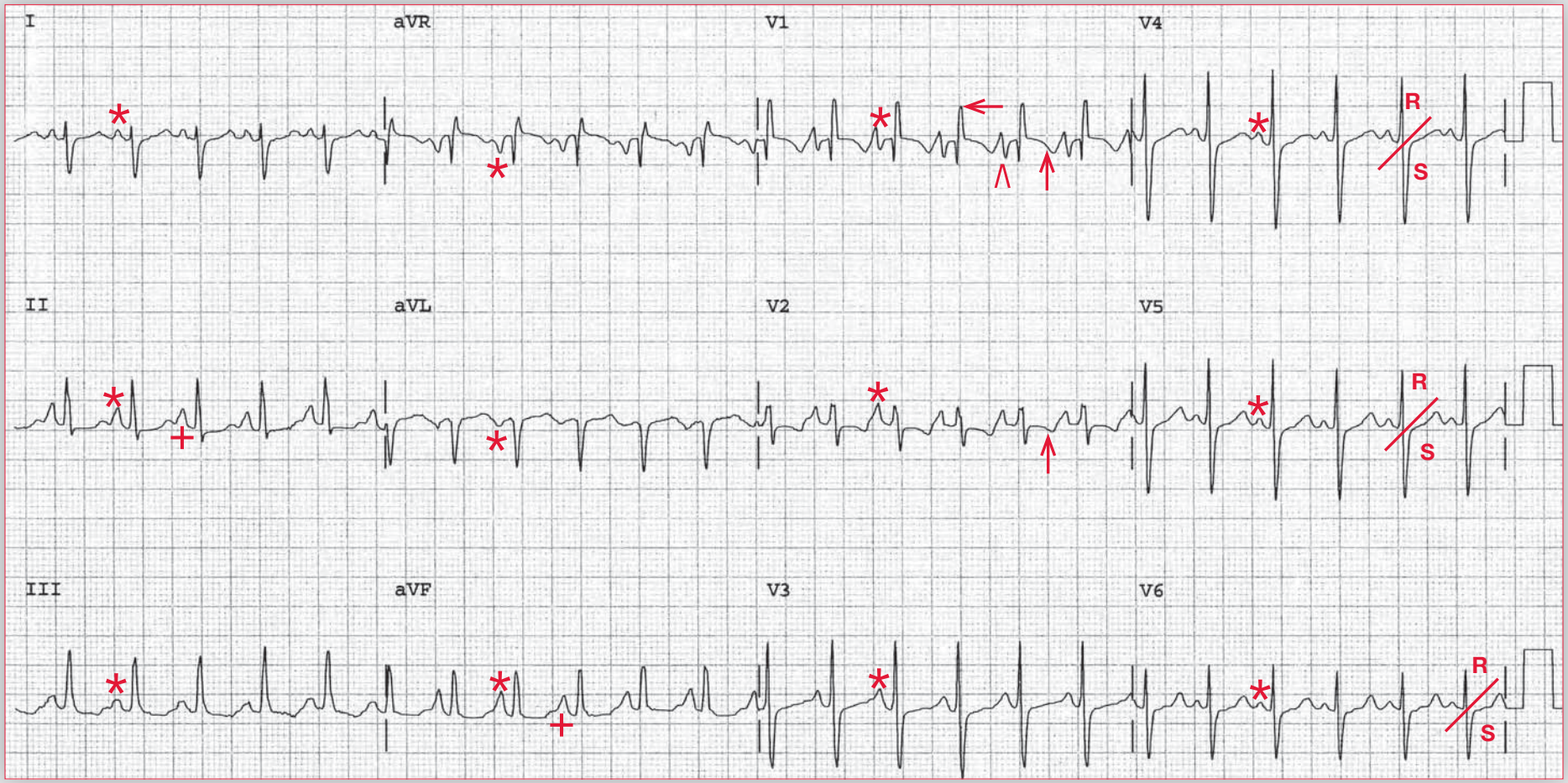

ECG 5 Analysis: Sinus tachycardia, right atrial hypertrophy (abnormality), right axis deviation, right ventricular hypertrophy (RVH)

There is a regular rhythm at a rate of 140 bpm. There is a P wave (*) before each QRS complex, with a stable PR interval (0.14 sec). The P wave is upright in leads I, II, aVF, and V4-V6 and negative in lead aVR. This is a sinus tachycardia. The P waves are tall (0.4 mV), peaked, and narrow (0.10 sec), particularly obvious in leads II and aVF (+). The P wave is also primarily positive and tall and peaked in lead V1 (^). This is characteristic of right atrial hypertrophy (or abnormality) and has been termed P pulmonale.

The QRS complex duration is normal (0.08 sec), and the axis is rightward, between +90° and +180° (QRS complex is negative in lead I and positive in lead aVF). There are a number of causes for a right axis deviation that should be considered. These include right ventricular hypertrophy (RVH; associated with a tall R wave in lead V1 and right atrial hypertrophy or abnormality), a lateral wall myocardial infarction (a deep Q wave in leads I and aVL), right–left arm lead switch (associated with negative P waves and T waves in leads I and aVL), dextrocardia (which resembles right–left arm lead switch and also has reverse R-wave progression across the precordium), Wolff-Parkinson-White pattern (with a prolonged QRS complex duration due to a delta wave and a short PR interval), and a left posterior fascicular block (a diagnosis of exclusion when there are no other causes for the right axis deviation).

There is a tall R wave (7 mm) and no S wave in lead V1 (←) and an S/R > 1 in leads V5-V6. This is characteristic of RVH, which is the cause for the right axis deviation. Associated with RVH are ST-T wave changes seen primarily in leads V1-V2 (↑), which reflect subendocardial ischemia of the thick right ventricular myocardium. The QT/QTc intervals are normal (280/430 msec).

continues

The patient's physical exam and ECG findings are consistent with RVH and right atrial hypertrophy, likely resulting from severe pulmonary hypertension (PH). Progressive exercise intolerance and dyspnea on exertion are typical of PH. In this case, the condition may be idiopathic (primary) or related to an unrecognized collagen vascular disease such as systemic lupus erythematosus (which may also explain the Raynaud's phenomenon), although the differential diagnosis is broad. Other potential causes of PH include left ventricular dysfunction (causing pulmonary venous hypertension); mitral stenosis; diseases associated with chronic hypoxia (which cause PH by hypoxic vasoconstriction), such as interstitial lung disease, sleep apnea, or chronic obstructive pulmonary disease; chronic thromboembolic disease; or mechanical obstruction of the pulmonary vasculature (by infiltrative or scarring lung diseases). Based on the physician's relative suspicion for each of these underlying causes, testing includes a chest X-ray, echocardiogram, pulmonary function tests, overnight sleep oximetry, ventilation/perfusion (V/Q) scan, or computed tomography (CT) pulmonary angiogram.

Right heart catheterization is necessary for the diagnosis of PH. A mean pulmonary arterial pressure higher than 25 mm Hg is diagnostic, although pressures may be much higher in this symptomatic patient. At the time of right heart catheterization, a pulmonary capillary wedge pressure (PCWP) can be measured to exclude left-sided heart failure as a cause (*ie*, a normal PCWP). Furthermore, inhaled nitric oxide (or other vasodilator such as epoprostenol) may be administered at the time of catheterization to assess potential responsiveness to vasodilating agents. ■

A 54-year-old black man presents for evaluation of multiple episodes of syncope and palpitations. A 24-hour Holter monitor shows evidence of both supraventricular tachycardia and brief, nonsustained ventricular tachycardia. A chest X-ray shows a normal cardiac silhouette with prominent hilar lymphadenopathy.

What does his ECG show?

What is the likely diagnosis?

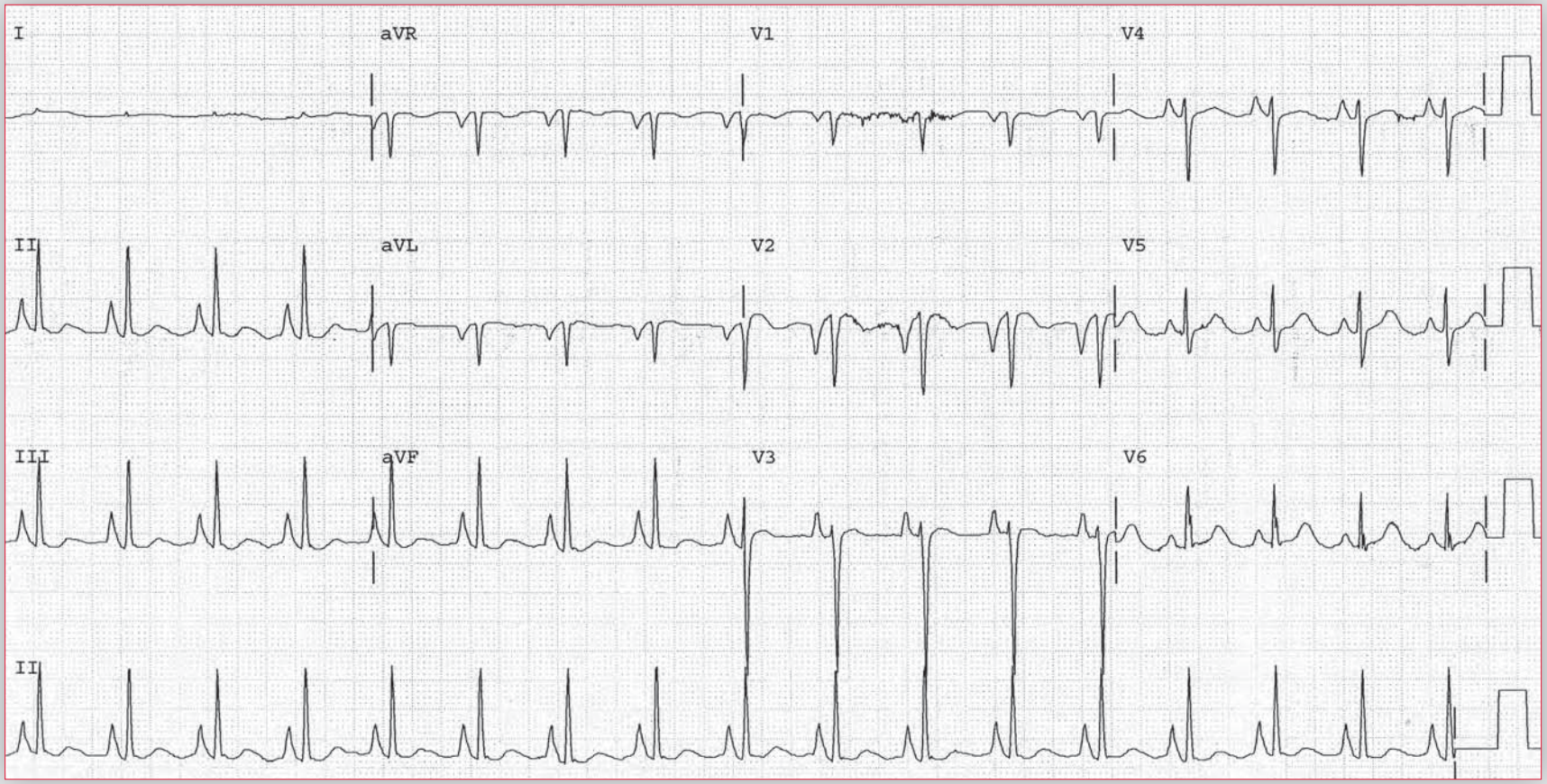

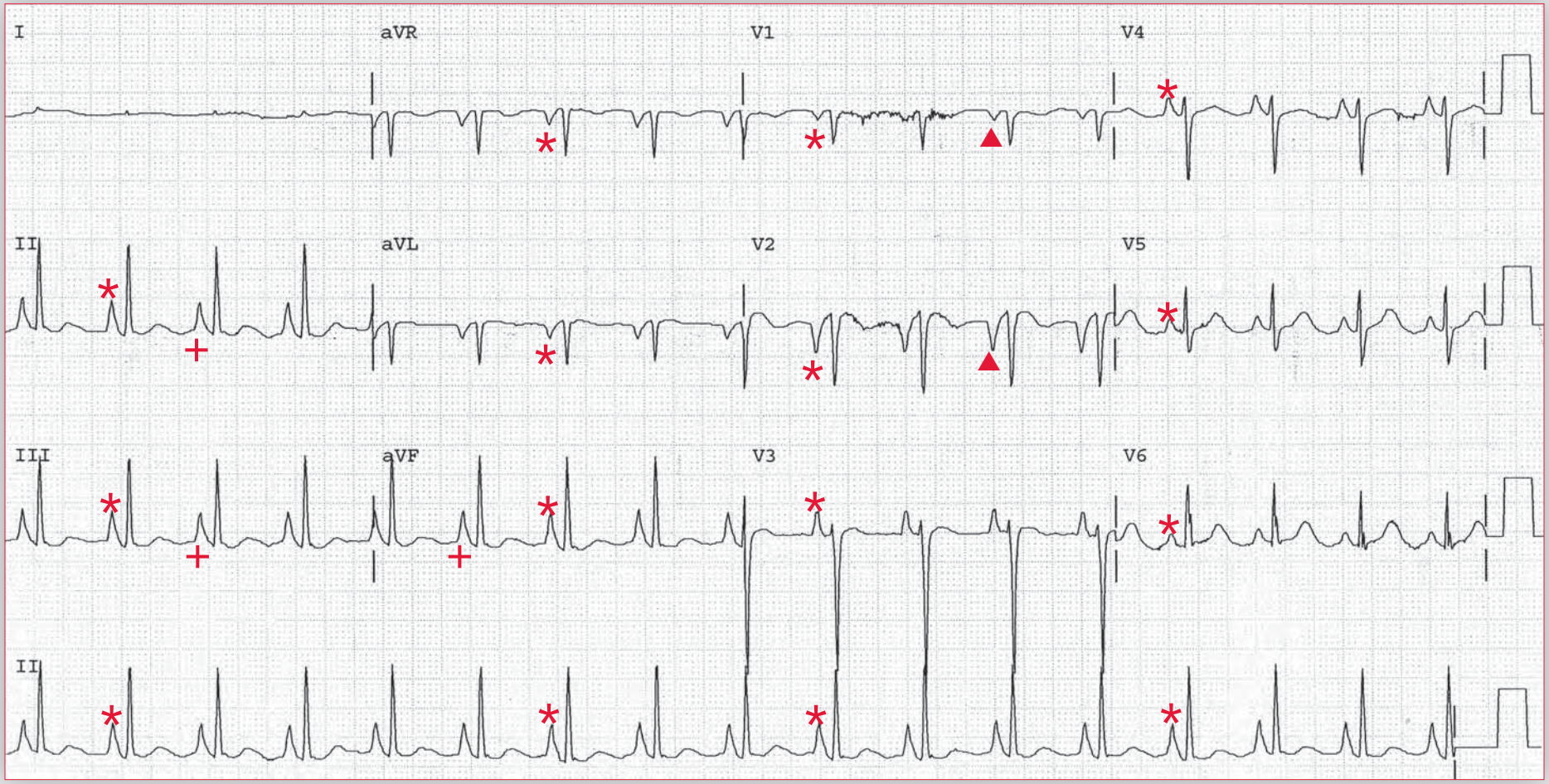

ECG 6 Analysis: Sinus tachycardia, right atrial hypertrophy (abnormality), left atrial hypertrophy (abnormality), biatrial hypertrophy (abnormality)

The rhythm is regular at a rate of 100 bpm. There is a P wave in front of each QRS complex (*), and the PR interval is stable (0.14 sec). The P wave is positive in leads I, II, aVF, and V4-V6 and negative in lead aVR. This is a sinus tachycardia. The P waves are narrow (0.10 sec), tall (0.5 mV), and peaked in leads II, III, and aVF (+). This is characteristic of right atrial hypertrophy (abnormality) or P pulmonale. In addition, the P wave is very negative in leads V1-V2 (▲), which is characteristic of left atrial hypertrophy (abnormality). Hence biatrial hypertrophy (abnormality) is present.

The QRS complex duration is normal (0.08 sec), and the axis is normal, between 0° and +90° (positive QRS complex in leads I and aVF). The QRS morphology is normal, and the QT/QTc intervals are normal (320/410 msec).

Hilar lymphadenopathy and ventricular tachycardia in this patient are possibly due to sarcoid granulomas involving the lungs and myocardium. After pulmonary disease, cardiac involvement is the second most common presentation of sarcoidosis and ventricular tachycardia is a common cause of death. Ventricular tachycardia can arise either from increased automaticity of the affected myocardium or reentry within the sarcoid granuloma. Because the clinical symptoms of cardiac sarcoid are nonspecific, the diagnosis is often difficult to make. A tissue diagnosis can only be made by endomyocardial biopsy, but involvement is often patchy, making the yield of biopsy small.

Treatment of cardiac sarcoidosis, if present, is challenging. The response to systemic glucocorticoids is variable. Endocardial radiofrequency ablation of sarcoid granulomas can reduce the burden of ventricular tachycardia, although the disease often progresses to other regions of myocardium and the efficacy of ablation tends to be short lived. Patients with complete (third-degree) heart block may require permanent placement of a pacemaker. Patients deemed to be at high risk for a serious life-threatening ventricular tachyarrhythmia often receive an implantable cardioverter–debrillator, which can be useful for the prevention of sudden death. ■

Notes

A 36-year-old man presents to the emergency department with complaints of chest pain after cocaine use. Upon arrival, his pain has resolved and he is hemodynamically stable. On examination, his blood pressure is 180/96 mm Hg, his heartbeat is regular, and there is an audible S4.

What does his ECG show?

What is the likely diagnosis?

Is any additional evaluation or therapy necessary?

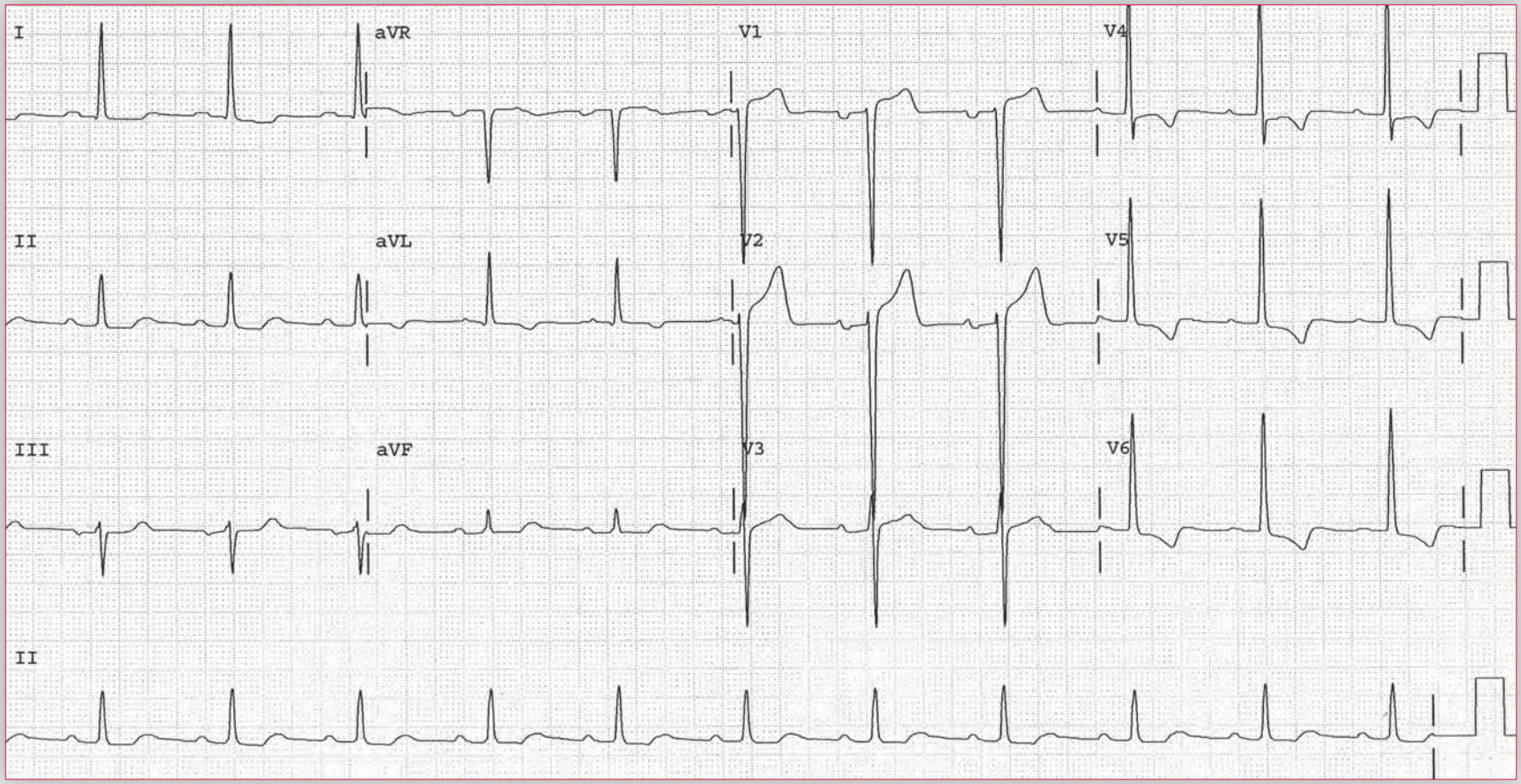

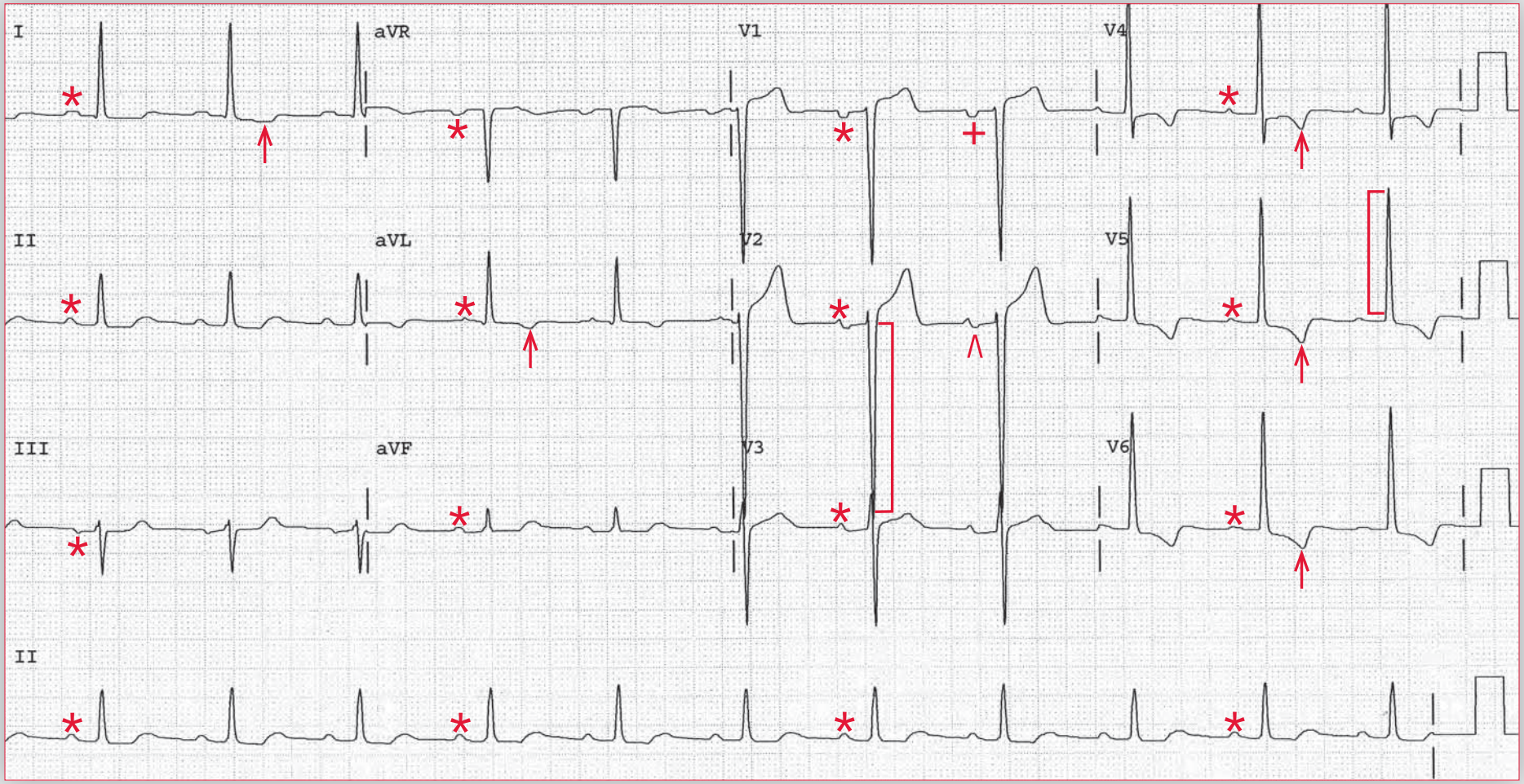

ECG 7 Analysis: Normal sinus rhythm, first-degree AV block, left atrial hypertrophy (abnormality), left ventricular hypertrophy (LVH) with ST-T wave abnormalities

There is a regular rhythm at a rate of 68 bpm. There is a P wave (*) in front of each QRS complex, with a stable PR interval (0.24 sec). The P wave is positive in leads I, II, aVF, and V4-V6 and negative in lead aVR. This is a normal sinus rhythm with a first-degree AV block. The P wave is inverted in lead V1 (+) and biphasic in lead V2 (^); this is suggestive of left atrial hypertrophy (abnormality).

The QRS complex duration is normal (0.08 sec), and there is a normal axis, between 0° and +90° (positive QRS complex in leads I and aVF). The QT/QTc intervals are normal (380/400 msec). The amplitude (voltage) of the QRS complex is increased, with an S-wave depth in lead V2 of 32 mm ( ]) and an R-wave amplitude in lead V5 of 16 mm ([ ). The S-wave depth in lead in V2 + R-wave amplitude in lead V5 = 47 mm, which meets one of the criteria for left ventricular hypertrophy (LVH) (*ie*, S-wave depth in lead V1 or V2 + R-wave amplitude in lead V5 or V6 ≥ 35 mm in patients ≥ 45 years of age or ≥ 45 mm in patients < 45 years of age). Although this voltage may be seen in patients who are younger than 45 years of age, there are also ST-T wave changes noted in leads I, aVL, and V4-V6 (↑), which are associated with LVH and represent repolarization abnormalities resulting from subendocardial ischemia. The presence of a tall QRS amplitude, ST-T wave abnormalities, and left atrial hypertrophy meet the Romhilt-Estes criteria for LVH (score = 9). There is slight J-point and ST-segment elevation in leads V1-V2, which is early repolarization, commonly seen with LVH or a tall QRS complex amplitude.

Since the patient's pain has resolved and he does not have any acute ischemic changes on ECG, an acute coronary syndrome seems unlikely. Nonetheless, cocaine use is known to cause vasospasm, accelerated atherosclerosis, hypertension, aortic dissection, and cardiomyopathy, all of which must be considered by the treating physician.

Most striking on this ECG is the LVH in this young patient. It is likely that he has longstanding hypertension, perhaps caused or exacerbated by his cocaine use. If this patient stops using cocaine, his LVH may resolve. If hypertension and LVH persist despite abstinence from cocaine, the clinician should investigate for other causes of hypertension. ■

Notes

A 59-year-old woman presents to the emergency department with complaints of indigestion. She has longstanding hypertension and is noncompliant with her medical regimen of lisinopril and amlodipine. Blood pressure on presentation is 190/100 mm Hg.

What does her ECG show?

What is the likely diagnosis?

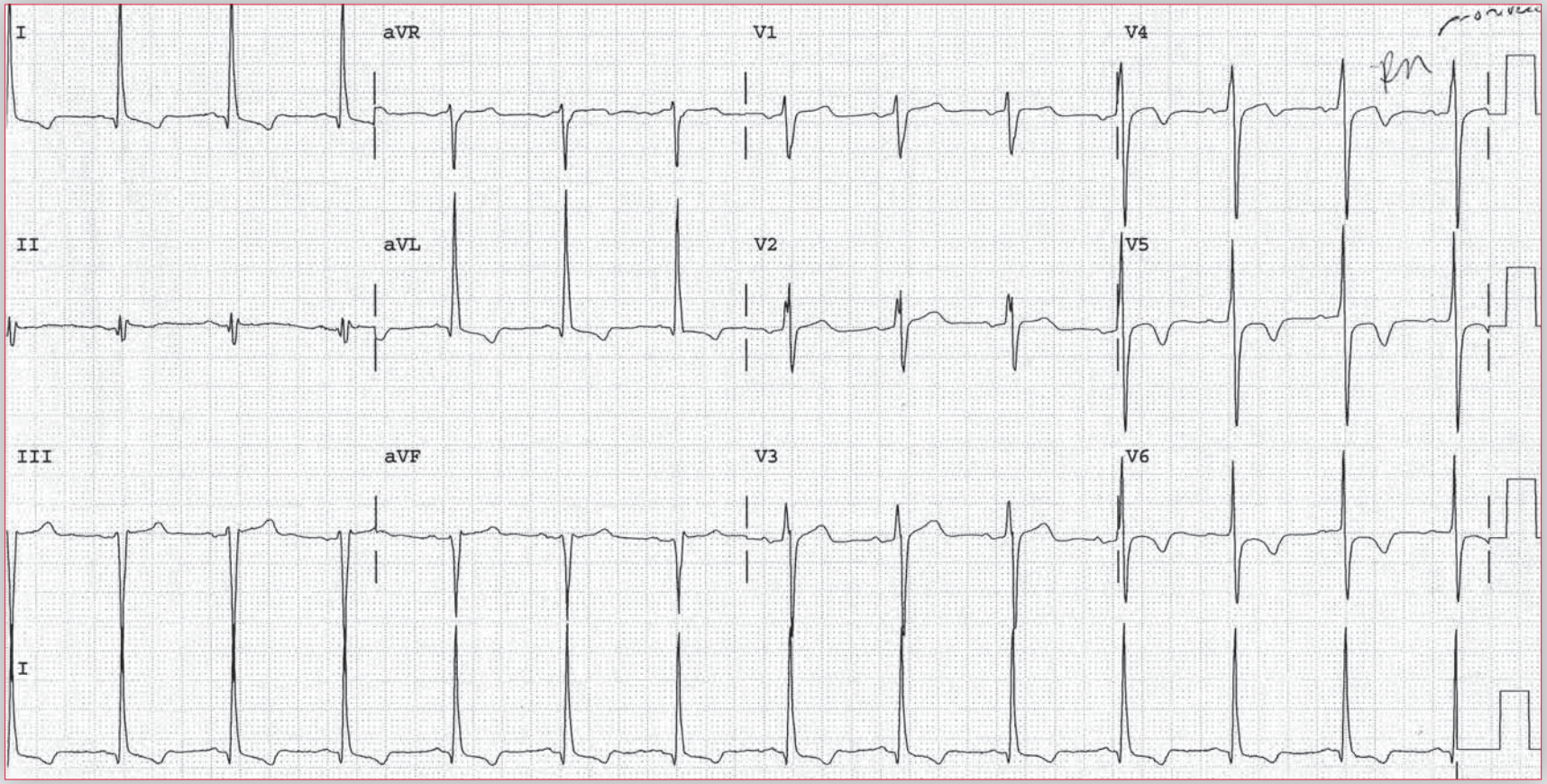

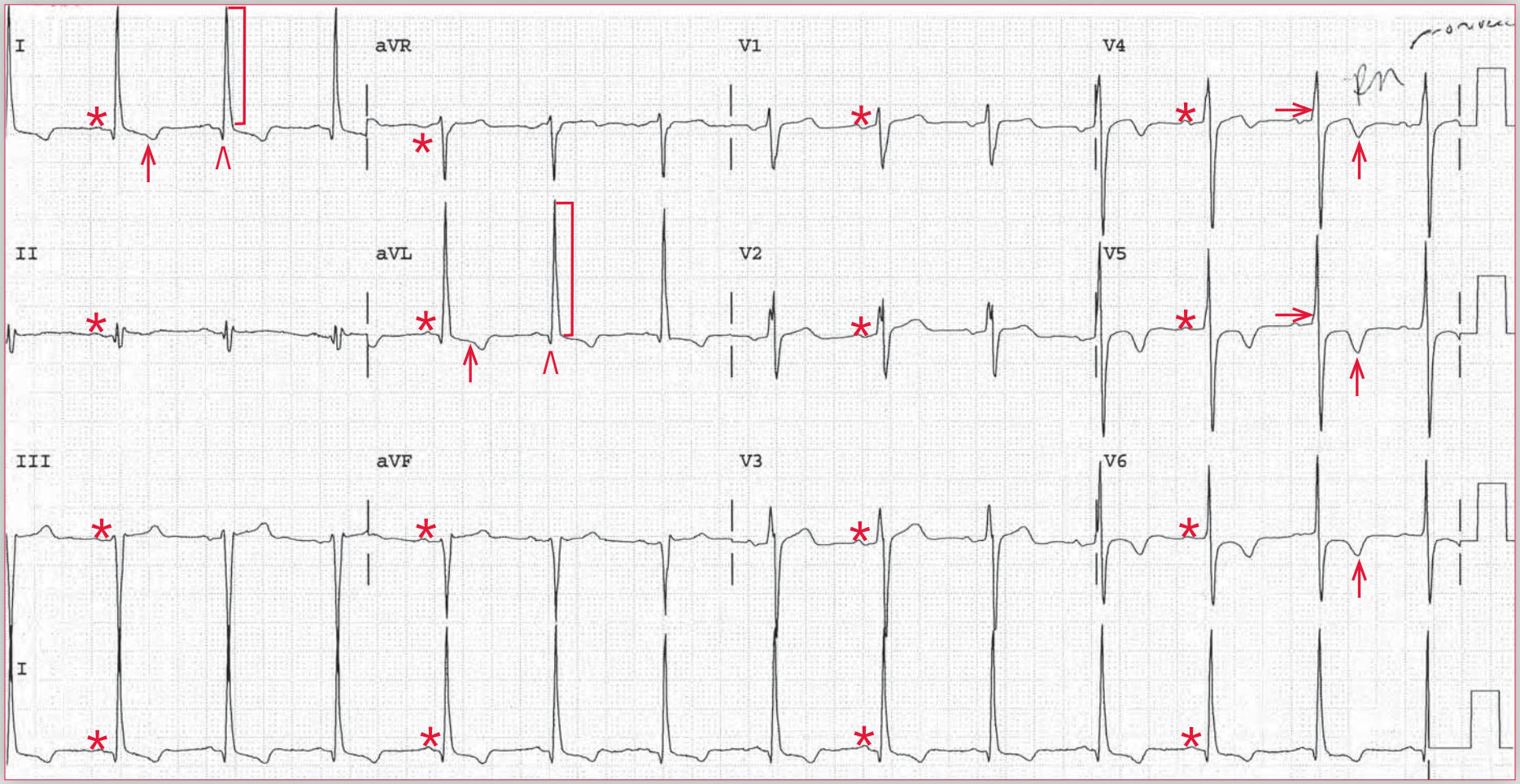

ECG 8 Analysis: **Normal sinus rhythm, left anterior fascicular block, left ventricular hypertrophy**

There is a regular rhythm at a rate of 80 bpm. There is a P wave (*) before each QRS complex, and the PR interval is stable (0.16 sec). The P wave is upright in leads I, II, aVF, and V4-V6. This is a normal sinus rhythm. The P wave has a normal morphology, amplitude, and duration. It is biphasic in lead V1.

The QRS complex duration is normal (0.10 sec), although in leads V4-V5 there is some delay in the upstroke of the R wave (→) (*ie*, a delayed intrinsicoid deflection). The axis is leftward, between –30° and –90° (positive QRS complex in lead I and negative QRS complexes in leads II and aVF). An extreme left axis deviation may be due to an inferior wall myocardial infarction, in which case Q waves would be present in leads II, III, and aVF, accounting for the left axis deviation. In this case, the QRS complexes have an rS morphology, which is characteristic of a left anterior fascicular block. The QT/QTc intervals are normal (360/420 msec). There are small Q waves in leads I and aVL (^); these represent normal septal depolarization. The amplitude of the QRS complexes in leads V1-V6 is normal; however, a markedly increased R-wave amplitude in leads I (22 mm) and aVL (23 mm) ( ]) meets criteria for left ventricular hypertrophy (*ie*, an R-wave amplitude in any limb lead ≥ 20 mm or an R-wave amplitude in lead aVL ≥ 11 mm or ≥ 18 mm when a left axis deviation is present). In addition, there are associated ST-T wave abnormalities (↑), best seen in leads I, aVL, and V4-V6. These are repolarization abnormalities that represent chronic subendocardial ischemia, which occurs as a result of reduced blood supply to the endocardium due to the hypertrophy.

The ECG is diagnostic for left ventricular hypertrophy (tall R wave in leads I and aVL, ST-T wave changes, left axis deviation, and delayed intrinsicoid deflect; Romhilt-Estes score = 9), which is likely attributable to poorly controlled hypertension. The treating clinician in the emergency department must be mindful of potential myocardial ischemia, which can often present as indigestion. Myocardial ischemia could be related to the increased myocardial oxygen demands resulting from the markedly elevated blood pressure. In the emergency department, blood tests for myocardial ischemia (creatine kinase [CK], CK-MB, and troponin) should be drawn, and serial ECGs should be ordered periodically or with any change in symptoms. Markedly elevated blood pressure requires acute therapy, and the clinician should take this as an opportunity to stress compliance with antihypertensive medications given the long-term risk for end-organ dysfunction with uncontrolled hypertension. ■

Notes

A 28-year-old man is referred by his primary care physician to a cardiologist for refractory hypertension. His blood pressure is 190/76 mm Hg bilaterally in his arms but only 128/72 mm Hg in his legs. Cardiac exam reveals a prominent S4 and a sustained apical impulse. A chest X-ray shows prominent rib notching.

What does his ECG show?

What is the likely diagnosis?

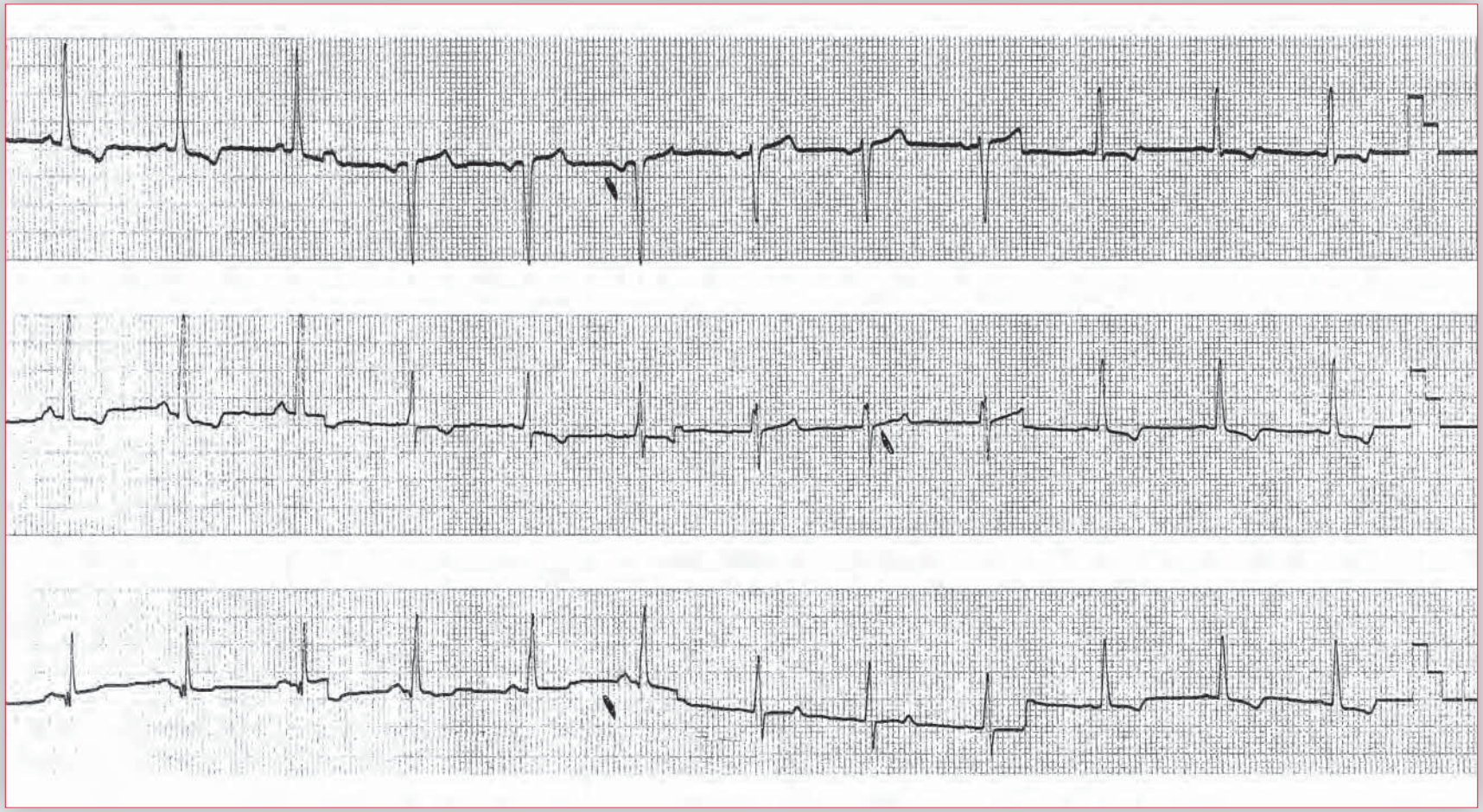

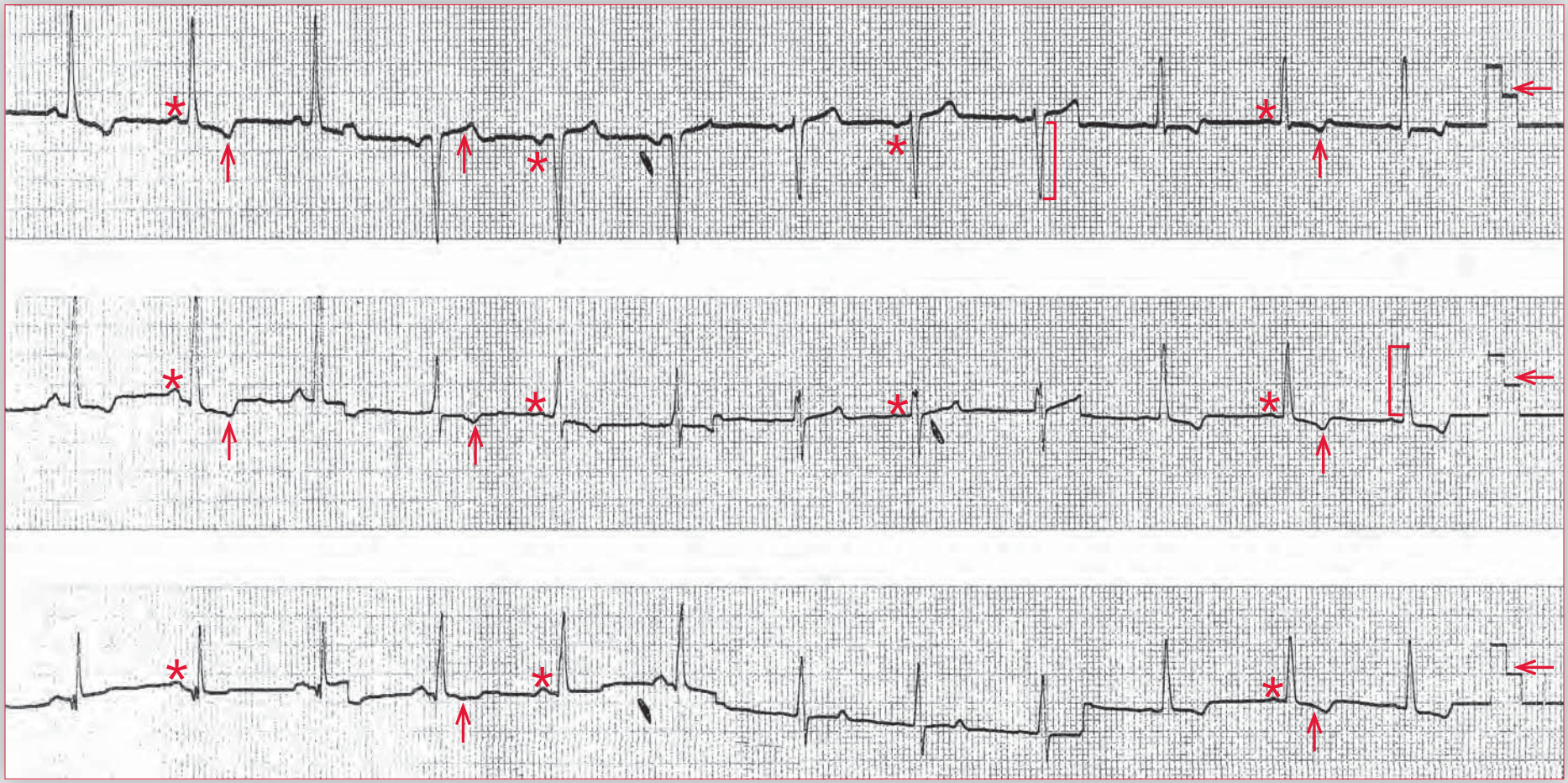

ECG 9 Analysis: Normal sinus rhythm, left ventricular hypertrophy (LVH), recording at half-standard

Although the leads are not labeled, the pattern is always the same (column 1 is leads I, II, and III; column 2 is leads aVR, aVL, and aVF; column 3 is leads V1-V3; and column 4 is leads V4-V6). There is a regular rhythm at a rate of 70 bpm. There is a P wave (*) before each QRS complex, with a stable PR interval (0.16 sec). The P wave is upright in leads I, II, aVF, and V4-V6 and negative in lead aVR. This is a normal sinus rhythm.

The QRS complex duration is 0.08 second, and there is a normal QRS complex morphology. The QRS axis is normal, between 0° and +90° (positive QRS complex in leads I and aVF). The QT/QTc intervals are normal (380/410 msec). As recorded, the QRS voltage is not increased in any lead. However, noted is the standardization used (←) in recording this ECG: The limb leads were recorded at normal standardization (1 mV = 10 mm), while the precordial or chest leads were recorded at half-standard (1 mV = 5 mm). Hence the amplitude of the QRS complexes as recorded in the precordial leads is half of their actual amplitude. The R-wave amplitude in lead V5 is 26 mm ([ ), while the S-wave depth in lead V1 is 26 mm ( ]) (S-wave depth in lead V1 + R-wave amplitude in lead V5 = 52 mm); therefore, this meets one of the criteria for left ventricular hypertrophy (LVH) (*ie*, S-wave depth in lead V1 or V2 + R-wave amplitude in lead V5 or V6 ≥ 35 mm in subjects > 45 years of age and ≥ 45 mm in those < 45 years of age). In addition, ST-T wave changes (↑) are noted in leads I, II, aVR (T wave should be negative), aVL, aVF, and V4-V6; these changes are characteristic of LVH and represent chronic subendocardial ischemia due to reduced perfusion of the endocardial layer of the hypertrophied left ventricular myocardium.

This young man appears to have hypertension on the basis of coarctation of the aorta. A blood pressure differential between the arms and lower extremities is caused by resistance to flow into the descending aorta. The diastolic pressures are often similar, as is observed in this patient. In most cases, the coarctation occurs just distal to the left subclavian artery so the blood pressures are similar in the two arms. Notching of the posterior one-third of the third to eighth ribs is due to erosion by the large collateral arteries. Computed tomography or magnetic resonance angiography can delineate the anatomic characteristics of the coarctation. There is no effective medical therapy for coarctation of the aorta discovered in adulthood. The treatment of choice is either surgical correction or balloon angioplasty with stenting. ■

Notes

A 72-year-old man is brought to the emergency department after suffering an eye injury at work. An intake ECG is abnormal and raises the suspicion for cardiac ischemia among the treating medical team. He denies chest pain. Exam reveals a blood pressure of 162/88 mm Hg, but the patient is otherwise normal. Initial screening creatine kinase (CK)-MB and troponin I are normal.

What does his ECG show?

What is the likely diagnosis?

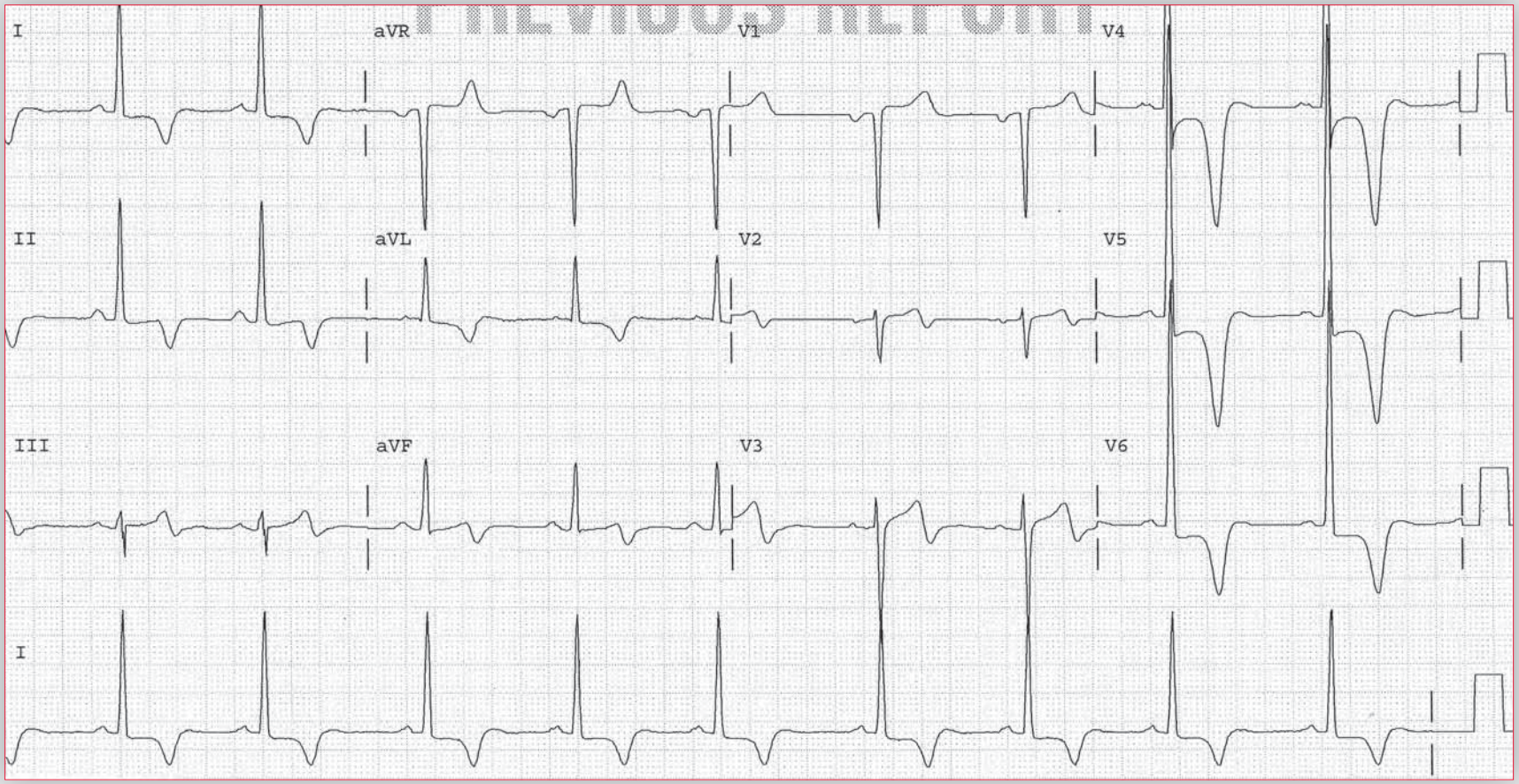

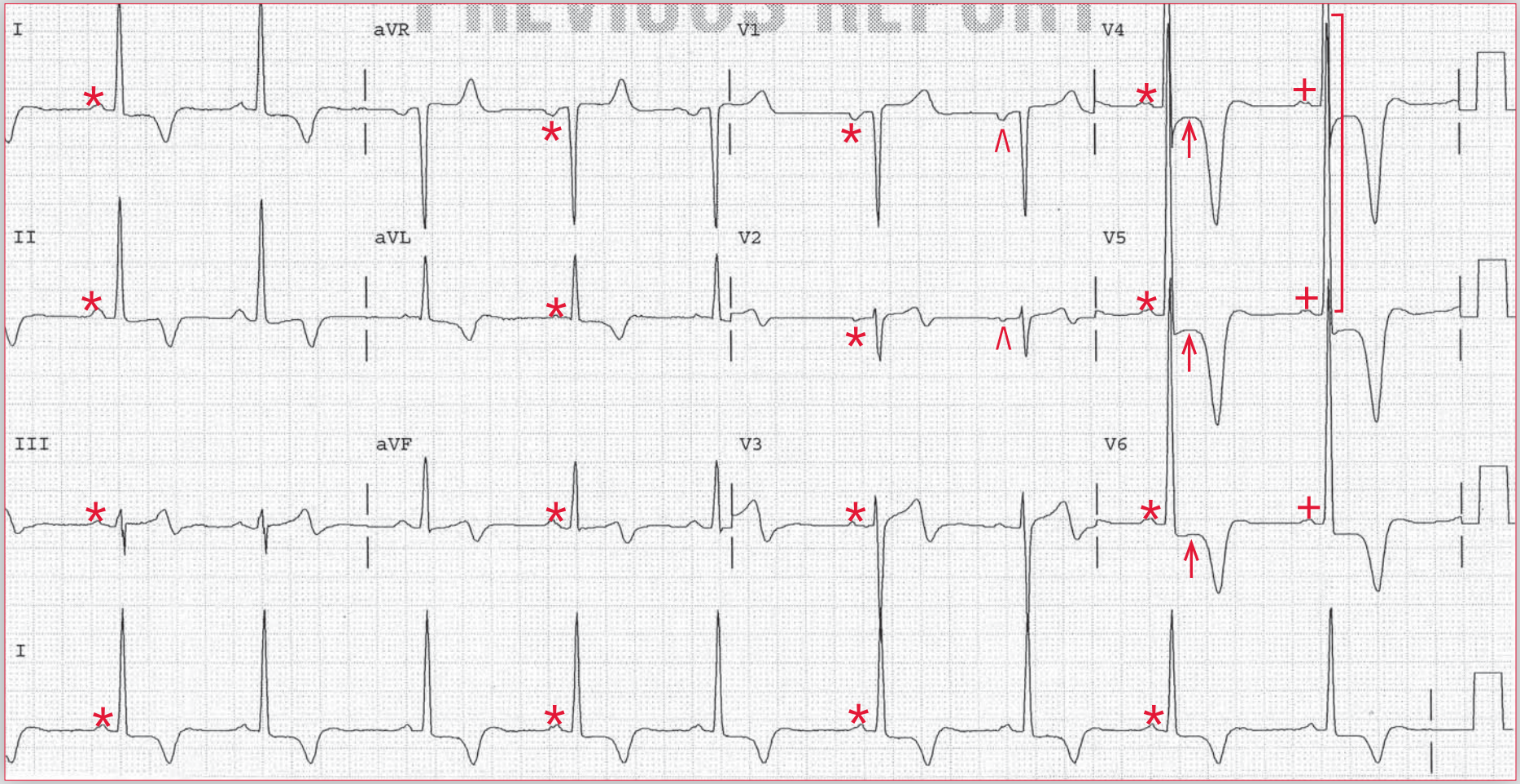

ECG 10 Analysis: Sinus bradycardia, left atrial hypertrophy, left ventricular hypertrophy (LVH) with ST-T wave changes (ST-segment depression and T-wave inversions)

There is a regular rhythm at a rate of 58 bpm. There is a P wave (*) before each QRS complex, and the PR interval is stable (0.18 sec). The P wave is positive in leads I, II, aVF, and V4-V6 and negative in lead aVR. This is a normal sinus rhythm. The P waves are negative in leads V1-V2 (^) and notched in leads V4-V6 (+), diagnostic for left atrial hypertrophy (P mitrale) or a left atrial abnormality.

The QRS complex duration is normal (0.10 sec), and the axis is normal, between 0° and +90° (positive QRS complex in leads I and aVF). The QT/QTc intervals are normal (440/430 msec). The morphology of the QRS complex is normal, but there is a marked increase in R-wave amplitude; it is 50 mm in lead V5 ( ]), which meets one of the criteria for left ventricular hypertrophy (LVH; S-wave depth or R-wave amplitude in any precordial lead ≥ 25 mm). Also noted are marked ST-T wave changes (asymmetrically inverted or biphasic T waves) in most leads with ST-segment depression (↑) in leads V4-V6. These are repolarization abnormalities associated with LVH and are due to chronic ischemia of the subendocardial layer caused by a reduction in subendocardial perfusion and oxygen supply resulting from LVH.

An ECG such as this can often raise suspicion for silent ischemia or an acute coronary syndrome. In the absence of clinical evidence for cardiac ischemia (no chest discomfort, dyspnea, pre-syncope, or nausea), this ECG is unlikely to indicate acute coronary ischemia. The pattern is much more typical of severe LVH with secondary repolarization changes attributable to increased wall stress. The primary goal of therapy should be to treat the hypertension and reduce wall stress. Since the patient's blood pressure is not dangerously high, it is reasonable to start an oral antihypertensive medication and have the patient return to the outpatient office for further titration of the regimen. With aggressive treatment of the hypertension, there may be some resolution of the LVH and ECG changes. ■

Core Case 11

You are asked to interpret an ECG performed at a preoperative anesthesia clinic. The patient plans to undergo elective rotator cuff surgery the following day.

ECG 11A

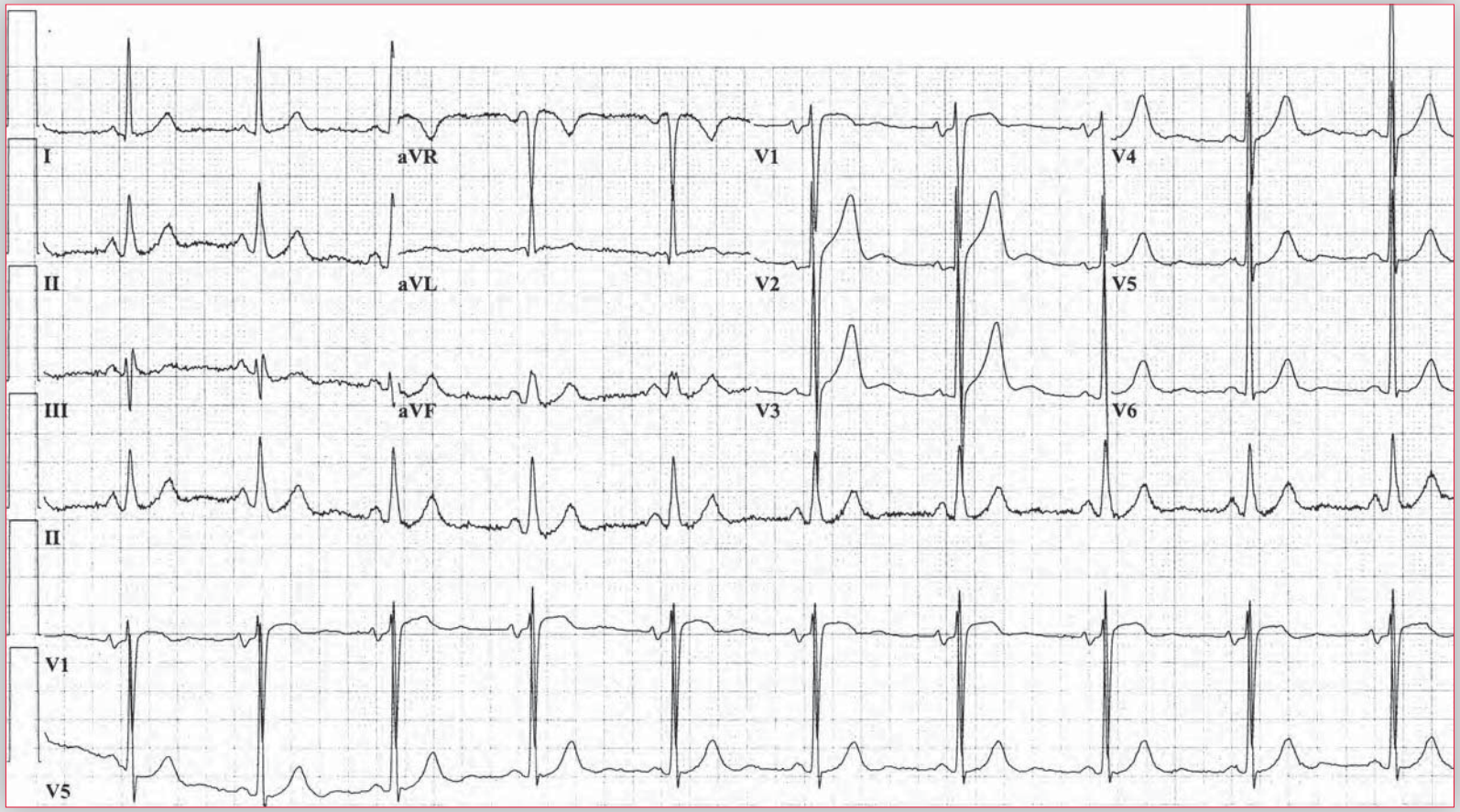

The treating physicians are concerned about left ventricular hypertrophy. The patient has a normal physical examination and feels well.

What do the ECGs show?

What is the likely diagnosis?

ECG 11B

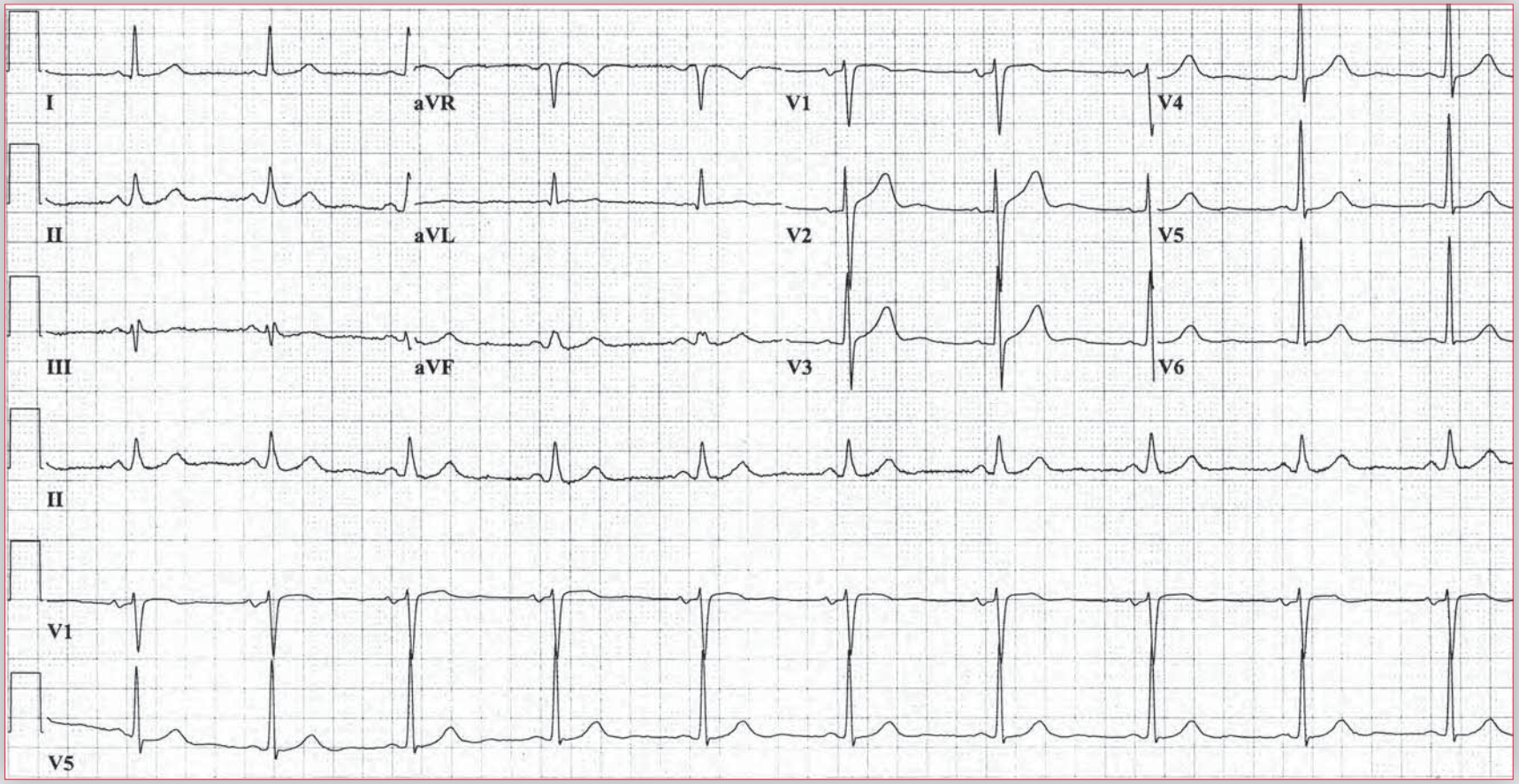

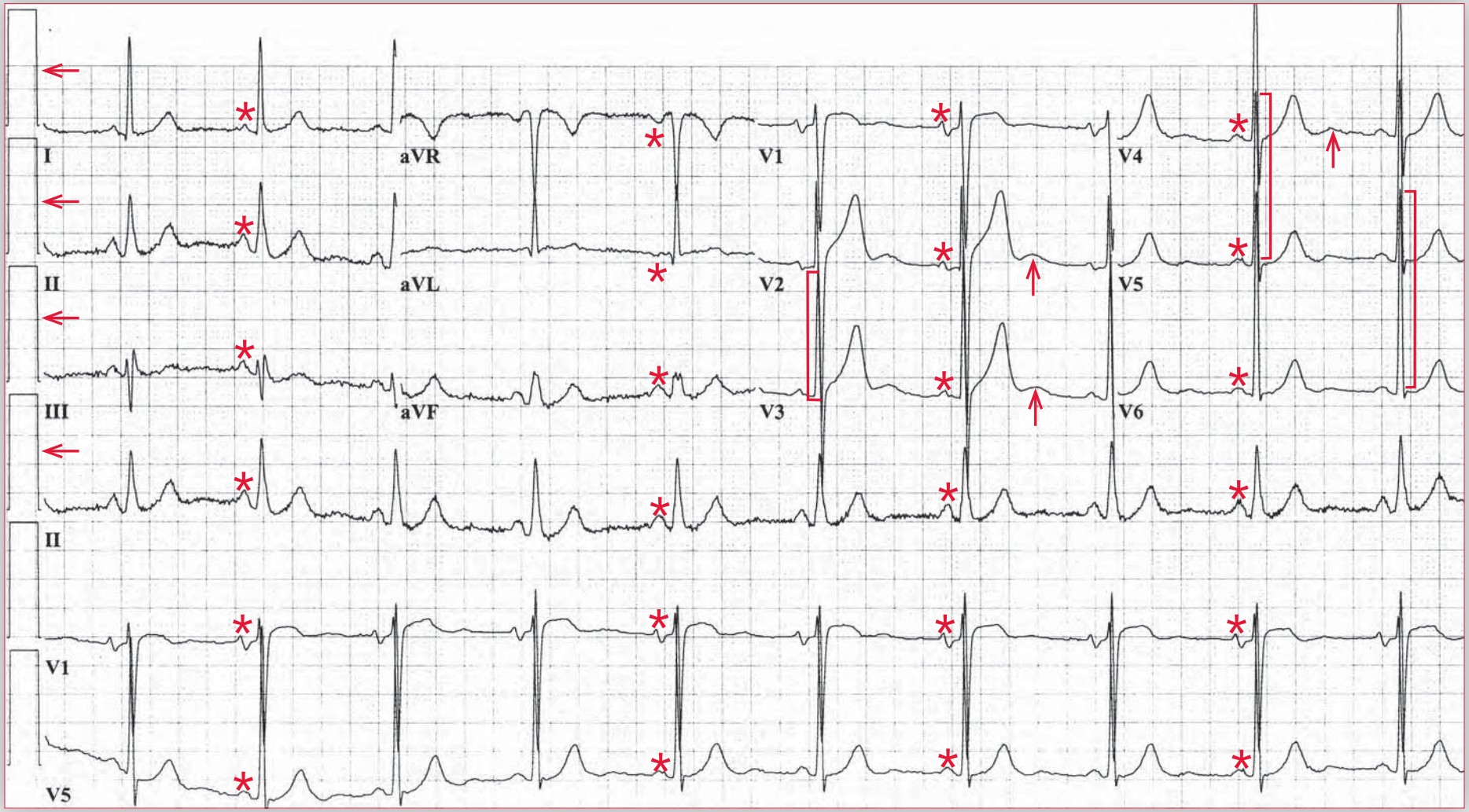

ECG 11A Analysis: Normal sinus rhythm,
ECG recorded at double standard, U waves

In **ECG 11A**, there is a regular rhythm at a rate of 60 bpm. There is a P wave (*) before each QRS complex, and the PR interval is stable (0.14 sec). The P waves are upright in leads I, II, aVF, and V4-V6. This is a normal sinus rhythm.

The QRS complex duration is normal (0.10 sec), and the morphology is normal. The QT/QTc intervals are normal (400/400 msec). The axis is normal, between 0° and +90° (positive QRS complex in leads I and aVF). The R waves in leads V4-V6 ( ]) have an increased amplitude (30 to 35 mm or small boxes), and the S wave in lead V2 is deep (27 mm or small boxes) ([ ) (S-wave depth in lead V2 + R-wave amplitude in lead V6 = 62 mm). This meets one of the criteria for left ventricular hypertrophy (LVH; S-wave depth in lead V1 or V2 + R-wave amplitude in lead V5 or V6 ≥ 35 mm). Also noted are prominent U waves (↑) in leads V1-V4. However, it should be noted that the ECG was recorded at double standard (←), that is, 1 mV equals 20 mm (20 small boxes) rather than at normal standard (1 mV = 10 mm or 10 small boxes). Hence the normal amplitude of the R wave or S wave is half of what is measured. Thus, LVH is not present.

continues

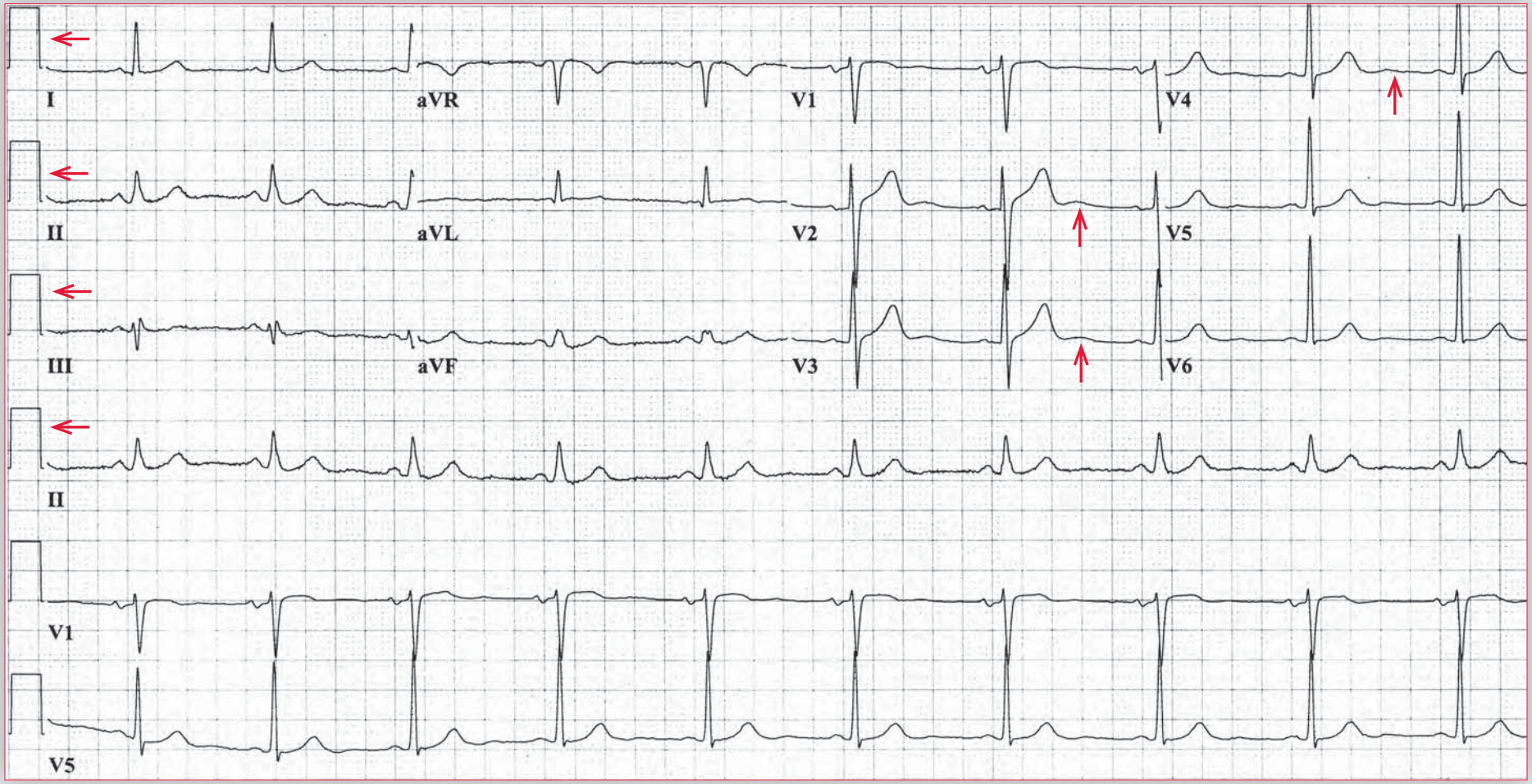

ECG 11B Analysis: Normal ECG recorded at normal standard

ECG 11B, obtained from the same patient, is recorded at normal standardization (←). The P-wave morphology, PR interval, QRS complex duration and axis, and QT/QTc intervals are the same as noted in **ECG 11A**. However, it should be noted that the amplitude (voltage) of the QRS complexes is normal and there is no evidence of LVH. U waves are still seen in leads V2-V3, but they are less prominent (↑). ■

Notes

A 33-year-old man with a history of surgically corrected tetralogy of Fallot returns to his cardiologist for routine follow-up. He notes mild pedal edema, which has worsened since his last visit 6 months earlier. Examination is notable for a harsh systolic murmur along the left upper sternal border and a right-sided S4.

What does his ECG show?

What is the likely diagnosis?

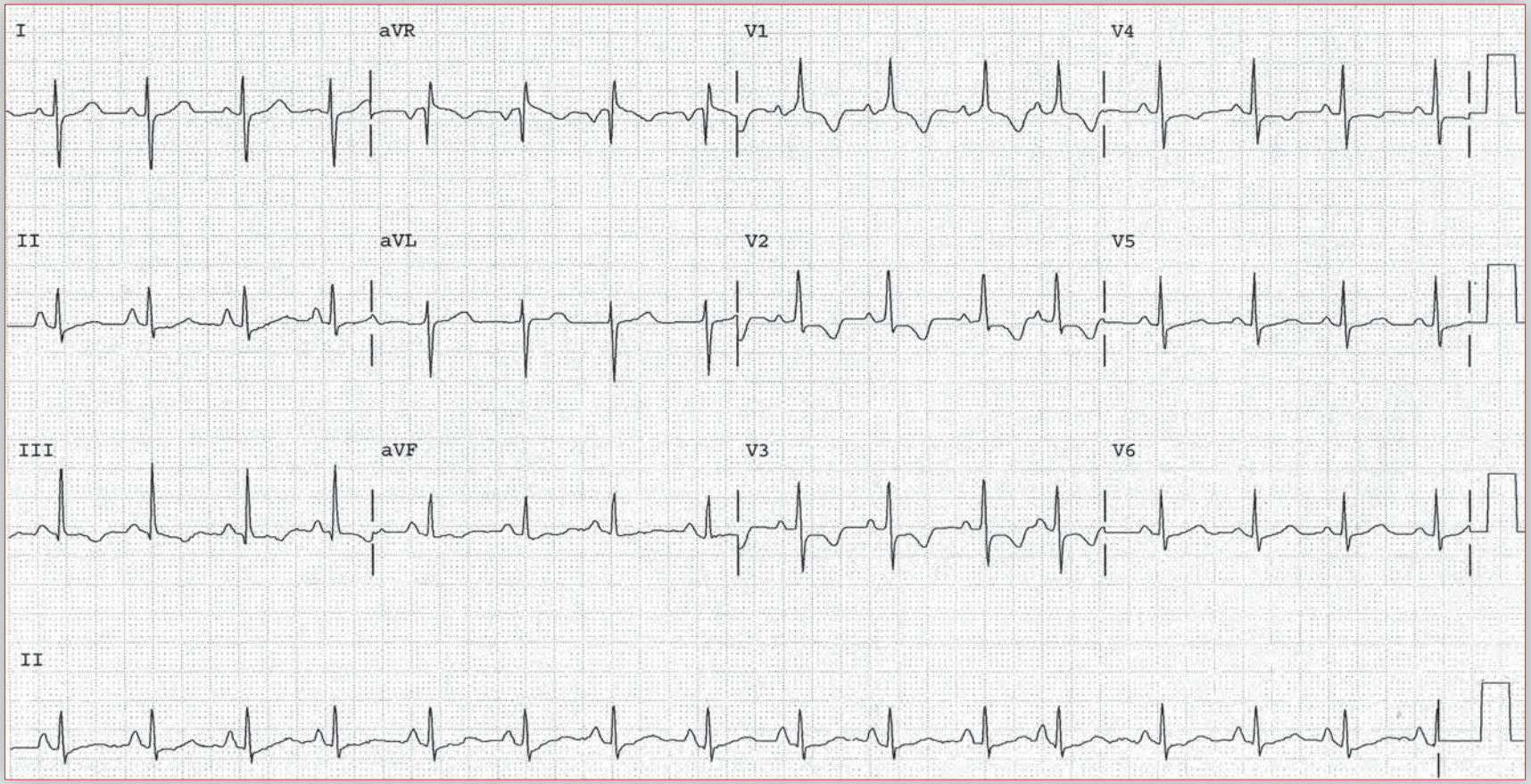

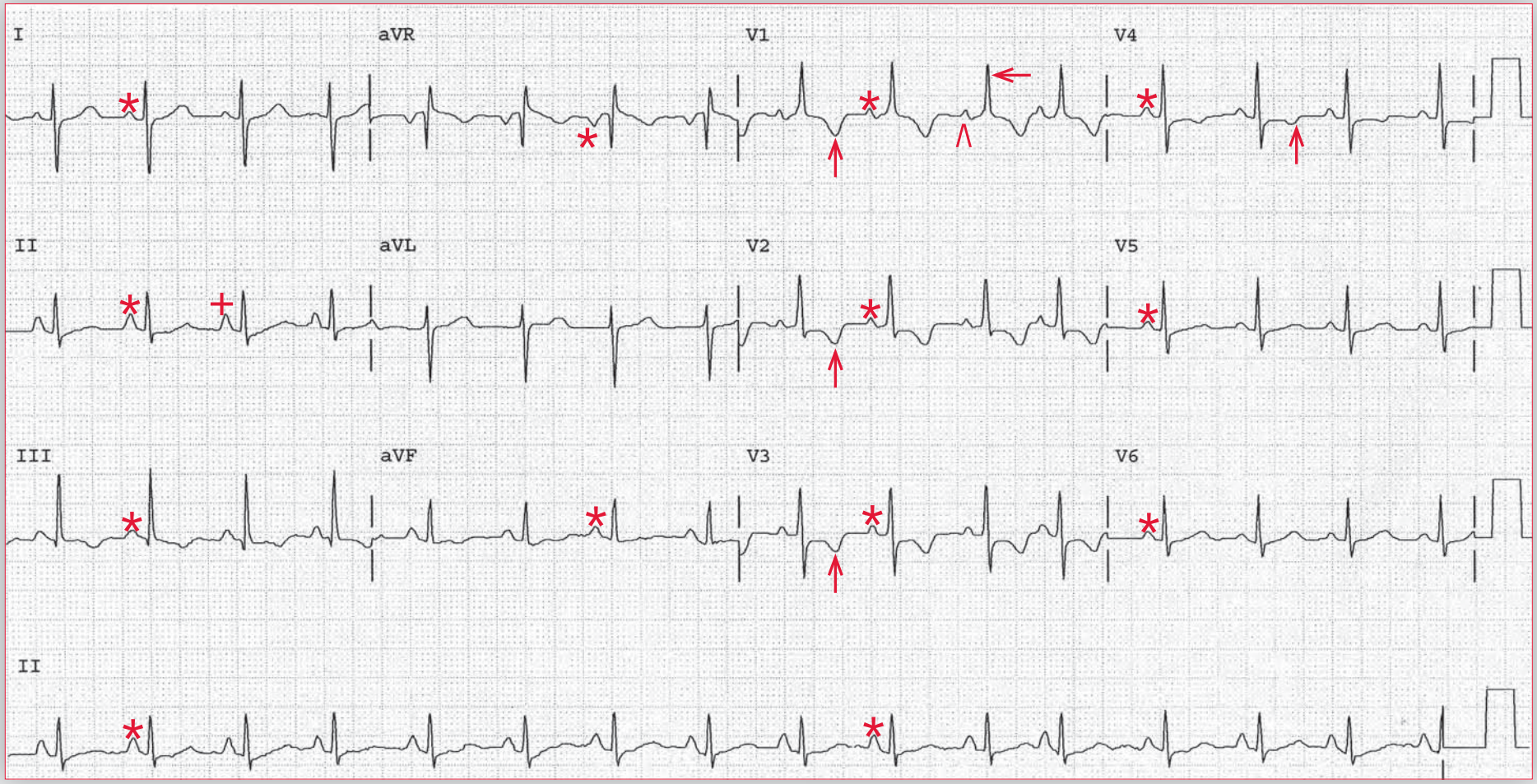

ECG 12 Analysis: Normal sinus rhythm, right atrial hypertrophy (abnormality), right ventricular hypertrophy with associated repolarization abnormalities (ST-T wave changes), right axis deviation

There is a regular rhythm at a rate of 94 bpm. There is a P wave (*) before each QRS complex, and the PR interval is stable (0.16 sec). The P waves are positive in leads I, II, aVF, and V4-V6. This is a normal sinus rhythm. The P waves are positive in lead V1 (^) and tall and peaked in lead II (+) (P pulmonale), suggestive of right atrial hypertrophy (abnormality).

The QRS complex duration is normal (0.08 sec). There is a tall R wave in lead V1 (←) that is 9 mm in amplitude, and there is no S wave, so the R/S ratio is greater than 1; these meet criteria for right ventricular hypertrophy (*ie*, R-wave amplitude in lead V1 ≥ 7 mm or R/S > 1). The QRS axis is rightward, between +90° and +180° (negative QRS complex in lead I and positive QRS complex in lead aVF). There are a number of causes for a right axis deviation that should be considered. These include right ventricular hypertrophy (associated with a tall R wave in lead V1 and right atrial hypertrophy or abnormality), a lateral wall myocardial infarction (a deep Q wave in leads I and aVL), right–left arm lead switch (associated with a negative P wave and T wave in leads I and aVL), dextrocardia (which resembles right–left arm lead switch and also has reverse R-wave progression across the precordium), Wolff-Parkinson-White pattern (with a prolonged QRS complex duration due to a delta wave and a short PR interval), and a left posterior fascicular block (a diagnosis of exclusion when there are no other causes for the right axis deviation). The QT/QTc intervals are normal (320/400 msec).

The tall R wave in lead V1 (←) along with the right axis deviation and right atrial hypertrophy are characteristic of right ventricular hypertrophy. Also noted are ST-T wave changes in leads V1-V4 (↑). These abnormalities are associated with right ventricular hypertrophy and, similar to the situation with left ventricular hypertrophy, they represent subendocardial ischemia of the right ventricular myocardium due to reduced endocardial perfusion of the hypertrophied right ventricular myocardium.

Tetralogy of Fallot (TOF) is a congenital abnormality that results from anterior deviation of a portion of the infundibular septum into the right ventricular outflow tact (RVOT). TOF presents with four characteristic abnormalities: RVOT obstruction, ventricular septal defect, overriding aorta (rightward deviation of the origin of the aorta), and concentric right ventricular hypertrophy. Most patients with TOF undergo intracardiac repair as the first operation. This procedure is aimed at relieving the RVOT obstruction by enlarging the RVOT; the ventricular septal defect is also closed with a patch. This patient has clinical and ECG evidence of persistent RVOT obstruction. Although the obstruction is reduced at the time of surgery, persistent RVOT obstruction or pulmonic insufficiency can be a long-term complication, depending on changes in the RVOT geometry as the heart grows. In cases of persistent RVOT obstruction the patient may require re-operation or catheter-based intervention to relieve the residual obstruction. ■

Notes

A 62-year-old man with known bicuspid aortic valve presents for evaluation of pedal edema and weight gain. He has been followed for several years for aortic stenosis but has been reluctant to undergo surgery. He has had no syncope and has remained free of chest discomfort by limiting his physical activity.

In recent months, he has gained weight and developed pedal edema. Exam shows an elevated jugular venous pressure with prominent V waves, harsh crescendo–decrescendo murmur at the right upper sternal border that radiates to the carotids, and a holosystolic murmur at the apex that radiates to the axilla.

What does his ECG show?

What is the likely diagnosis?

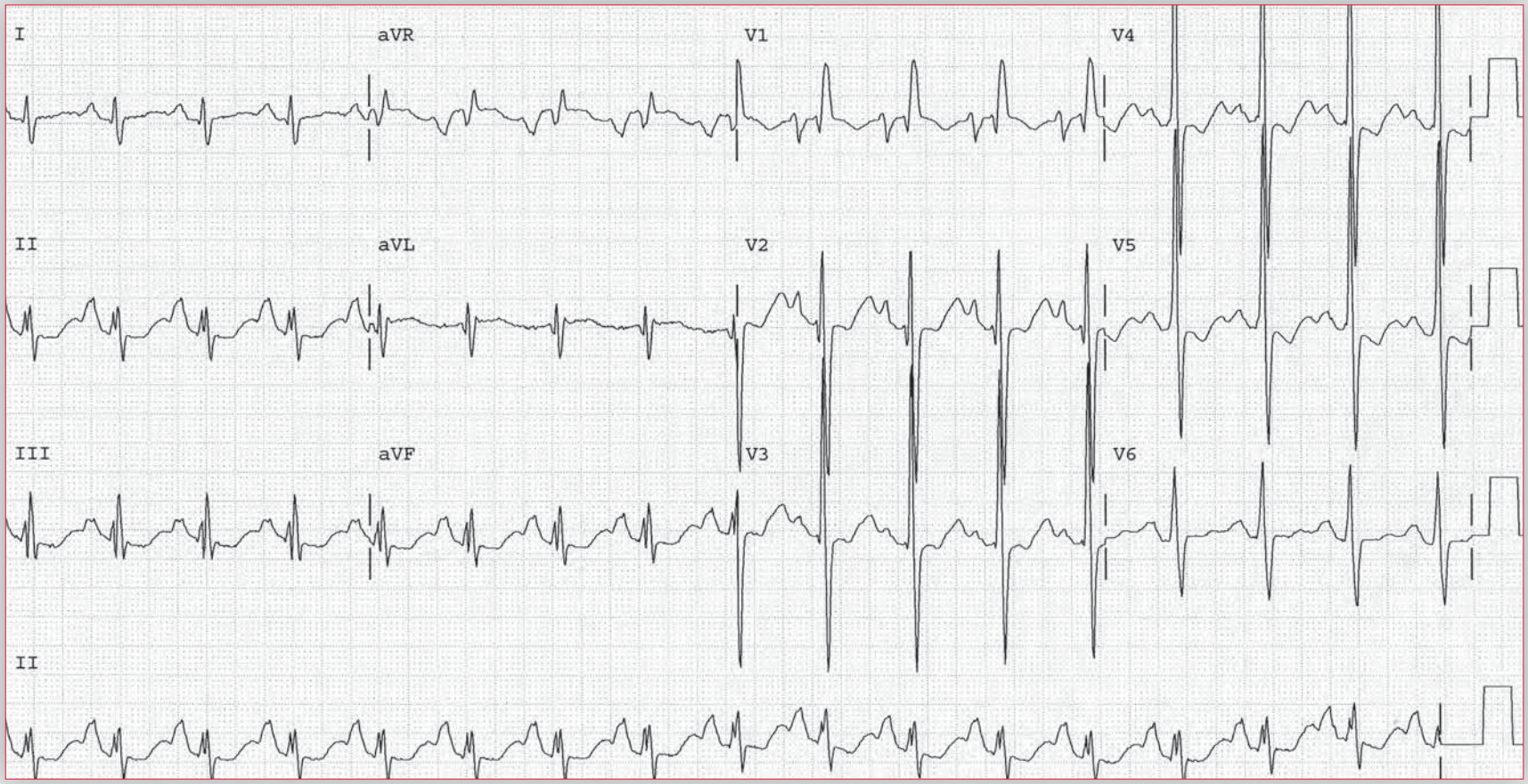

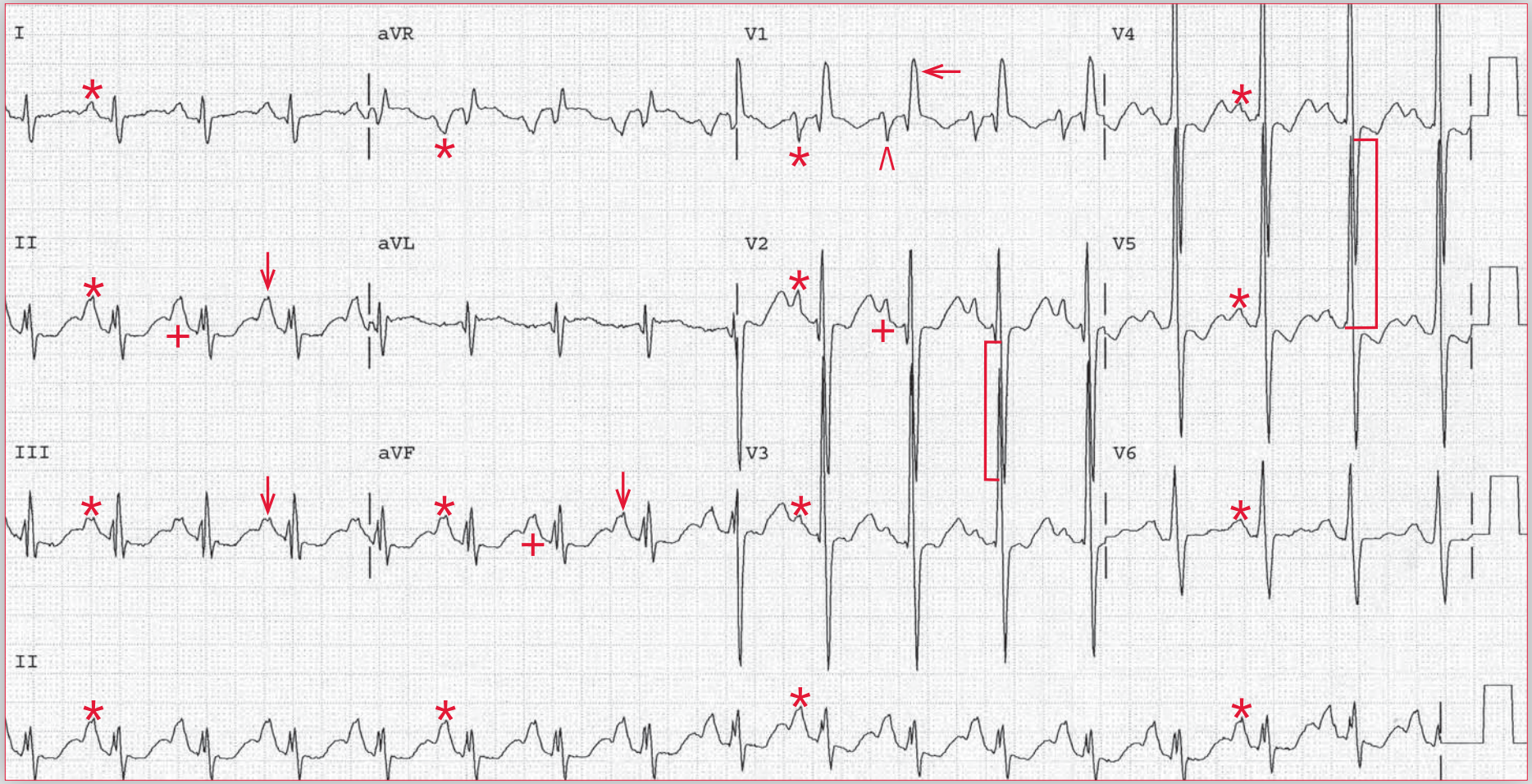

ECG 13 Analysis: Normal sinus rhythm, right atrial hypertrophy (abnormality), left atrial hypertrophy (abnormality), biatrial hypertrophy (abnormality), right axis deviation, right ventricular hypertrophy (RVH), left ventricular hypertrophy (LVH; biventricular hypertrophy), intraventricular conduction delay, QT prolongation

There is a regular rhythm at a rate of 98 bpm. There is a P wave (*) before each QRS complex, and the PR interval is stable (0.20 sec). The P wave is positive in leads I, II, aVF, and V4-V6 and negative in lead aVR. This is a normal sinus rhythm. The P waves are tall and peaked in leads II and aVF as well as in lead V2 (P pulmonale) (+). This is characteristic of right atrial hypertrophy (abnormality). There is also evidence of left atrial hypertrophy (abnormality), with broad P waves in leads II, III, and aVF (↓) and a marked negative component to the P wave in lead V1 (^). This represents biatrial hypertrophy (abnormality).

The QRS complex duration is prolonged (0.12 sec) with a nonspecific morphology (intraventricular conduction delay), and the axis is rightward, between +90° and +180° (negative QRS complex in lead I and positive QRS complex in lead aVF). There are a number of causes for a right axis deviation that should be considered. These include right ventricular hypertrophy (RVH; associated with a tall R wave in lead V1 and right atrial hypertrophy or abnormality), a lateral wall myocardial infarction (a deep Q wave in leads I and aVL), right–left arm lead switch (associated with a negative P wave and T wave in leads I and aVL), dextrocardia (which resembles right–left arm lead switch and also has reverse R-wave progression across the precordium), Wolff-Parkinson-White pattern (with a prolonged QRS complex duration due to a delta wave and a short PR interval), and a left posterior fascicular block (a diagnosis of exclusion when there are no other causes for the right axis deviation). The QT/QTc intervals are prolonged (400/510 msec), even when the prolonged QRS complex duration is considered (360/460 msec).

There is a tall R wave in lead V1 (←), which, along with the right axis deviation and the right atrial hypertrophy, is characteristic of RVH. In addition, the R-wave amplitude in lead V5 (33 mm) ( ]) and the S-wave depth in lead V2 (27 mm) ([ ) (S-wave depth in lead V2 + R-wave amplitude in lead V5 = 60 mm) meet one of the criteria for left ventricular hypertrophy (LVH; S-wave depth in lead V1 or V2 + R-wave amplitude in lead V5 or V6 ≥ 35 mm). Hence biventricular hypertrophy is present.

This patient has demonstrated the typical progression of symptomatic aortic stenosis. He has delayed symptoms by limiting his physical activity and has thereby delayed surgical repair. However, he has now developed evidence of biventricular and biatrial hypertrophy. Left ventricular dysfunction arises from decreased left ventricular compliance resulting from LVH. Left ventricular dilation occurs to reduce wall tension once the left ventricle has maximally hypertrophied. In the context of left ventricular dysfunction, pulmonary hypertension can arise from chronic elevation of the left ventricular end-diastolic pressure resulting from decreased compliance of the hypertrophied left ventricle. Pulmonary hypertension is a marker for poor survival both with and without valve replacement, but this patient's aortic stenosis has progressed to the point that surgical repair is imperative. The presence of coexisting mitral valve disease (*ie*, mitral stenosis or mitral regurgitation) should be considered as these conditions will also produce pulmonary artery hypertension resulting in RVH and right atrial hypertrophy. The presence of both aortic and mitral valvular disease is a common presentation for patients with rheumatic heart disease. ■

Notes

A 65 year-old man with severe chronic obstructive pulmonary disease (COPD) presents with weight gain and lower extremity edema. He was recently hospitalized for exacerbation of COPD and was discharged on a course of corticosteroids.

What does his ECG show?

What is the likely diagnosis?

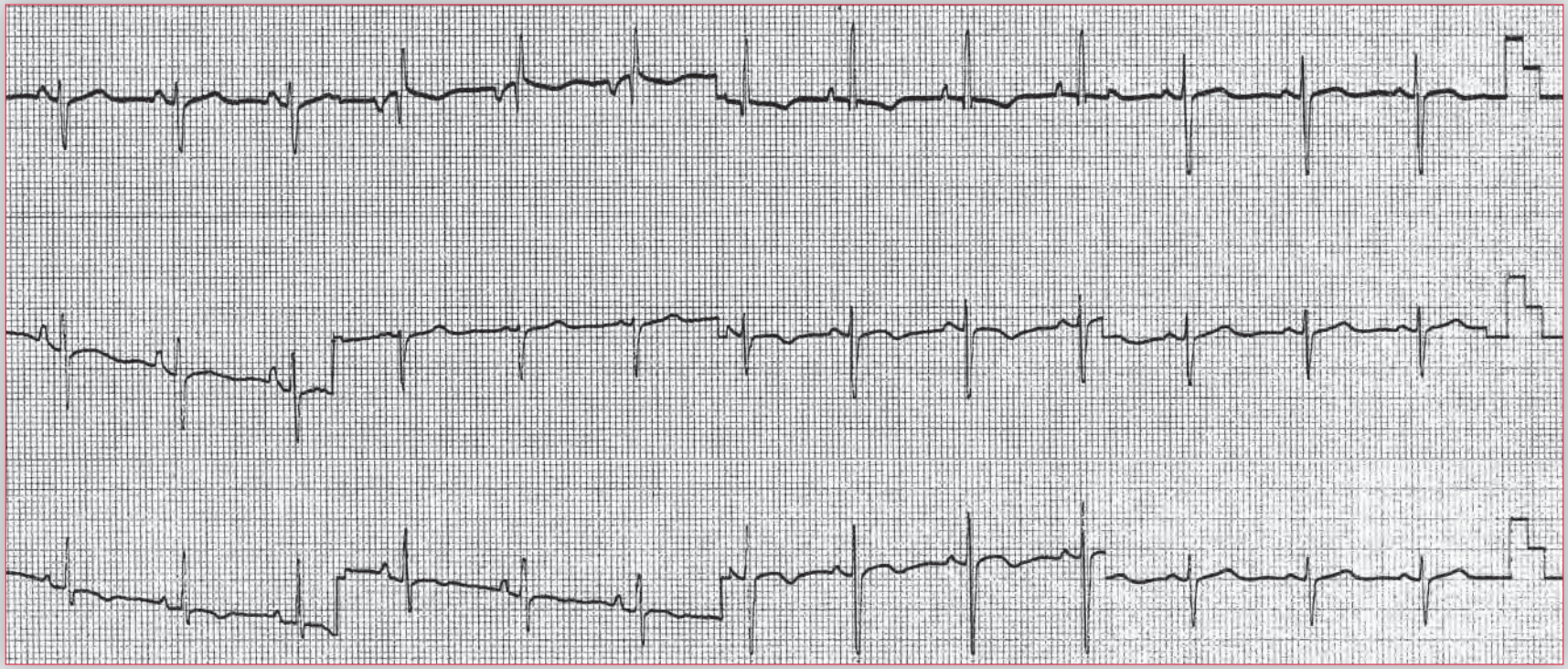

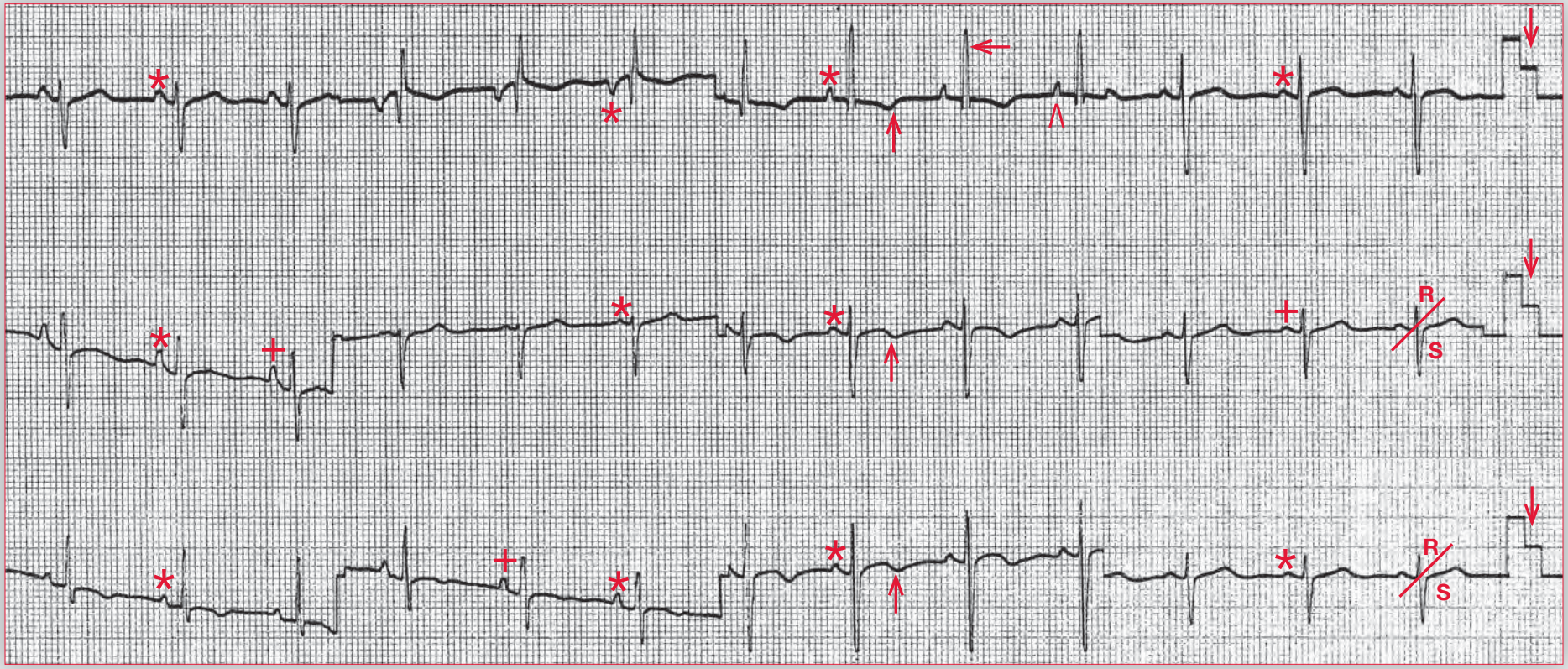

ECG 14 Analysis: Normal sinus rhythm, right atrial hypertrophy, right ventricular hypertrophy, right axis deviation, recorded at half-standard

Although the leads are not labeled, the pattern is always the same (column 1 is leads I, II, and III; column 2 is leads aVR, aVL, and aVF; column 3 is leads V1-V3; and column 4 is leads V4-V6). There is a regular rhythm at a rate of 86 bpm. There is a P wave (*) before each QRS complex, with a stable PR interval (0.16 sec). The P wave is positive in leads I, II, aVF, and V4-V6 and negative in lead aVR. This is a normal sinus rhythm. The P waves (+) are tall (0.3 mV), narrow (0.08 sec), and peaked in leads II and aVF and positive and tall in lead V1 (^). This is characteristic of P pulmonale or right atrial abnormality.

The QRS complex duration is narrow (0.08 sec), and the axis is rightward, between +90° and +180° (negative QRS complex in lead I and positive QRS complex in lead aVF). There are a number of causes for a right axis deviation that should be considered. These include right ventricular hypertrophy (associated with a tall R wave in lead V1 and right atrial hypertrophy or abnormality), a lateral wall myocardial infarction (a deep Q wave in leads I and aVL), right–left arm lead switch (associated with a negative P wave and T wave in leads I and aVL), dextrocardia (which resembles right–left arm lead switch and also has reverse R-wave progression across the precordium), Wolff-Parkinson-White pattern (with a prolonged QRS complex duration due to a delta wave and a short PR interval), and a left posterior fascicular block (a diagnosis of exclusion when there are no other causes for the right axis deviation).

There is a tall R wave in lead V1 (11 mm) (←), and there is an S/R greater than 1 in lead V6; these meet criteria for right ventricular hypertrophy (*ie*, R-wave amplitude in lead V1 ≥ 7 mm and S/R in lead V6 > 1). There are also ST-T wave changes in leads V1-V3 (↑). However, while the limb leads were recorded at normal standard (1 mV = 10 mm), the precordial or chest leads were recorded at half-standard (↓) (1 mV = 5 mm). Hence the actual amplitude of the R wave in lead V1 is 22 mm. The tall R-wave voltage in lead V1 along with the right axis deviation, ST-T wave changes in leads V1-V3, and right atrial hypertrophy are characteristic of right ventricular hypertrophy.

This patient has right ventricular and right atrial hypertrophy arising in the context of COPD; this is termed cor pulmonale. This entity describes any cause of right heart dysfunction caused by the pulmonary vasculature. In COPD, pulmonary hypertension can arise from multiple causes, including hypoxic vasoconstriction, destruction of the pulmonary vascular bed by scarring emphysema, and increased pulmonary blood flow. The presence of cor pulmonale is a marker for advanced COPD and portends a poor prognosis. Treatment of cor pulmonale is focused on improving oxygenation (supplemental oxygen) and diuretic therapy to minimize peripheral edema. Pulmonary vasodilators can be used, but success is often limited in this setting. ■

Notes

A 28-year-old man presents for a pre-employment physical examination. He has no complaints. Physical examination is normal.

What does his ECG show?

What is the likely diagnosis?

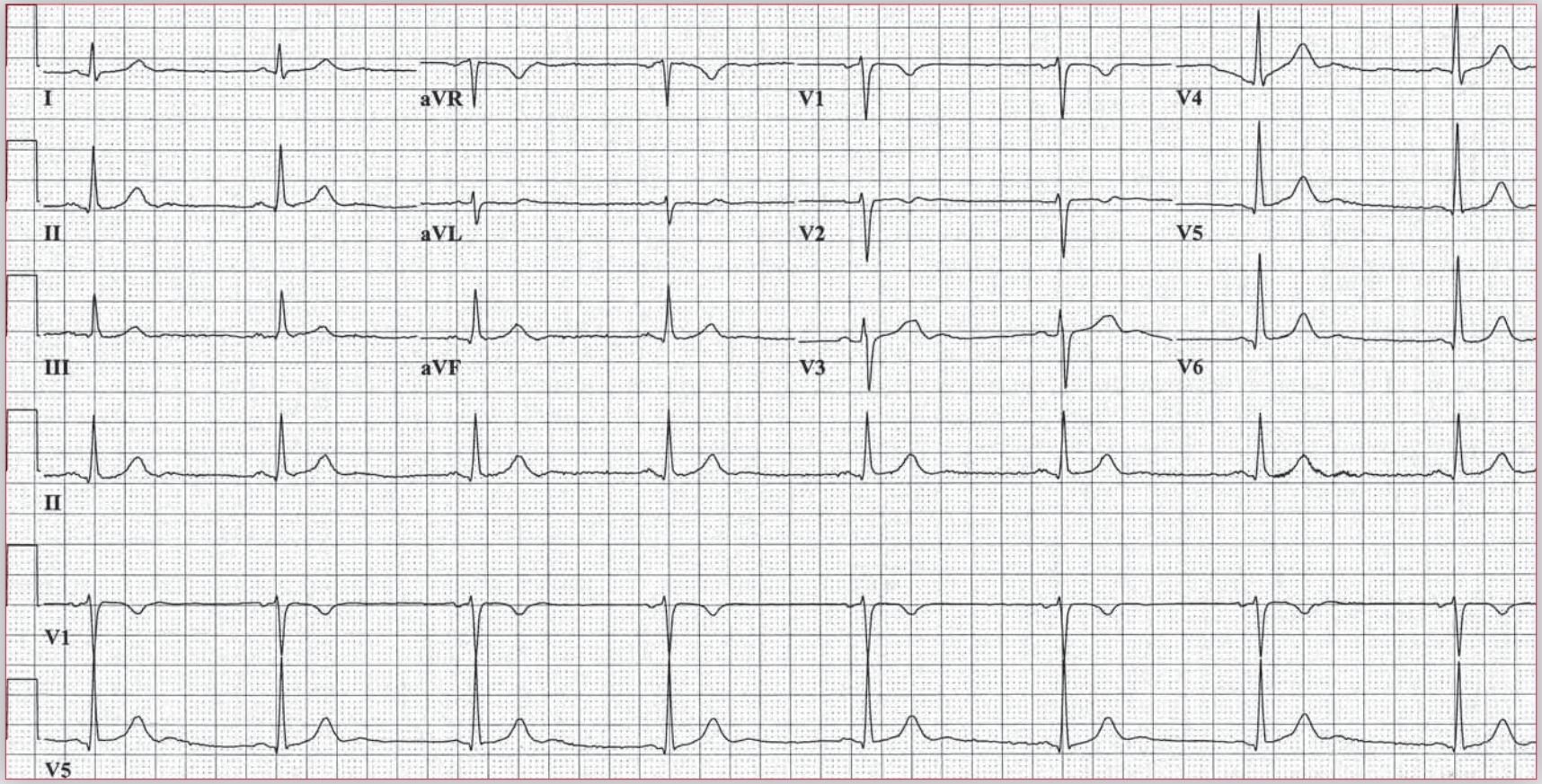

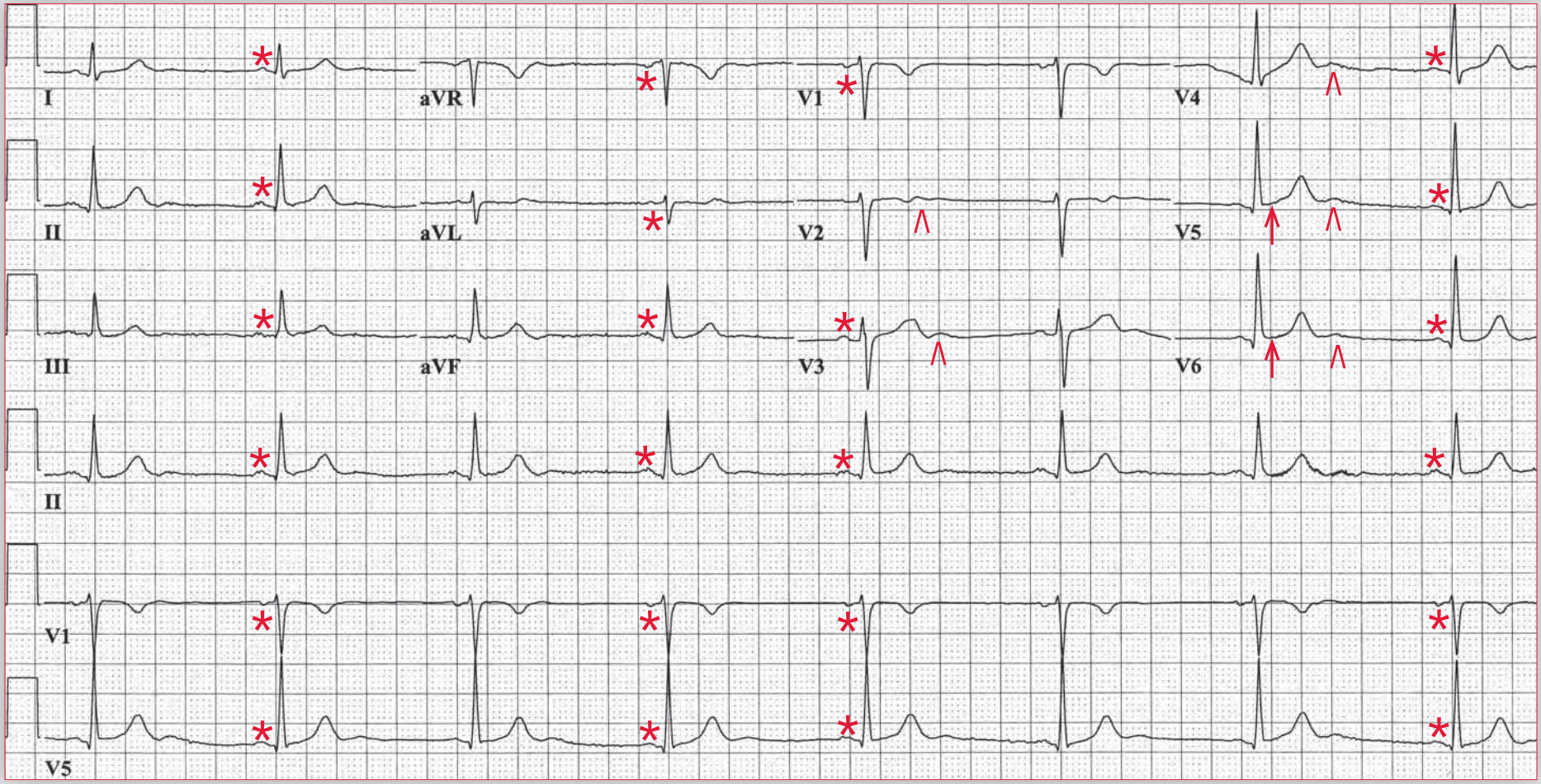

ECG 15 Analysis: Sinus bradycardia, early repolarization, prominent U waves

The rhythm is regular at a rate of 46 bpm. There is a P wave (*) in front of each QRS complex, and the PR interval is stable (0.16 sec). The P wave is positive in leads I, II, aVF, and V4-V6 and negative in lead aVR. This is a sinus bradycardia. The P-wave morphology is normal.

The QRS complex duration is normal (0.08 sec), and the axis is normal, between 0° and +90° (positive QRS complex in leads I and aVF). The QRS morphology is normal, and there is normal R-wave progression across the precordium. The QT/QTc intervals are also normal (400/350 msec). U waves (^) can be seen after the T waves in leads V3-V6. The ST segments have a normal configuration (*ie*, they are slightly concave). The J point and ST segments in leads V5-V6 are slightly above baseline (↑), which is defined by the TP segment. This is a normal ECG with minimal early repolarization.

Early repolarization is seen in about 5% of normal ECGs, most often in the lateral precordial leads (V4-V6). It does not have any known pathologic correlates and does not portend adverse events. It is most commonly observed in young men as well as in the black population but can be seen at any age in either sex and in any ethnic group. It is often seen with tall QRS voltage (with or without left ventricular hypertrophy) as an exaggeration due to the increased QRS complex amplitude. The abnormalities can sometimes be dynamic, which may raise concern for myocardial ischemia or pericarditis. In these cases, the ECG findings must be considered in the clinical context. Moreover, with pericarditis the ST-segment elevations are diffuse, involving most or all leads. An acute myocardial infarction usually has associated hyperacute T waves (tall, peaked, and symmetric) as well as reciprocal ST-segment depressions. Sinus bradycardia, defined as a heart rate less than 60 bpm, is a common finding in young, healthy patients. ■

Notes

A 28-year-old woman presents for evaluation of palpitations. She often notes that she feels "extra beats" when lying still in bed. She denies any syncope or pre-syncope. She feels well otherwise. Her internist obtains an ECG and refers her for further evaluation of possible coronary artery disease.

What does her ECG show?

What is the likely diagnosis?

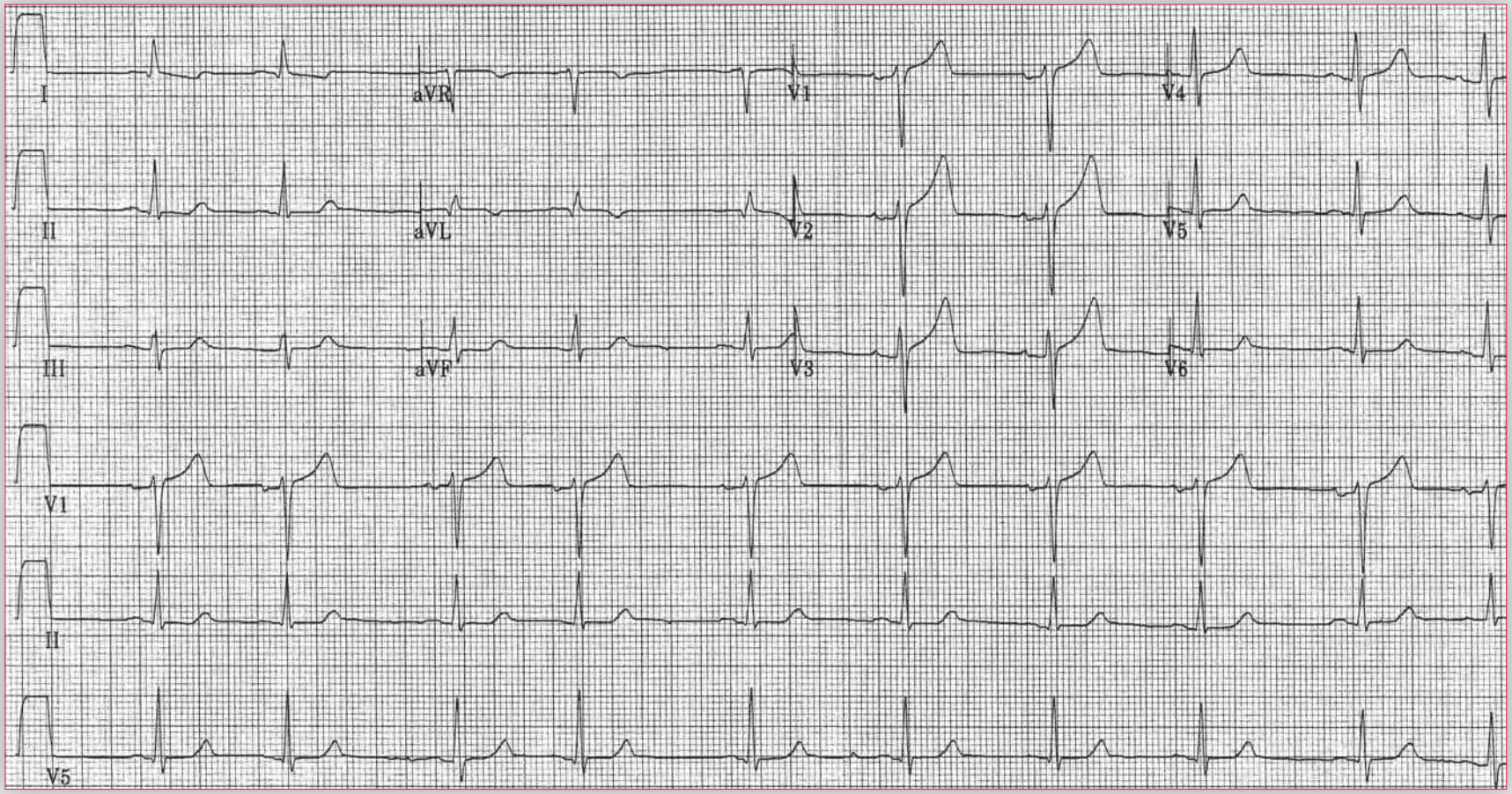

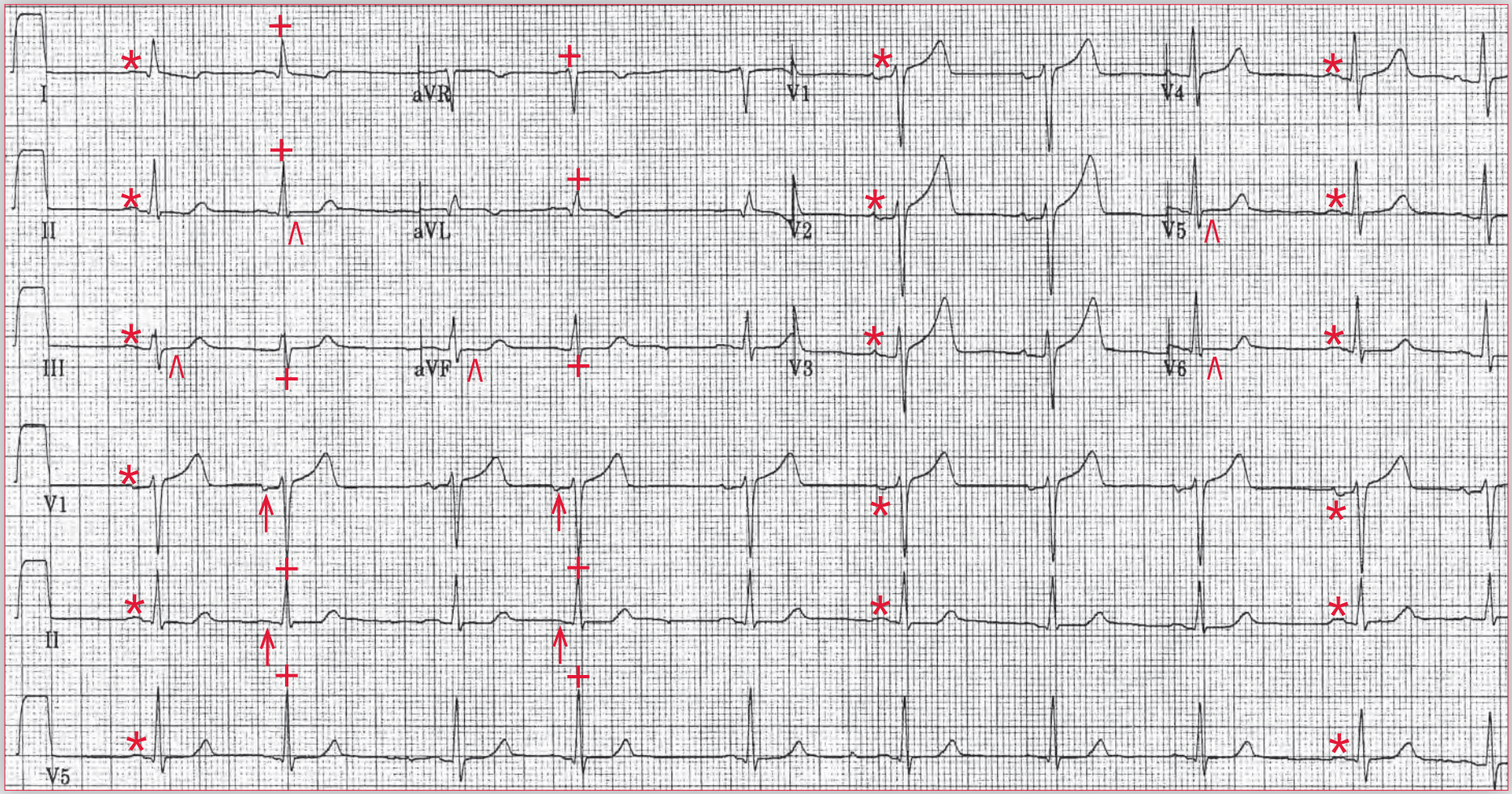

ECG 16 Analysis: Normal sinus rhythm, premature atrial complexes (PACs), nonspecific ST-segment flattening

The rhythm is basically regular at a rate of 60 bpm. There is a P wave (*) before each QRS complex, and the PR interval is stable (0.18 sec). The P wave is positive in leads I, II, aVF, and V4-V6 and negative in lead aVR. This is a normal sinus rhythm. There are, however, two QRS complexes that are early or premature (second and fourth) (+). They have a QRS morphology that is identical to all of the other QRS complexes. Both are preceded by a P wave (↑), but the P-wave morphology is slightly different from those of the sinus complexes (*ie*, they are negative in lead V1 compared with the sinus P wave, which is biphasic in lead V1 and flat in lead II compared with the sinus P wave, which is positive in lead II). These are, therefore, premature atrial complexes (PACs).

The QRS complex duration is normal (0.08 sec), and there is a normal QRS axis, between 0° and +90° (positive QRS complex in leads I and aVF). The QRS morphology is normal, with normal R-wave progression across the precordium. The QT/QTc intervals are normal (420/420 msec), and the T waves have a normal asymmetric morphology. The J point and ST segments are at baseline (*ie*, the same level as the TP segments). However, in some of the leads (*ie*, leads II, III, aVF, and V5-V6) the ST segments (^) no longer have their normal concave morphology but are flattened. This is a nonspecific ST-segment abnormality, which does not imply any cardiac abnormality if flattened without depression.

This patient has symptomatic PACs. PACs are a common finding that, if infrequent, are not considered pathologic. Although they are common in the general population, the frequency of PACs increases with age and they are more common in the presence of structural heart disease, exogenous stimulant administration, or other medical illnesses. No therapy is indicated for asymptomatic PACs. However, if a patient is bothered by palpitations, the symptoms can be suppressed with β-blockers (although β-blockers do not have any direct effect on the myocardium and do not generally suppress PACs). Not uncommonly, PACs trigger other atrial arrhythmias, such as atrial tachycardia, atrial flutter, and atrial fibrillation. Hence PACs are occasionally treated to prevent the occurrence of these sustained atrial tachyarrhythmias. Treatment to suppress PACs requires the use of antiarrhythmic agents that work on atrial myocardium and include the class IA, IC and III antiarrhythmic drugs. ■

Core Case 17

A 48-year-old woman is evaluated for atypical chest pain. Her father suffered a myocardial infarction in his early 50s, but she has no other risk factors. She is evaluated with an office exercise stress test.

ECG 17A

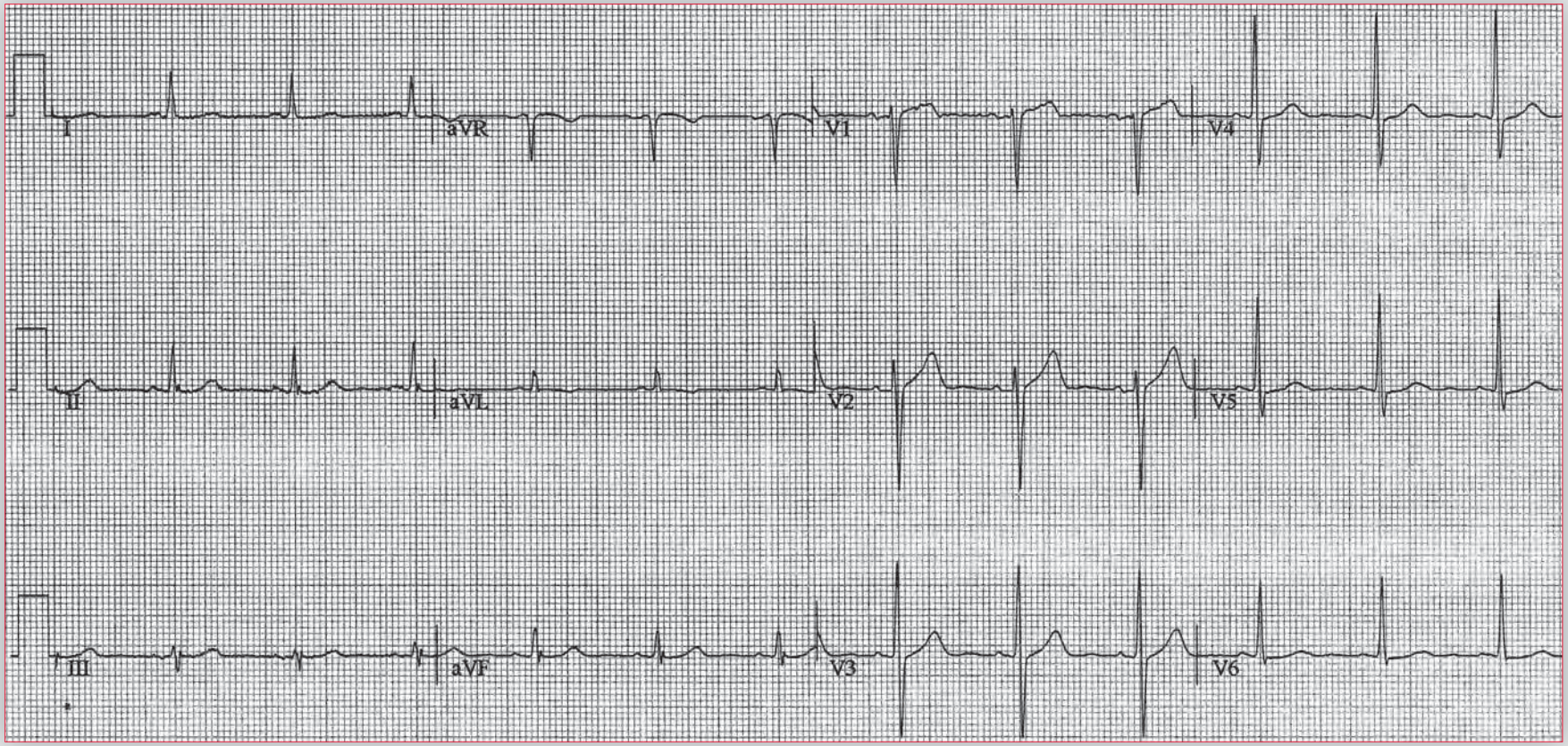

The technologist notes that there is a subtle change in the P-wave morphology, the PR interval duration, and the ST segment. ECG 17A is the patient's ECG before the stress test (baseline); ECG 17B was obtained after the stress test.

How do you explain these findings?

What is the diagnosis?

Is any further evaluation necessary?

ECG 17B

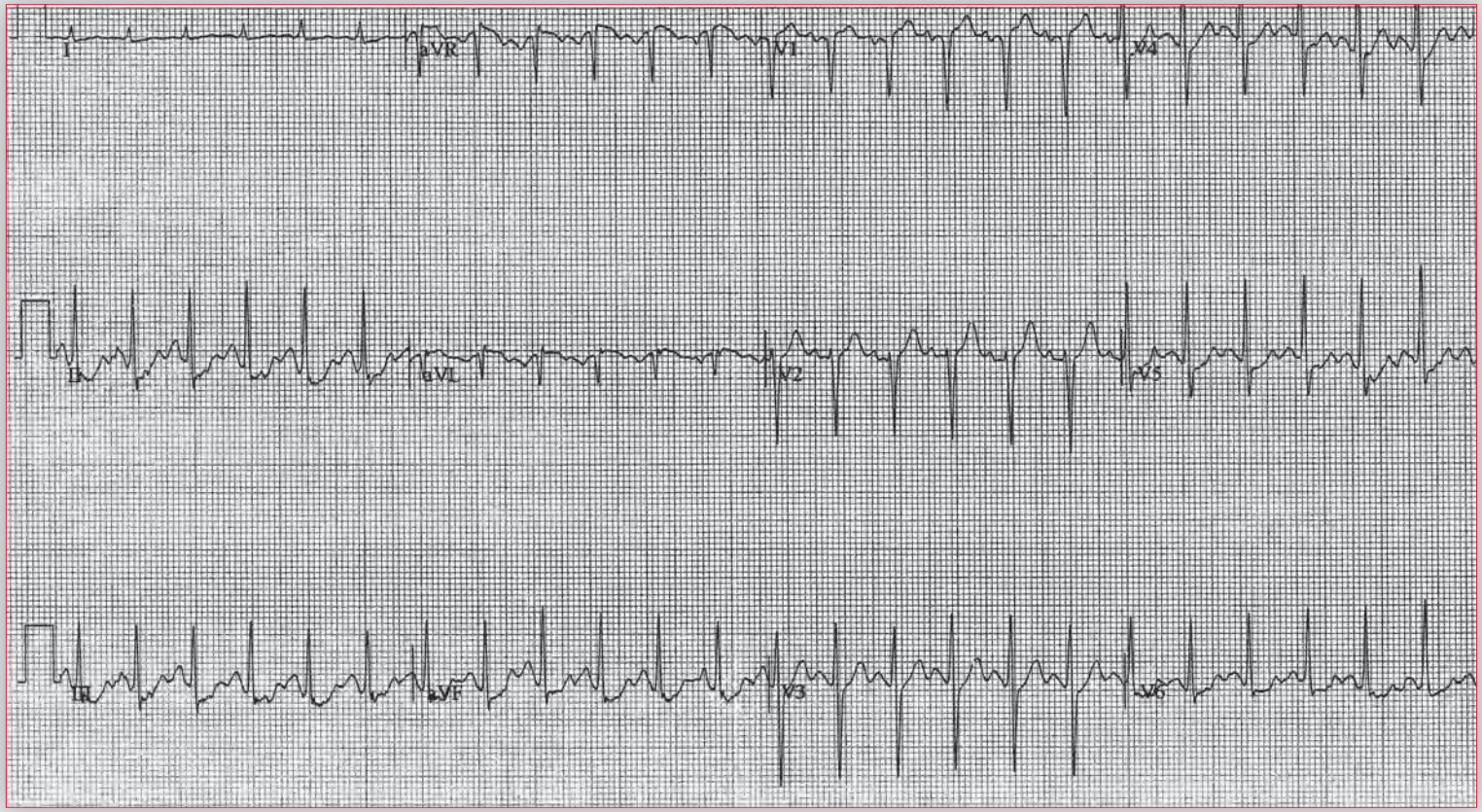

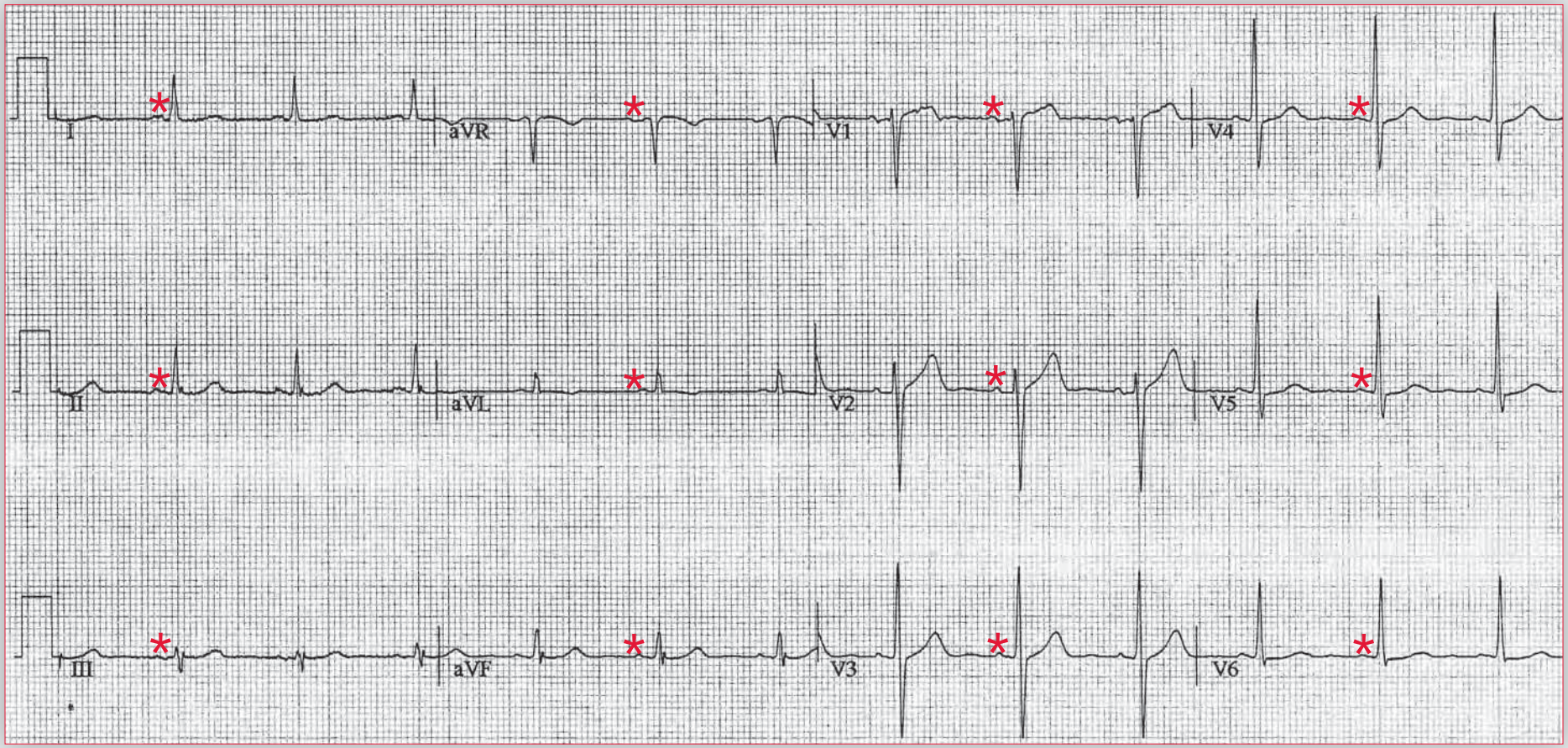

ECG 17A Analysis: Normal

ECG 17A shows a regular rhythm at a rate 76 bpm. There is a P wave (*) before each QRS complex, and the PR interval is stable (0.14 sec). The P wave is upright in leads I, II, aVF, and V4-V6 and negative in lead aVR. This is a normal sinus rhythm.

The QRS complex duration (0.08 sec) and morphology are normal. The axis is normal, between 0° and +90° (positive QRS complex in leads I and aVF). There is normal R-wave progression from leads V1 to V6. The ST segments, T waves, and QT/QTc intervals (360/400 msec) are also normal.

continues

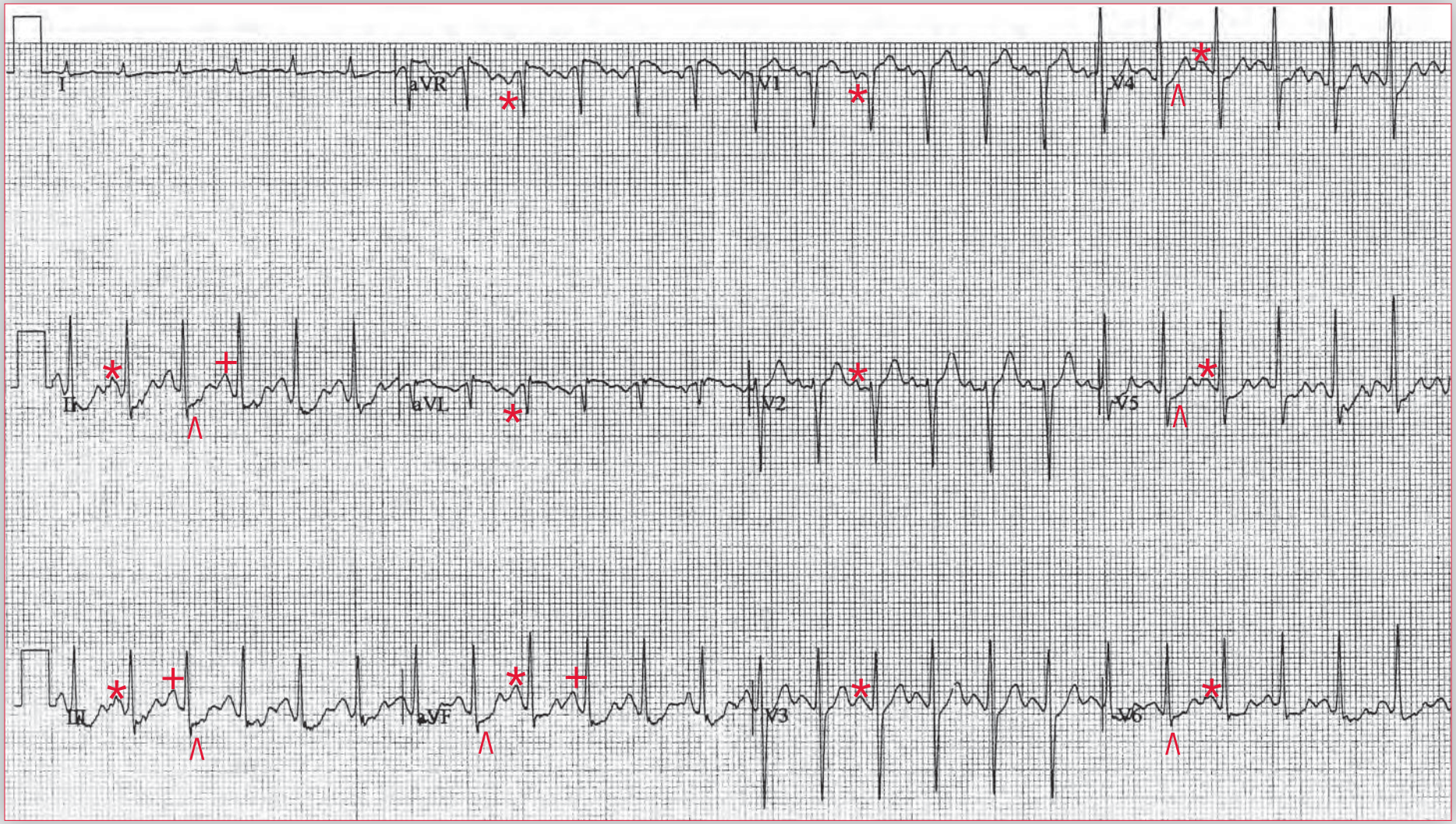

ECG 17B Analysis: Sinus tachycardia, upsloping ST-segment depression

ECG 17B was obtained immediately upon termination of the patient's exercise test on a treadmill. There is a regular rhythm at a rate of 150 bpm. There is a P wave (*) before each QRS complex, with a stable PR interval (0.14 sec). The P wave has the same axis and morphology as seen in **ECG 17A**; this is sinus tachycardia. Of note is the fact that the P waves have a greater amplitude in leads II, III, and aVF (+) compared with baseline. This is commonly seen with sinus tachycardia and is the result of a change in the direction of atrial activation originating from the sinus node (*ie*, atrial activation is more inferiorly directed).

Anatomically, the sinus node is a cylindric crescent-shaped structure located at the proximal portion of the right atrium. Within the sinus node are pacemaker cells that have different rates of action potential generation. The more proximal pacemaker cells generate an action potential at a faster rate compared with those located at the more distal end. The sinus node is also innervated by the parasympathetic and sympathetic nervous systems. There are more vagal fibers located at the proximal portion of the node compared with the distal portion. When vagal tone is increased (and sympathetic tone decreased), the pacemaker cells at the proximal portion of the node are suppressed and the dominant pacemaker location is shifted to the distal portion of the node where pacemaker activity is slower; so the heart rate slows. In addition, the activation of the atrial tissue occurs in a direction that is more horizontal and therefore parallel to lead I and perpendicular to leads II and aVF. In this situation the P wave is taller in lead I and of a lesser amplitude in leads II and aVF. When there is an increase in sinus rate, which is due to withdrawal of vagal tone and increased sympathetic tone, the location of dominant pacemaker activity is shifted to the more proximal portion of the node, where action potential generation is faster. Therefore, activation of the atrium is in a more vertical direction, parallel to leads II and aVF, so the amplitude of the P wave increases in these leads while it decreases in lead I.

continues

The QRS complex duration and morphology in **ECG 17B** are normal and are identical to those in **ECG 17A**. The QT/QTc intervals are normal (240/380 msec). However, there is pronounced J-point and ST-segment depression, particularly seen in leads II, III, aVF, and V4-V6 (^); note that ST-segment elevation in lead aVR is actually ST-segment depression. Although a TP segment is not obvious due to the sinus tachycardia, the PR segment can be used as baseline. The ST-segment depression is described as upsloping. Upsloping ST-segment depression may be a normal finding during sinus tachycardia or can be a manifestation of ischemia, although it is the least predictive. It should be remembered that atrial repolarization (*ie*, the T wave of the P wave) occurs during the QRS complex and hence is not seen. When the sinus rate increases, however, there is a shortening of the PR segment (due to sympathetic enhancement of conduction through the AV node), which causes the T wave of the P wave to move out from the QRS complex and fall on the J point, causing both the J point and the initial portion of the ST segment to be depressed. Therefore, the ST segment slopes upward to return to baseline. When there is upsloping ST-segment depression, it is standard practice to evaluate the degree of depression present at 80 msec (two small boxes) past the J point, which eliminates any effect from the atrial T wave on the J point and ST segment. If the ST segment at 80 msec past the J point is still depressed more than 1.5 mm below baseline (the TP segment or, if not obvious, the PR segment), then subendocardial ischemia is present.

In this case the ST segment is back to baseline at 80 msec past the J point. Hence, this is a normal rate-related change. ■

A 58-year-old man with hypertension, dyslipidemia, and a family history of cardiac disease presents for evaluation of cardiovascular risk prior to undergoing elective spine surgery. He undergoes an exercise stress test that provokes chest discomfort after 6 minutes; as a result the test is terminated. The ECG at 2 minutes of recovery is shown.

What does his ECG show?

What is the likely diagnosis?

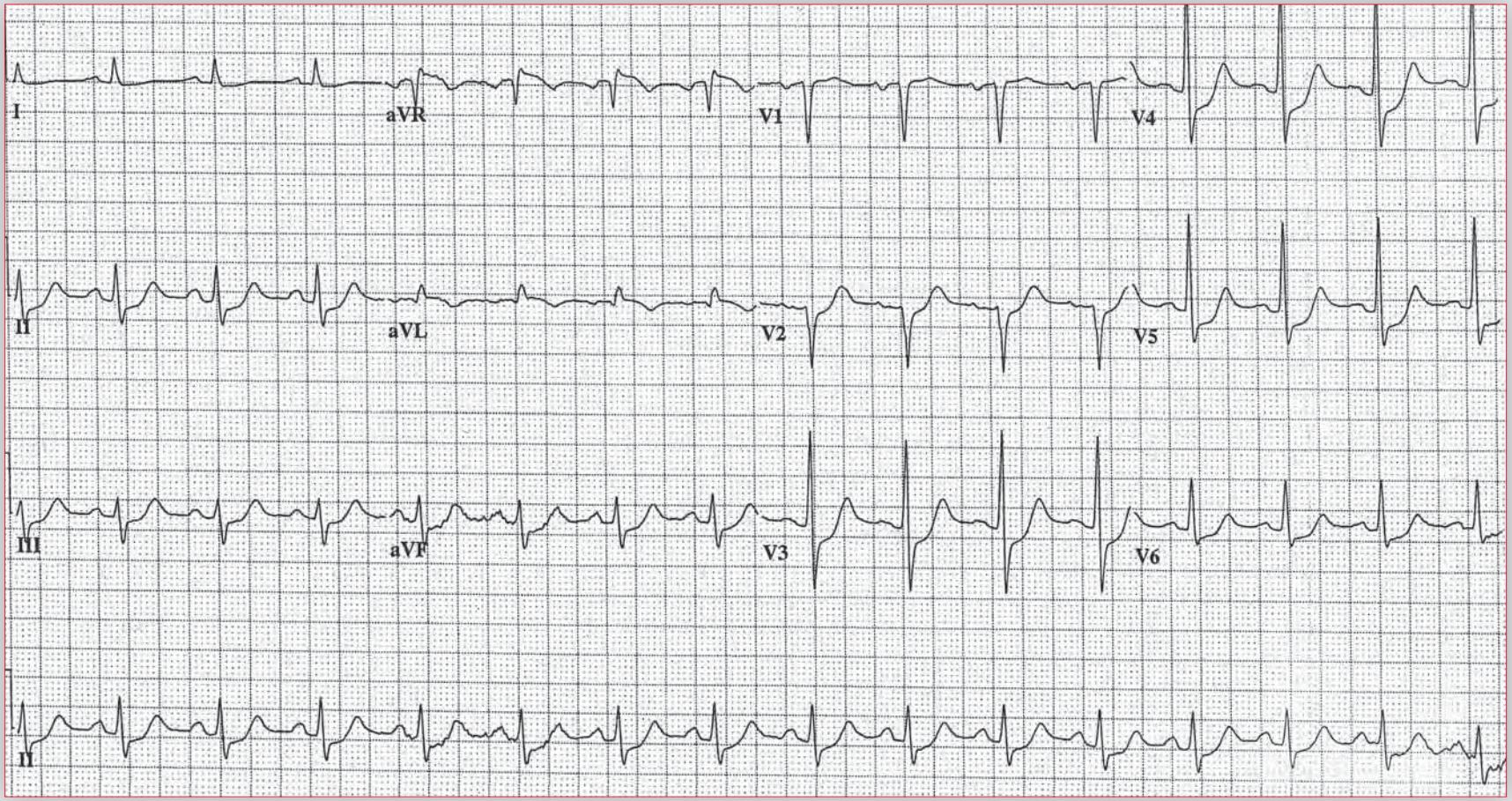

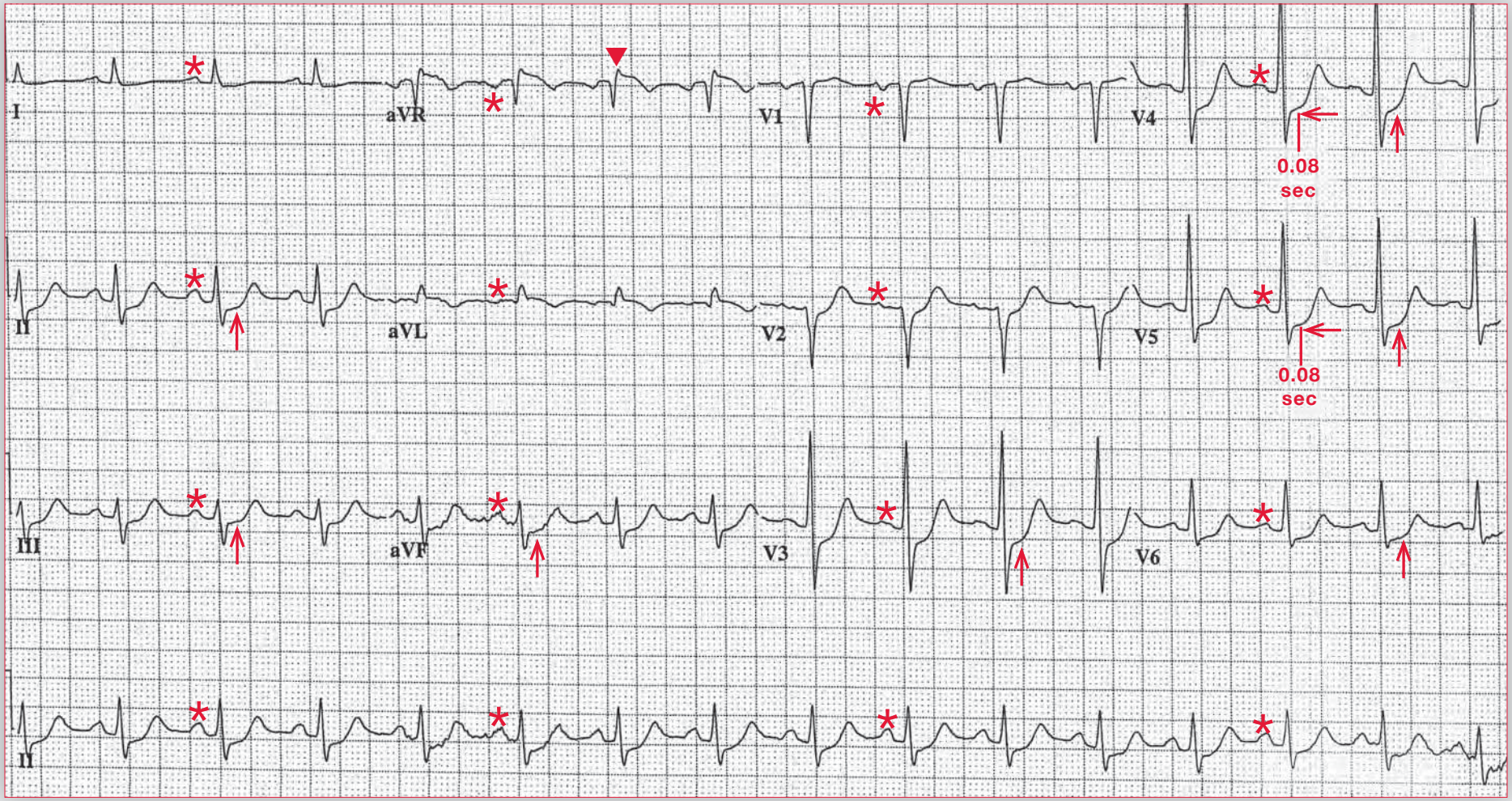

ECG 18 Analysis: Normal sinus rhythm, upsloping ST-segment depression

There is a regular rhythm at a rate of 92 bpm. There is a P wave (*) before each QRS complex, with a stable PR interval (0.16 sec). The P wave is positive in leads I, II, aVF, and V4-V6 and negative in lead aVR. The P-wave morphology is normal. This is a normal sinus rhythm.

The QRS complex duration is normal (0.08 sec), and it has a normal morphology and axis, between 0° and +90° (positive QRS complex in leads I and aVF). The QT/QTc intervals are normal (340/420 msec). J-point and ST-segment depression can be seen in leads II, III, aVF, and V2-V6 (↑); ST-segment elevation (▼) in lead aVR is actually ST-segment depression. The ST-segment depression is upsloping. However, at 0.08 sec past the J point (←) the ST segment is still depressed 2 mm below the baseline (TP segment). This is highly suggestive of an ischemic response. The location of ST-segment depression does not correlate with the location of the ischemia or with the coronary artery that is involved.

There are three types of ST-segment depression that reflect ischemia: upsloping, horizontal, and downsloping. Upsloping ST-segment depression is the least specific change of ischemia as it may be seen in sinus tachycardia as a rate-related change. However, when the ST segment remains more than 1.5 mm below baseline at 80 msec past the J point, it is diagnostic for ischemia. In addition, the upsloping ST-segment changes were seen at a rate of 92 bpm; therefore, they are not a normal rate-related change. ■

Notes

A 64-year-old woman with longstanding diabetes is evaluated for complaints of atypical chest discomfort (left-sided ache). She has been taking a β-blocker for hypertension. She undergoes an exercise stress test, which provokes her symptoms. The peak exercise ECG is shown below.

What does the ECG show?

What is the likely diagnosis?

What further diagnostic evaluation could be undertaken?

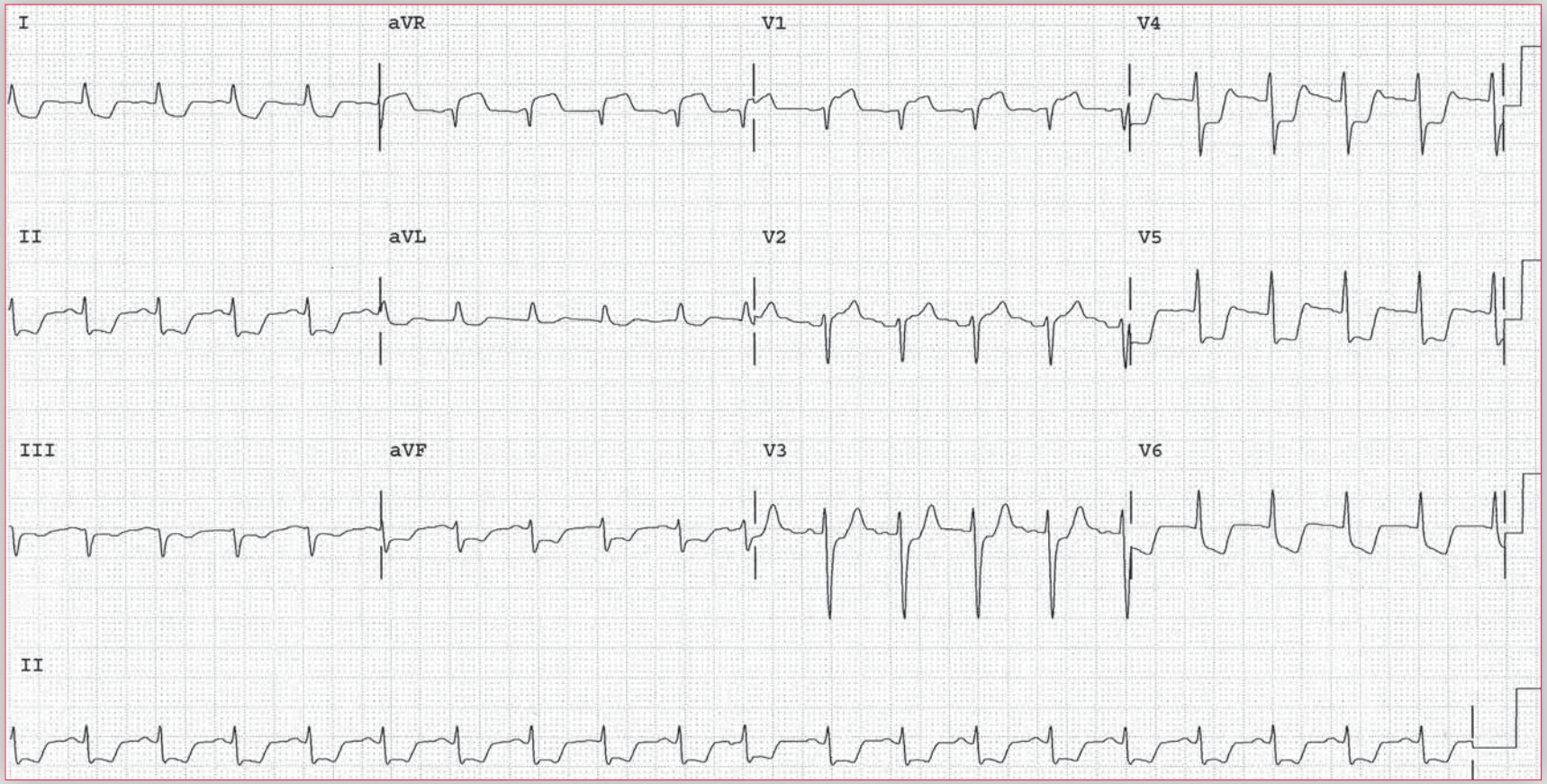

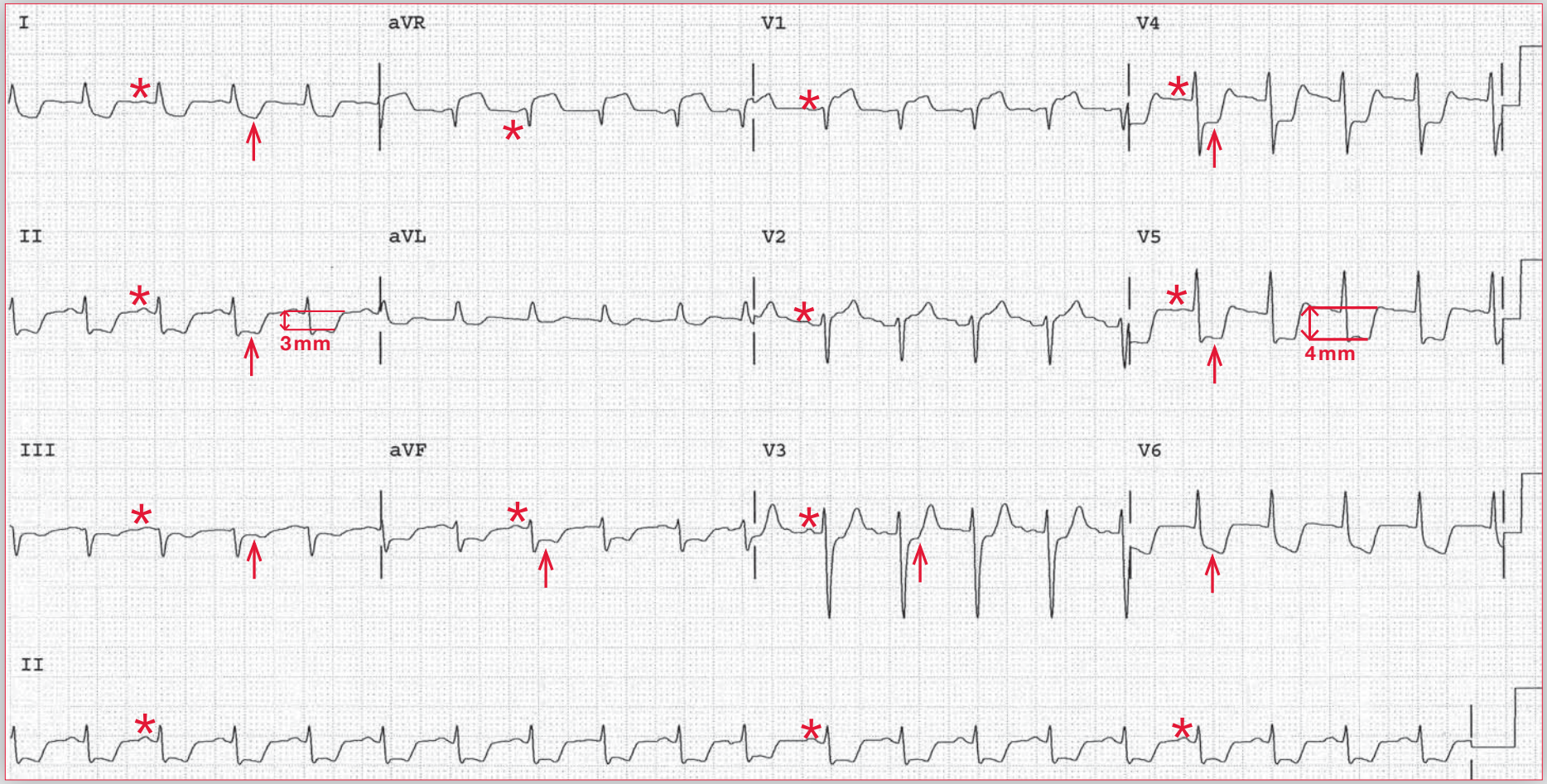

ECG 19 Analysis: Sinus tachycardia, low voltage, horizontal ST-segment depression

The ECG shows a regular rhythm at a rate of 120 bpm. There is a P wave (*) before each QRS complex, with a stable PR interval (0.14 sec). The P wave is upright in leads I, II, aVF, and V4-V6, and the P-wave morphology is normal. This is sinus tachycardia.

The QRS complex duration is normal (0.08 sec), and the axis is slightly leftward, between 0° and –30° (positive QRS complex in leads I and II and slightly negative QRS complex in lead aVF). The QRS morphology is normal, and there is normal R-wave progression from lead V1 to lead V6. However, the QRS amplitude in the limb leads is low (defined as a QRS complex amplitude ≤ 5 mm in each limb lead). The QT/QTc intervals are normal (260/370 msec). Diffuse J-point and ST-segment depression (↑) can be seen in almost all leads. The ST segments are 3 to 4 mm below the baseline (TP segment) (↕) and are horizontal, except in leads I and V6, where the ST-segment depression is downsloping. Horizontal ST-segment depression is more specific for ischemia than upsloping ST-segment depression. Although the leads in which ST-segment depression is seen do not necessarily correlate with the location of ischemia, the finding of widespread ST-segment depression does correlate with significant, probably multivessel coronary artery disease. The degree of ST-segment depression (*ie*, number of millimeters depressed) also correlates with the severity of the coronary disease.

This patient likely has multivessel coronary disease. Although her chest discomfort is atypical for ischemia, she is both diabetic and female. In both of these situations ischemic chest discomfort may present with atypical features. Therefore, additional anti-ischemic therapy should be initiated (*ie*, a long-acting nitrate and increased dose of β-blocker to further reduce her heart rate with activity). If symptoms persist, further delineation of the coronary anatomy is warranted. This is usually accomplished with diagnostic coronary angiography. If multivessel disease is confirmed, this patient will likely require revascularization, either with a percutaneous intervention or coronary artery bypass graft surgery. In most cases, symptomatic ischemia in the presence of diabetes mellitus and multivessel disease, particularly involving the left main or left anterior descending artery, is an indication for surgical revascularization. ■

Core Case 20

An 81-year-old woman is admitted with fever, hypotension, and bacteremia. She is found to have *Escherichia coli* sepsis with a likely urinary

ECG 20A

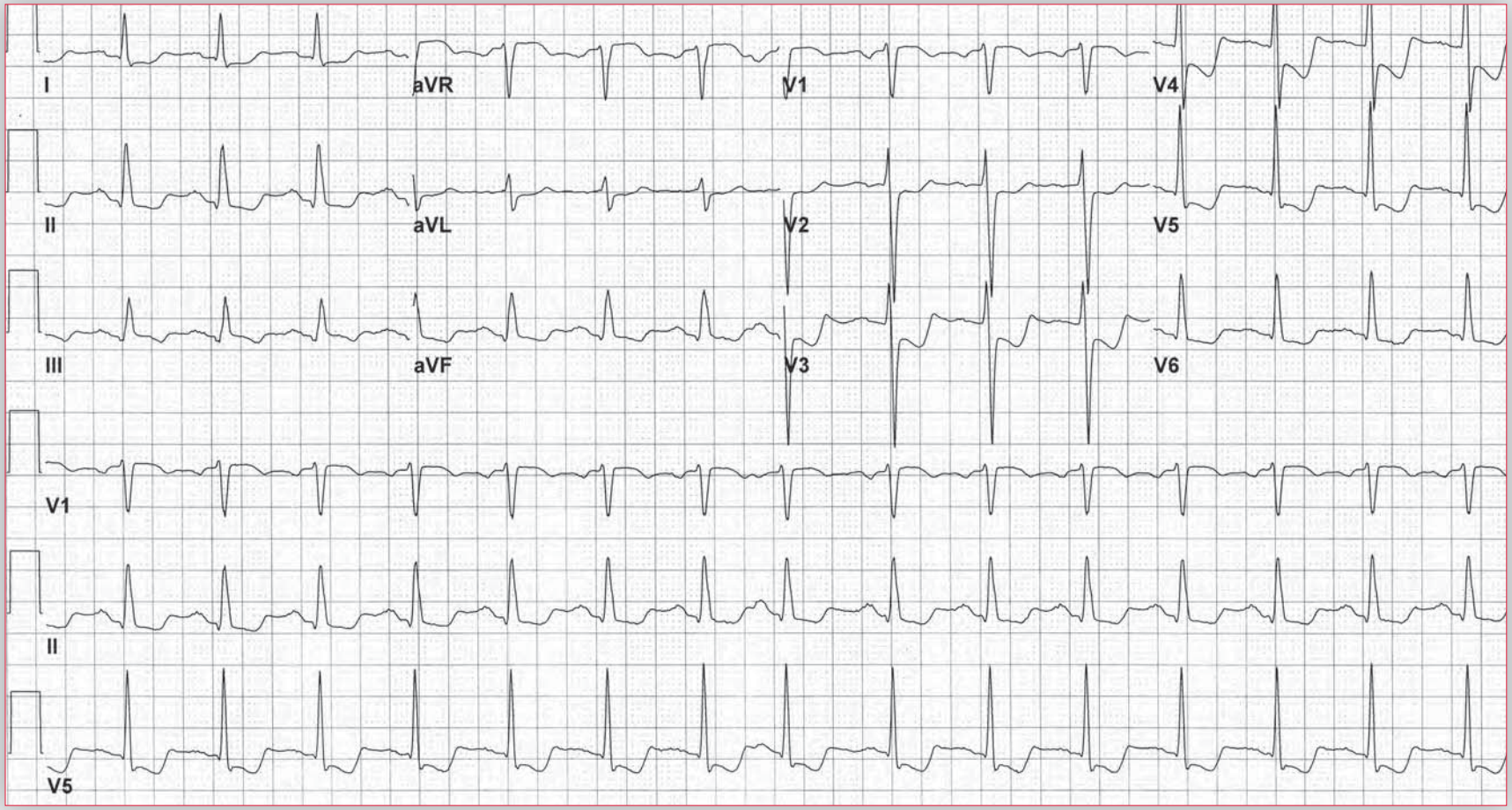

tract source and is admitted to the intensive care unit for antibiotics and fluids. An ECG (20A) is obtained and compared with her baseline ECG (20B).

What does ECG 20A show?
What the likely diagnosis?
What therapy is appropriate?

ECG 20B

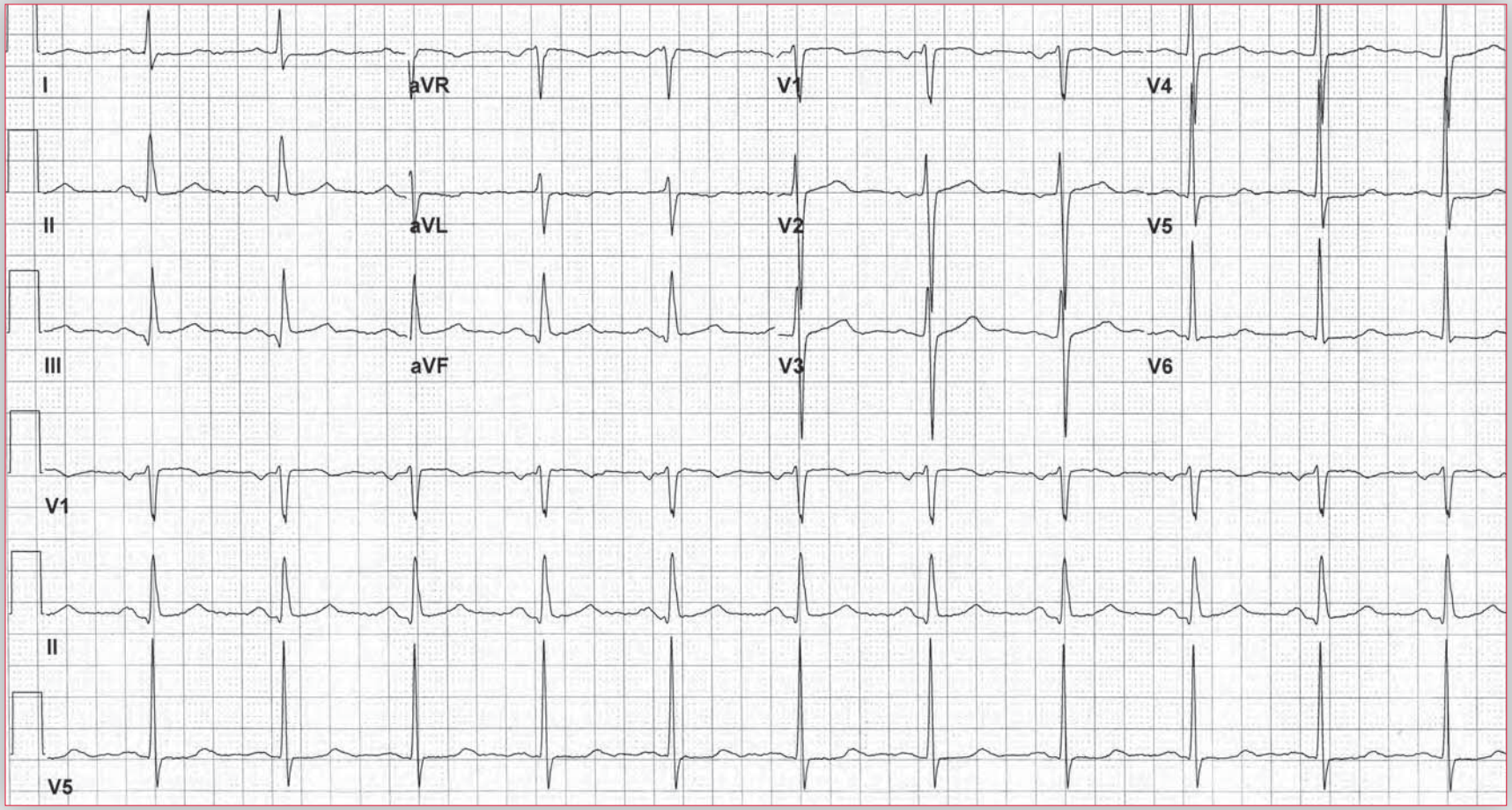

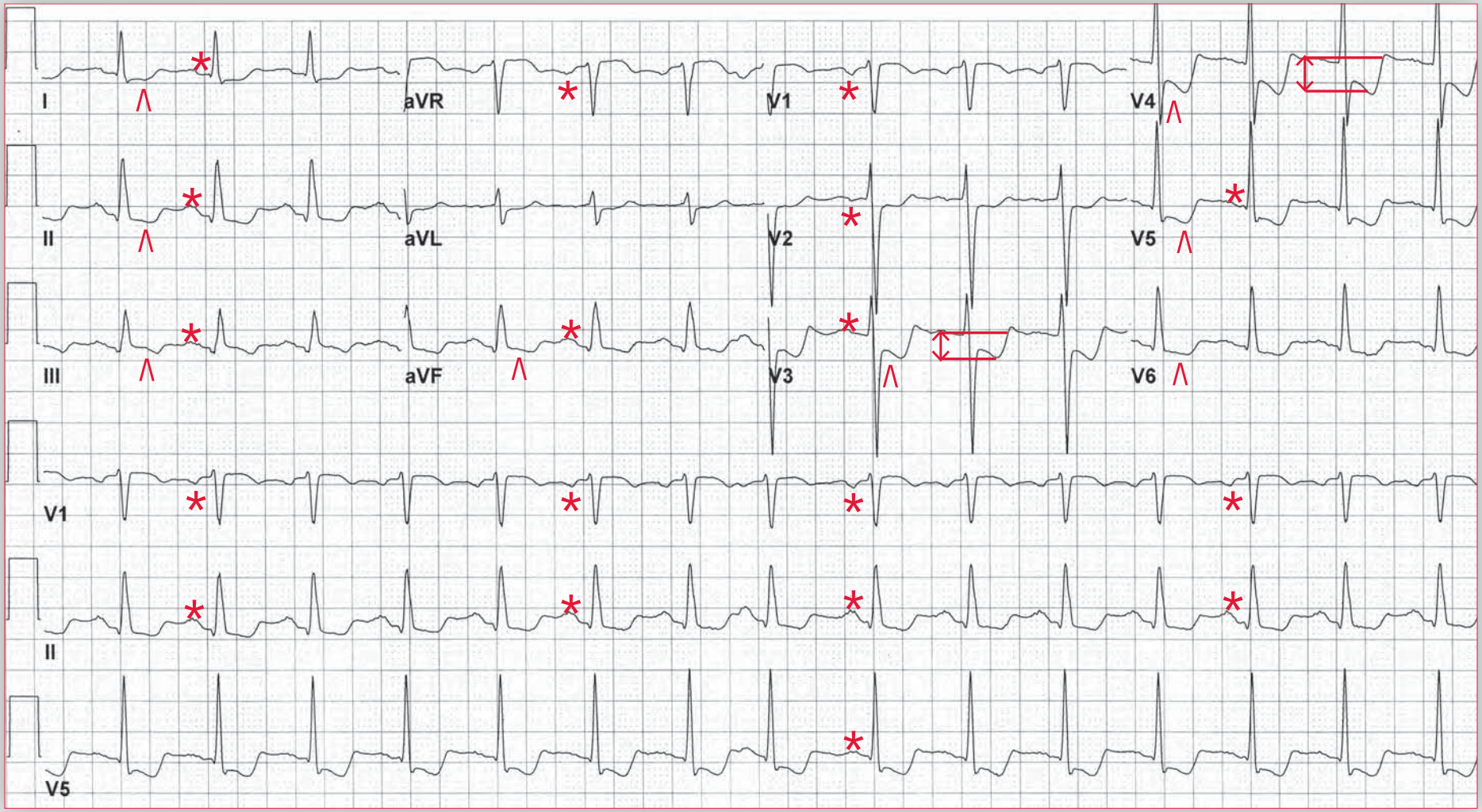

ECG 20A Analysis: Normal sinus rhythm, downsloping ST-segment depression

In **ECG 20A**, there is a regular rhythm at a rate of 92 bpm. There is a P wave (*) before each QRS complex, with a stable PR interval (0.18 sec). The P wave is positive in leads I, II, aVF, and V4-V6 and negative in lead aVR. The P-wave morphology is normal. This is a normal sinus rhythm.

The QRS complex duration is normal (0.10 sec), and the morphology is normal with normal R-wave progression in leads V1 to V6. The QRS axis is normal, between 0° and +90° (positive QRS complex in leads I and aVF). The QT/QTc intervals are normal (340/420 msec). There are small Q waves in leads II, III, and aVF. They are not deep or wide (0.04 sec). These are septal Q waves.

There is prominent J-point and ST-segment depression (^) in leads I, II, aVF, and V3-V6. The ST-segment depression is downsloping, especially in leads V3-V6, and is 2 to 4 mm below the baseline (↕) (TP segment). Downsloping ST-segment depression is the type of ST-segment change that is most predictive of significant coronary artery disease. The number of leads showing ST-segment depression and the depth of the depression are predictive of multivessel disease.

continues

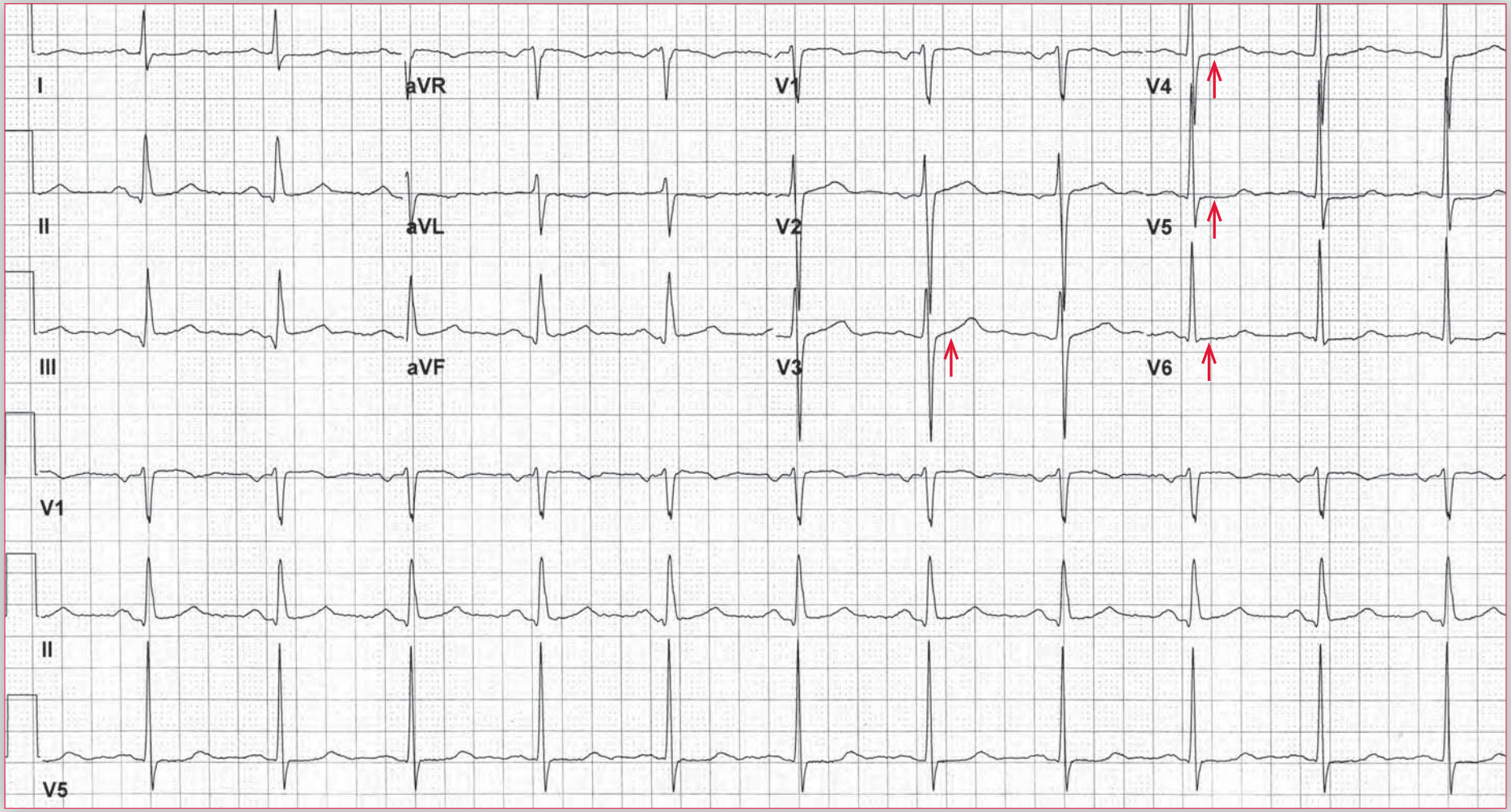

ECG 20B Analysis: Normal

ECG 20B is the patient's baseline ECG. The P waves, PR interval, QRS complex, T waves, and QT interval are normal and are the same as in **ECG 20A**. However, there is no J-point or ST-segment depression present (↑).

These ECGs demonstrate evidence of myocardial ischemia in the setting of the hemodynamic stress of bacteremia and sepsis. Though rate-related ST-segment changes are common and can be nonspecific, these downsloping ST-segment depressions are likely to indicate subendocardial ischemia. It is not uncommon for patients to suffer myocardial ischemia or small elevations of cardiac biomarkers in the setting of this kind of hemodynamic perturbation. This is termed demand ischemia (also called a type II myocardial infarction) and has a different pathophysiology than a non–ST-segment elevation myocardial infarction (NSTEMI) (also called a type I myocardial infarction), which is due to acute plaque rupture and intracoronary thrombosis. In most cases of NSTEMI, patients have symptoms of myocardial ischemia associated with the ECG changes and elevated biomarkers. Therapy for demand ischemia should be focused on restoring normal hemodynamics, including volume resuscitation, treatment of the underlying infection, and support of the blood pressure with vasoactive agents. Antithrombotic medications are not indicated in this clinical scenario as this is not a type I NSTEMI. ■

Core Case 21

A 55-year-old woman presents to the emergency department for evaluation of chest discomfort. She notes typical angina occurring with activity two to three times per week, most recently about 30 minutes prior to presentation. She has risk factors including hypertension and a strong family history of coronary artery disease.

ECG 21A

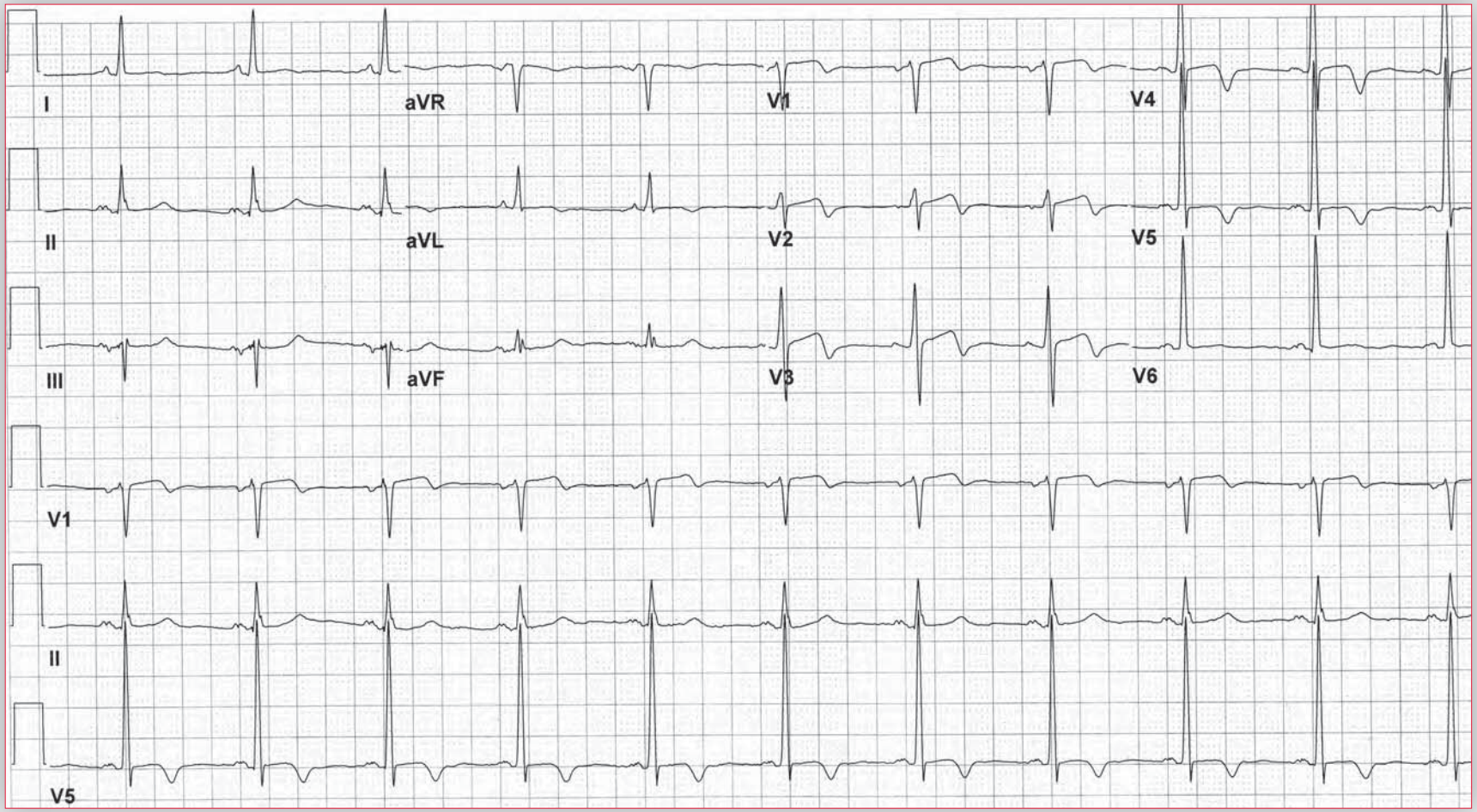

Her presenting ECG is shown (21A). She undergoes an exercise stress test, during which she exercises for 7 minutes 24 seconds with no chest pain. One minute into recovery, she develops severe retrosternal chest discomfort associated with nausea and diaphoresis. A second ECG is obtained (21B).

What do these ECGs show?

What is the likely diagnosis?

ECG 21B

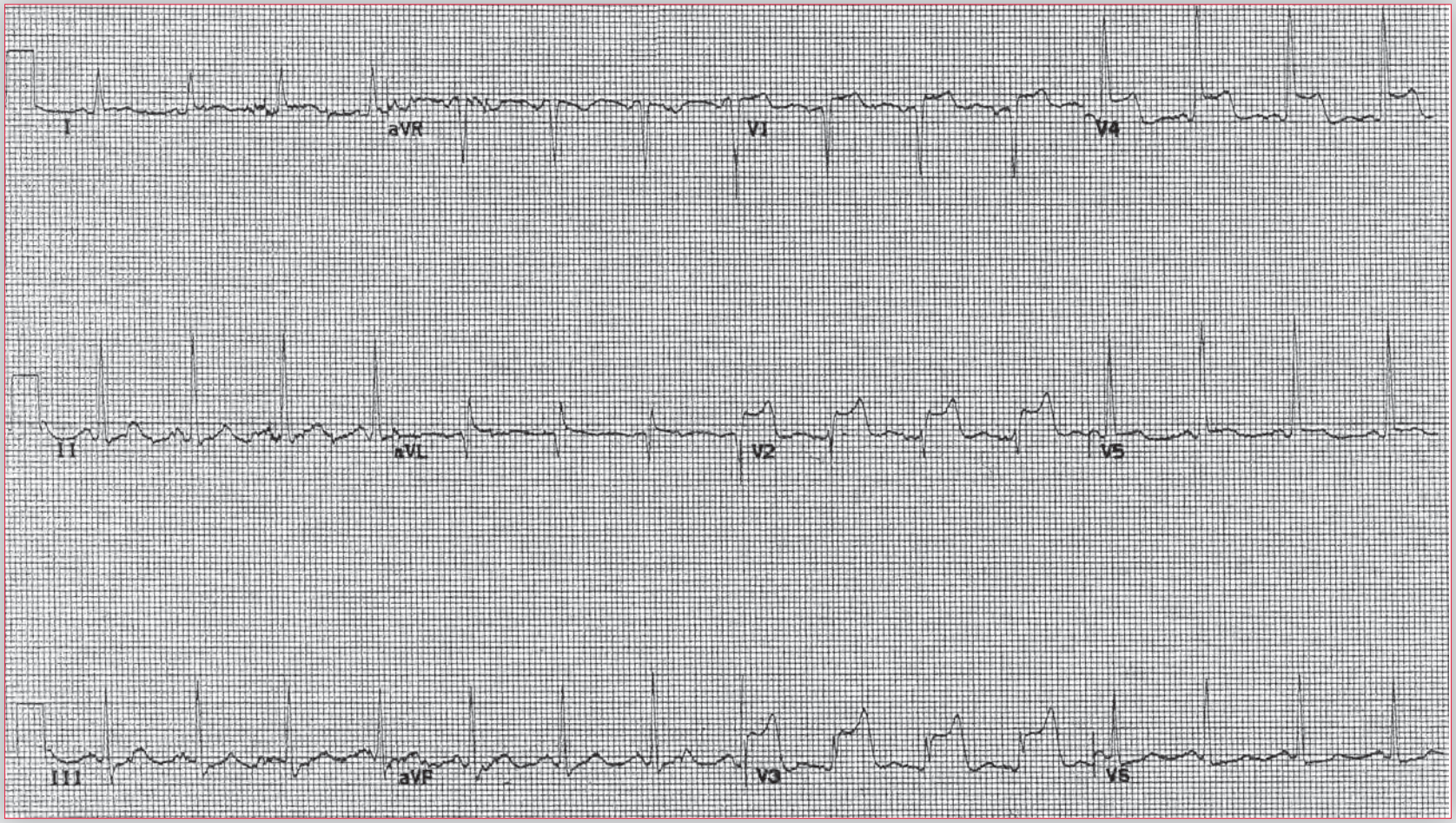

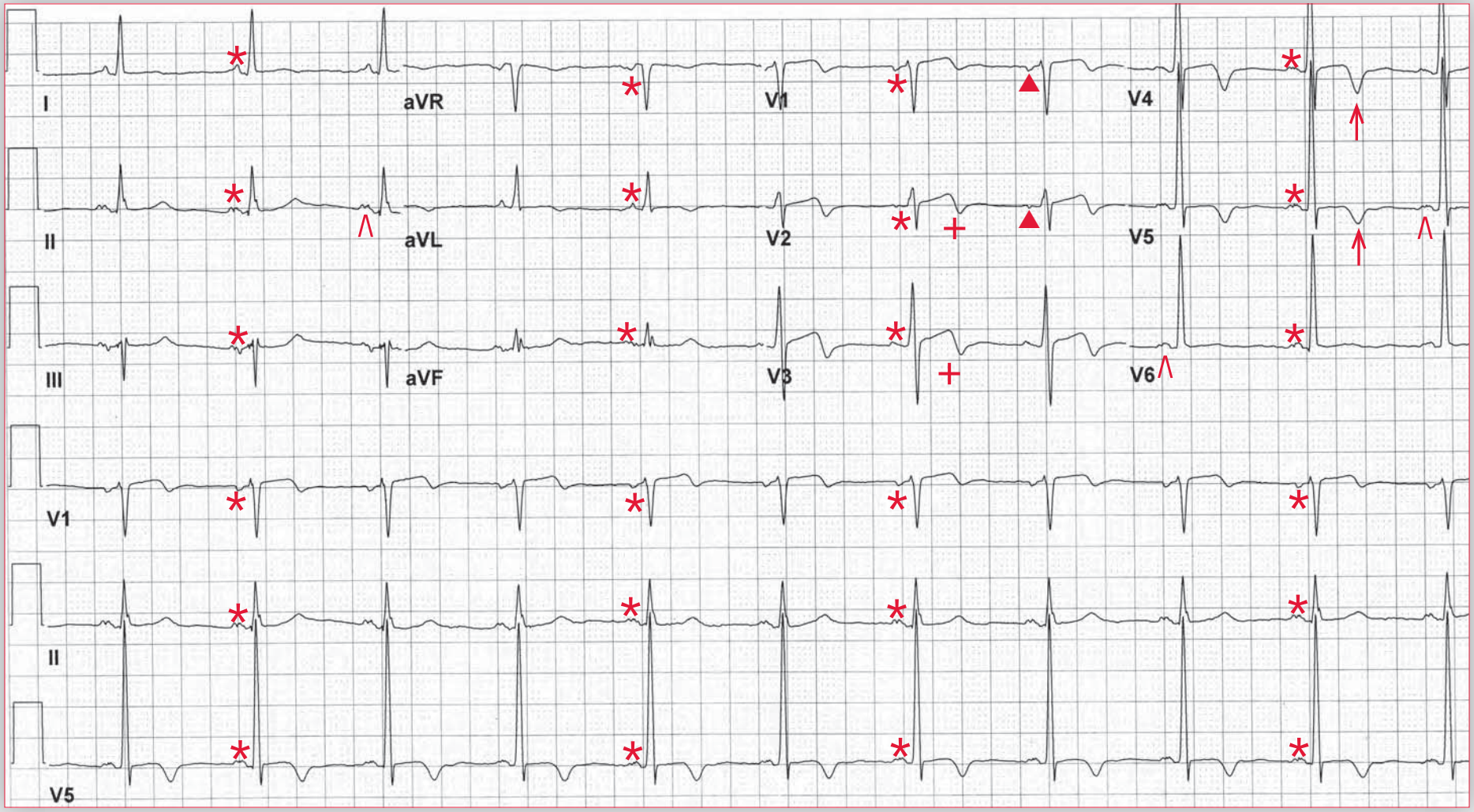

ECG 21A Analysis: Normal sinus rhythm, left atrial hypertrophy (abnormality), nonspecific ST-T wave abnormalities

The baseline **ECG** (**21A**) shows a regular rhythm at a rate of 66 bpm. There is a P wave (*) before each QRS complex, with a stable PR interval (0.14 sec). The P waves are upright in leads II, III, aVF, and V4-V6 and negative in lead aVR. This is a normal sinus rhythm. The P waves are prominently notched in leads II and V5-V6 (^) and are primarily negative in leads V1-V2 (▲). This is consistent with left atrial hypertrophy or a left atrial abnormality.

The QRS complex duration is normal (0.08 sec), with a normal morphology and axis, between 0° and +90° (positive QRS complex in leads I and aVF). The QT interval is normal (400/420 msec), and the ST segments are normal and at baseline. The T waves are biphasic (+) in leads V2-V3 and negative (↑) in leads V4-V5. Although T-wave inversions are nonspecific, they are meaningful when associated with a clinical story that is characteristic for discomfort due to myocardial ischemia.

Although not completely typical (as the T waves are biphasic in leads V2-V3), the T-wave changes seen in this ECG are suggestive of Wellens' syndrome. Wellens' T waves are deep and symmetrically inverted T waves in leads V2-V4 or V5. This pattern should alert the clinician to a potential high left anterior descending coronary artery (LAD) stenosis. This pattern is frequently overlooked by treating physicians because it is not a typical pattern of ischemia. Nonetheless, this could represent a potentially unstable LAD plaque. If the frequency of angina is increasing or is occurring at rest, indicating an unstable pattern, the patient should be evaluated using coronary angiography rather than exercise stress testing. However, if the angina has a stable pattern, exercise testing is reasonable.

continues

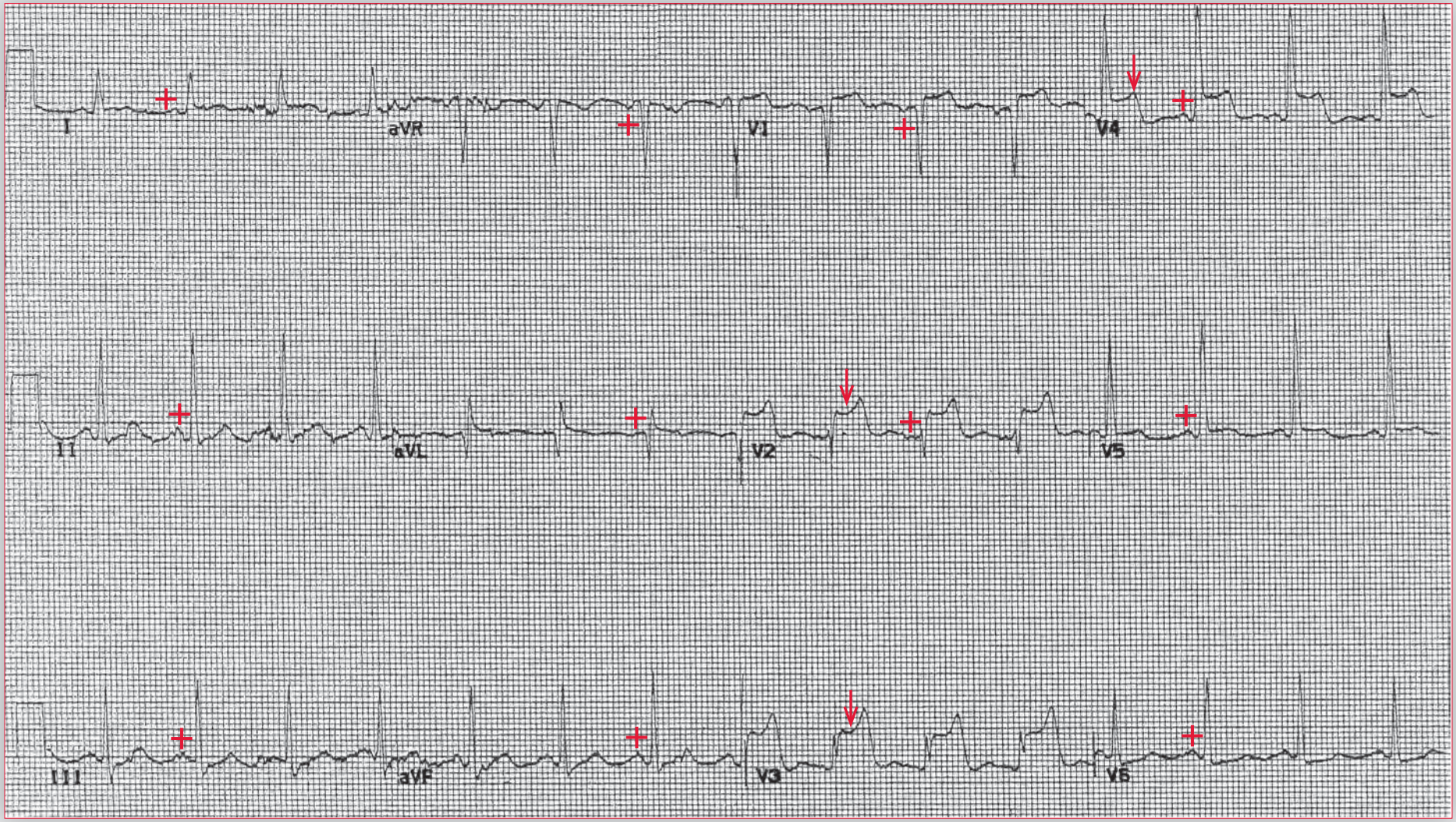

ECG 21B Analysis: Normal sinus rhythm, T-wave inversions suggesting ischemia, exercise-induced ST-segment elevation due to ischemia

ECG 21B was obtained within the first minute of recovery after the stress test. The rhythm is regular at a rate of 94 bpm. The P waves (*), PR interval, QRS complexes, and QT/QTc intervals are the same as in **ECG 21A**. However, there is significant ST-segment elevation (↓) in leads V2-V4. ST-segment elevation occurring in leads that do not have Q waves indicates transmural ischemia. This was provoked by exercise and is associated with a critical, subtotal occlusion of a coronary artery. In this case the ST-segment elevations are indicative of transmural anteroapical ischemia, likely from a proximal to mid-LAD lesion. The provocation of ST-segment elevation during an exercise test is an indication for urgent cardiac catheterization and intervention as appropriate.

In contrast, ST-segment elevation during an exercise test that is seen in leads where there has been a previous infarction, indicated by a Q wave, is associated with the development of a wall motion abnormality. ■

Core Case 22

A 58-year-old man with a prior inferior and anterior wall myocardial infarction presents with sharp chest pain while playing tennis. The pain is reliably reproduced with vigorous activity but has also occurred at rest. The chest pain is sharp and located at the left sternal border. Episodes last about 30 seconds. A baseline ECG (22A) is obtained

ECG 22A

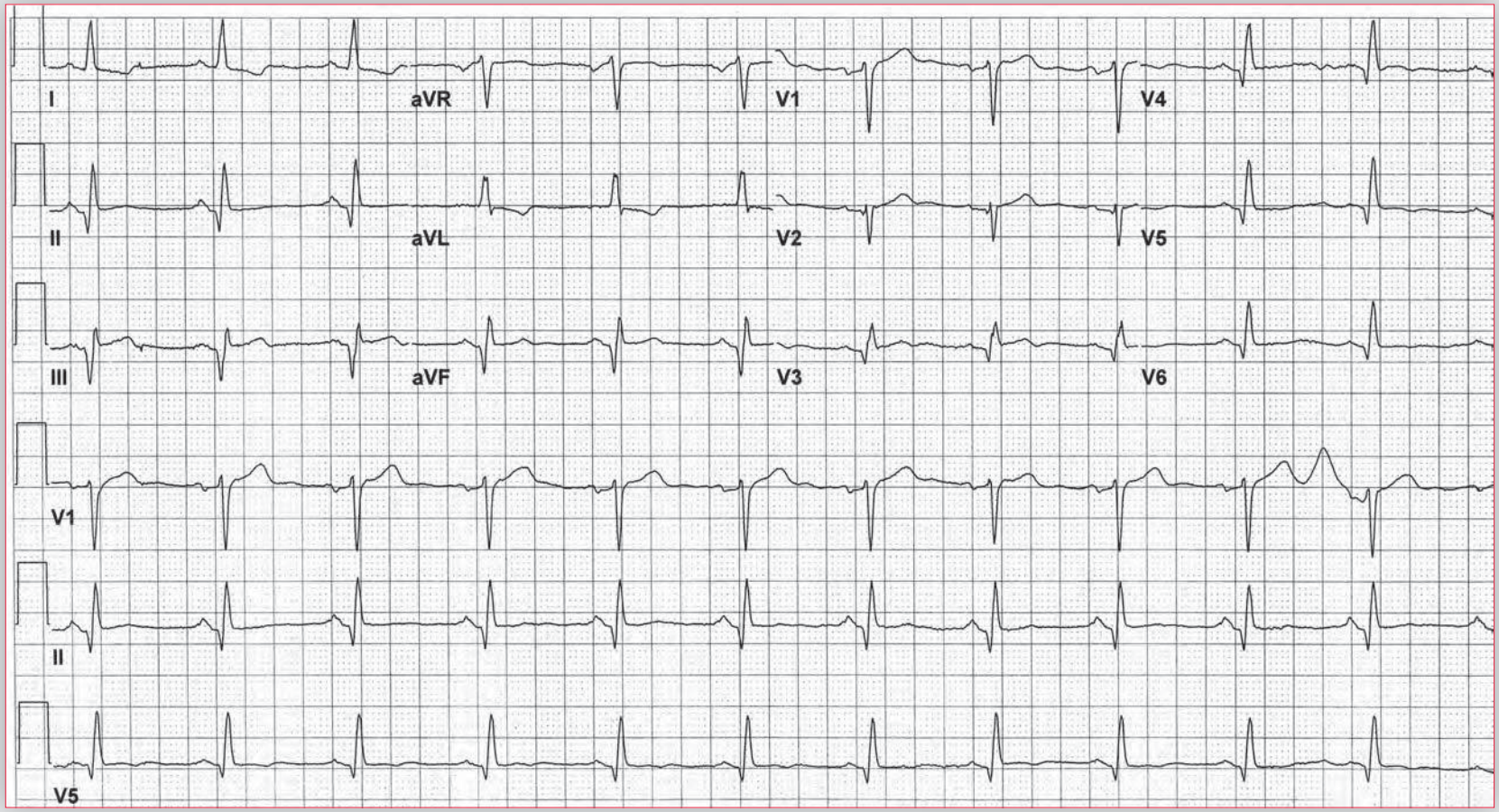

in his primary care physician's office. His physician refers him for an exercise stress test. He exercises for 8 min 14 seconds on a Bruce protocol and stops due to shortness of breath but does not develop chest pain. Within 1 minute of stopping the test, his ECG changes (ECG 22B) and he develops chest pain similar to his presenting pain.

What do these ECGs show?

What is the likely diagnosis?

ECG 22B

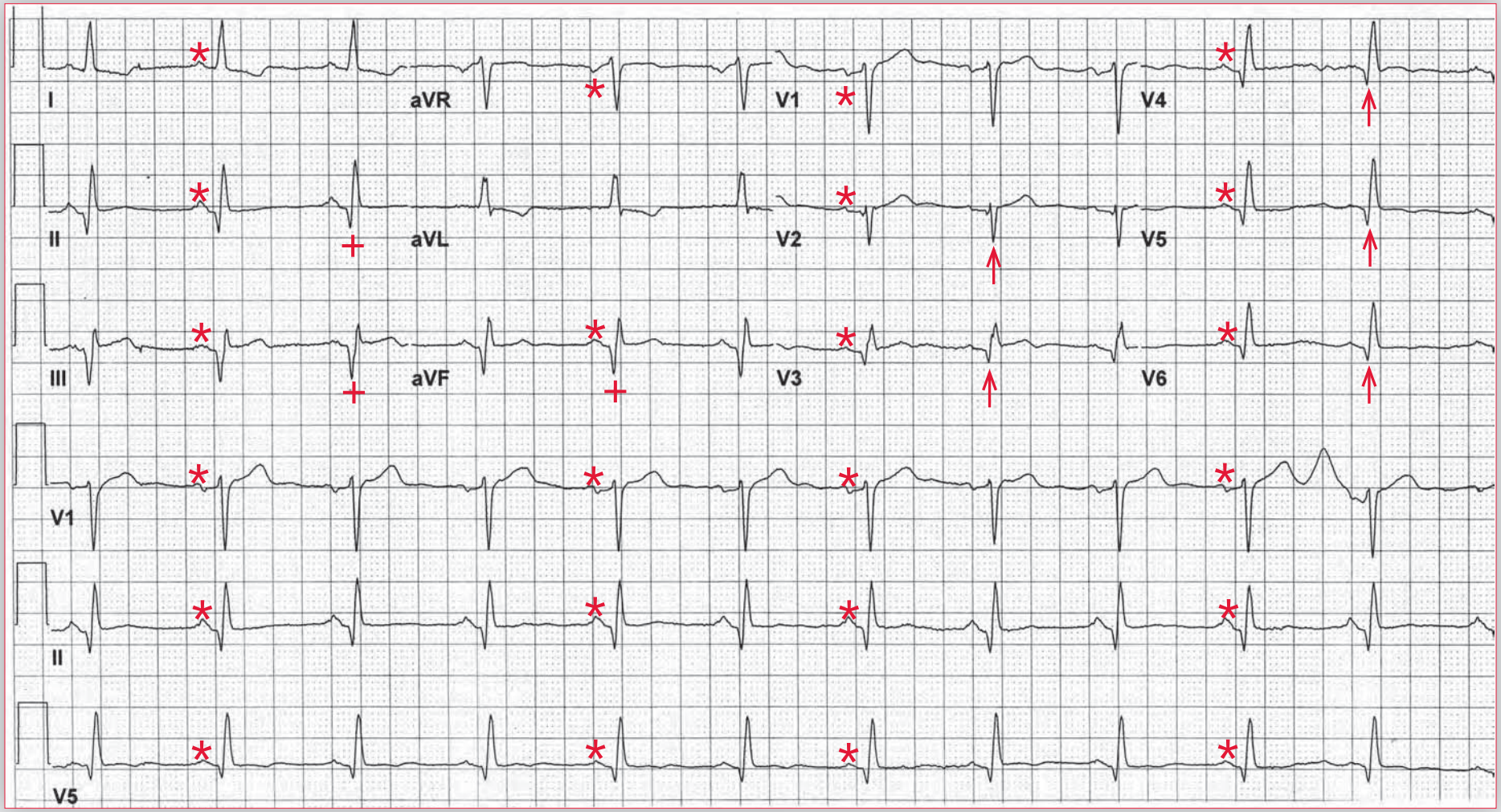

ECG 22A Analysis: Normal sinus rhythm, intraventricular conduction delay, old inferior wall myocardial infarction (MI), old anteroapical and anterolateral wall MI

ECG 22A shows a regular rhythm at a rate of 68 bpm. There is a P wave (*) before each QRS complex, with a stable PR interval (0.16 sec). The P waves have a normal morphology and are upright in leads II, III, aVF, and V4-V6 and negative in lead aVR. This is a normal sinus rhythm.

The QRS complex duration is increased (0.12 sec). There is no specific morphology indicative of a bundle branch block; hence this is an intraventricular conduction delay. There are significant Q waves (+) in leads II, III, and aVF, indicative of a previous inferior myocardial infarction (MI). There is also a small but significant Q wave (↑) in lead V2 as well as Q waves (↑) in leads V3-V6, indicative of an anteroapical and anterolateral MI. The QRS axis appears to be about 0° (positive QRS complex in lead I and biphasic QRS complex in lead aVF). However, the biphasic QRS complex in lead aVF is the result of a deep Q wave that is the result of an MI. If this is not considered, the axis is normal, between 0° and +90°. The QT/QTc intervals are normal (360/380 msec and 320/340 msec when corrected for the prolonged QRS complex duration).

This baseline ECG is consistent with an old inferior and anteroapical and anterolateral MI. There is no evidence of active ischemia by ECG, but the patient's recent exertional chest pain is suspicious for residual ischemia (although it is not typical for myocardial ischemia). Since the symptoms occur primarily with exertion, a stress test is indicated.

continues

ECG 22B Analysis: Exercise-induced ST-segment elevation due to wall motion abnormality

ECG 22B was recorded immediately upon the termination of exercise, within the first minute of recovery. The rate is 150 bpm. The P wave (*); PR interval; QT/QTc intervals; and QRS complex duration, axis, and morphology are the same as in **ECG 22A**. However, ST-segment elevation (↓) is noted in leads II, III, aVF, and V3-V6. These ST-segment changes are seen in the same leads in which there are Q waves (^), which are indicative of a previous MI. Hence these ST-segment changes are the result of the development of an exercise-induced wall motion abnormality in the area of a previous MI. In this situation they are not the result of transmural ischemia as would be the case if the ST-segment elevation occurred in leads without Q waves. However, there is 1 mm horizontal ST-segment depression in leads I and aVL (↑), which may be indicative of subendocardial ischemia. ■

Notes

A 84-year-old woman is admitted to the hospital following an elective cholecystectomy. She has a history of hypertension and chronic renal insufficiency. Six hours after her surgery, she developed chest tightness and dyspnea. An ECG at the time of her symptoms is shown.

What does her ECG show?

What is the likely diagnosis?

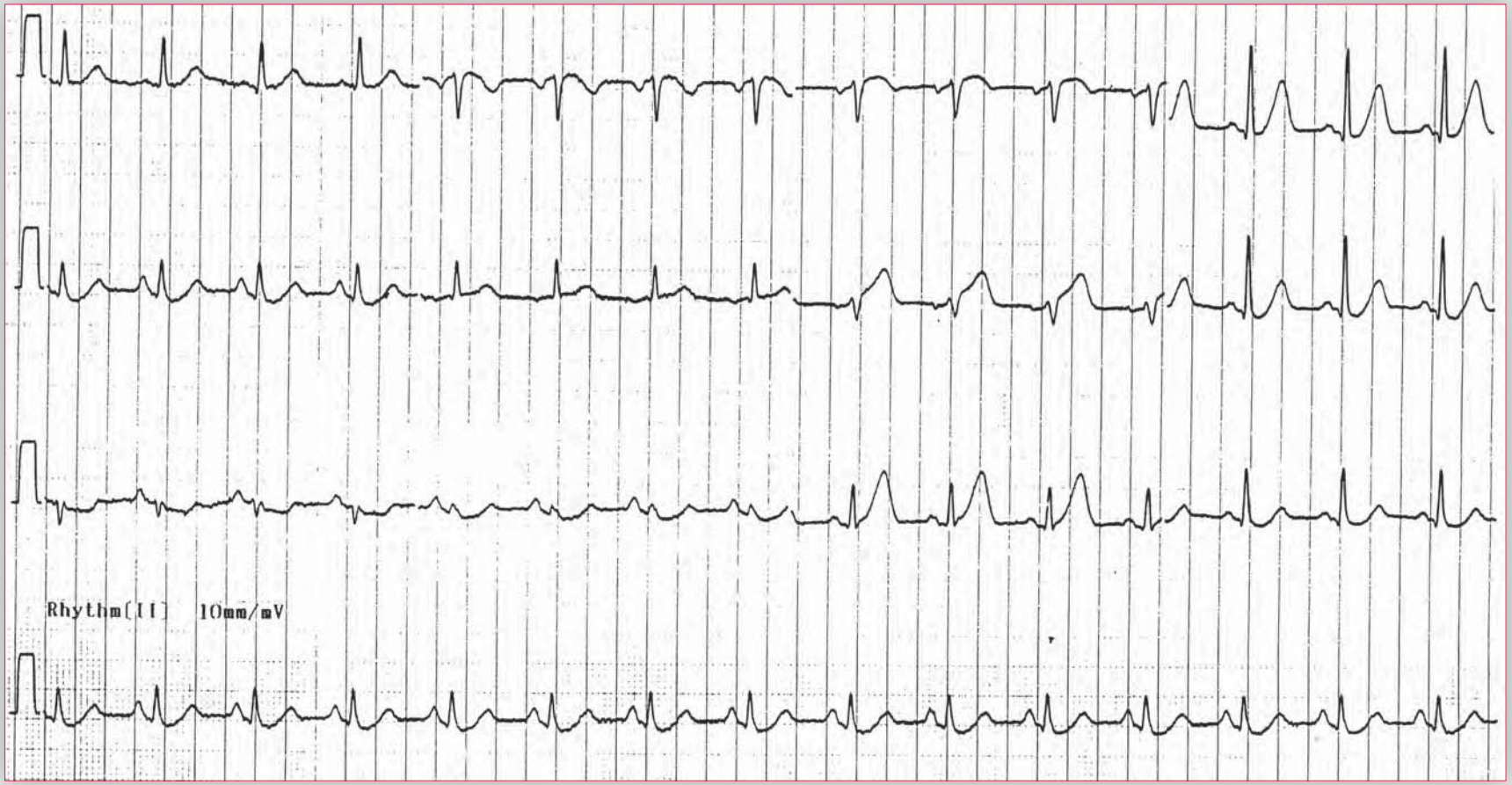

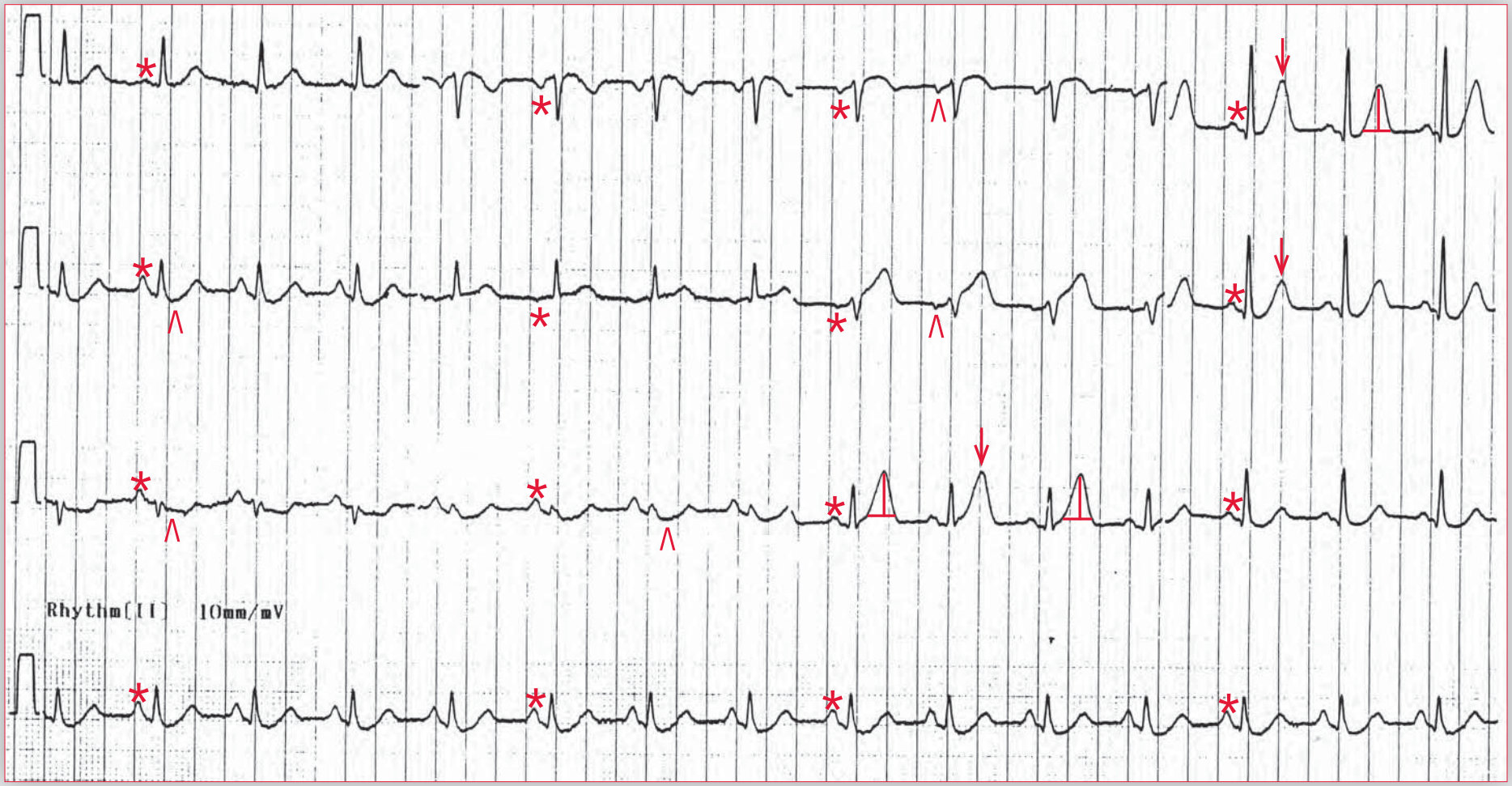

ECG 23 Analysis: Normal sinus rhythm, acute anterior wall myocardial infarction (MI), hyperacute T waves, left atrial hypertrophy

Although the leads are not labeled, the pattern is always the same (column 1 is leads I, II, and III; column 2 is leads aVR, aVL, and aVF; column 3 is leads V1-V3; and column 4 is leads V4-V6). The ECG shows a regular rhythm at a rate of 92 bpm. There is a P wave (*) before each QRS complex, with a stable PR interval (0.16 sec). The P wave is upright in leads I, II, aVF, and V4-V6 and negative in lead aVR. This is a normal sinus rhythm. The P wave is negative in leads V1-V2 (^), indicating left atrial hypertrophy or left atrial abnormality.

The QRS complex duration is normal (0.08 sec), and there is a normal morphology and axis, between 0° and +90° (positive QRS complex in leads I and aVF). The QT/QTc intervals are normal (320/400 msec), although there is a broad T wave, and the ST segment seems to be short. The T waves (↓) in leads V3-V5 are tall and symmetric (the T-wave upstroke and downstroke are equal), in contrast to the normal T wave, which is asymmetric (*ie*, the upstroke of the T wave is slower than the downstroke). T waves that are tall, peaked and, most importantly, symmetric are seen with hyperkalemia and they are called hyperacute. Hyperkalemia may be systemic and hence associated with diffusely symmetric T-wave changes, or it may be localized, as occurs with an acute myocardial infarction (MI). Therefore, the hyperacute T waves, primarily in leads V3-V5, indicate an acute anteroapical MI. The shortened ST segment is also indicative of an acute MI. There are minimal ST-segment elevations in leads V1 and V2 and ST-segment depressions in leads II, III, and aVF (^), which are reciprocal changes. Reciprocal changes are the same ST-segment changes seen from another angle.

An acute infarction is the result of total cessation of blood flow and oxygen supply. This causes loss of the normal energy (oxygen)-dependent sodium–potassium–ATPase pump and therefore loss of membrane integrity. As a result, potassium leaks out of the cell, based on its electrochemical gradient (normally intracellular potassium levels are higher than extracellular levels because of this ATPase pump). As there is no blood flow into or out of the infarcted tissue, the potassium remains in this area, producing local hyperkalemia. There is also an inward "leak" of calcium and the development of intracellular hypercalcemia, probably accounting for the shortening of the QT interval.

The earliest change with a transmural infarction is hyperacute (symmetric) T waves seen in the area of the involved myocardium. This is due to the localized hyperkalemia that develops and is seen even before there are any ST-segment changes. Thereafter, the ST segment begins to elevate, maintaining its normal concave morphology; hyperacute T waves are still present. ST segments continue to elevate and then become convex, merging with T waves. The amplitude of the R wave decreases. When the ST segment and T waves merge and the R wave is no longer obvious, the complex has the morphology that is called a "current of injury." It resembles the fast action potential. The ST segment begins to return to baseline, Q waves develop, and T waves begin to invert, resulting in a chronic infarct pattern (*ie*, Q-wave and T-wave inversion). Persistent ST-segment elevation, present weeks to years after an acute event, indicates the presence of an aneurysm in the area of the previous infarction.

continues

The location of these changes identifies the region of myocardium involved:

- Inferior wall MI: ST-segment elevation in leads II, III, and aVF. The right ventricle is often involved in an inferior wall MI; this is suggested by the presence of ST-segment elevation in lead V1 and ST-segment depression in lead aVR (which actually represents ST-segment elevation) and is confirmed by obtaining right-sided leads, which will show ST-segment elevation in leads V3R-V4R. There may also be involvement of the posterior wall, which is suggested by the presence of ST-segment depression in leads V1-V2. Posterior leads placed on the back below the left scapula (V7-V8) showing ST-segment elevation help support the diagnosis of a posterior wall MI.
- Anteroseptal MI: ST-segment elevation in leads V1-V2
- Anteroapical MI: ST-segment elevation in leads V3-V4
- Anterolateral MI: ST-segment elevation in leads V5-V6
- Anterior wall MI: ST-segment elevation in two or more contiguous leads across the precordium (*ie*, leads V1-V6)
- Lateral MI: ST-segment elevation in leads I and aVL

The clinical story associated with the ECG changes that indicate an acute transmural or ST-segment elevation myocardial infarction (STEMI) should result in emergent activation of the catheterization laboratory because an acute percutaneous coronary intervention (*ie*, stenting) is indicated. In acute MI, the size of the infarct can be reduced and survival improved with prompt revascularization (*ie*, within 90 minutes of symptom onset). This should be easily achievable for a hospitalized patient, assuming there is recognition that the hyperacute T wave indicates an acute infarction. ■

A 72-year-old man with hypertension and dyslipidemia is admitted with an inferior wall myocardial infarction (MI). He undergoes urgent percutaneous coronary intervention and placement of a bare metal stent in a dominant mid–right coronary artery.

The initial changes on the ECG resolve. Twelve hours after his intervention, he develops recurrent chest discomfort and diaphoresis, resembling the symptoms associated with the MI. An ECG is obtained immediately.

What does his ECG show?

What is the likely diagnosis?

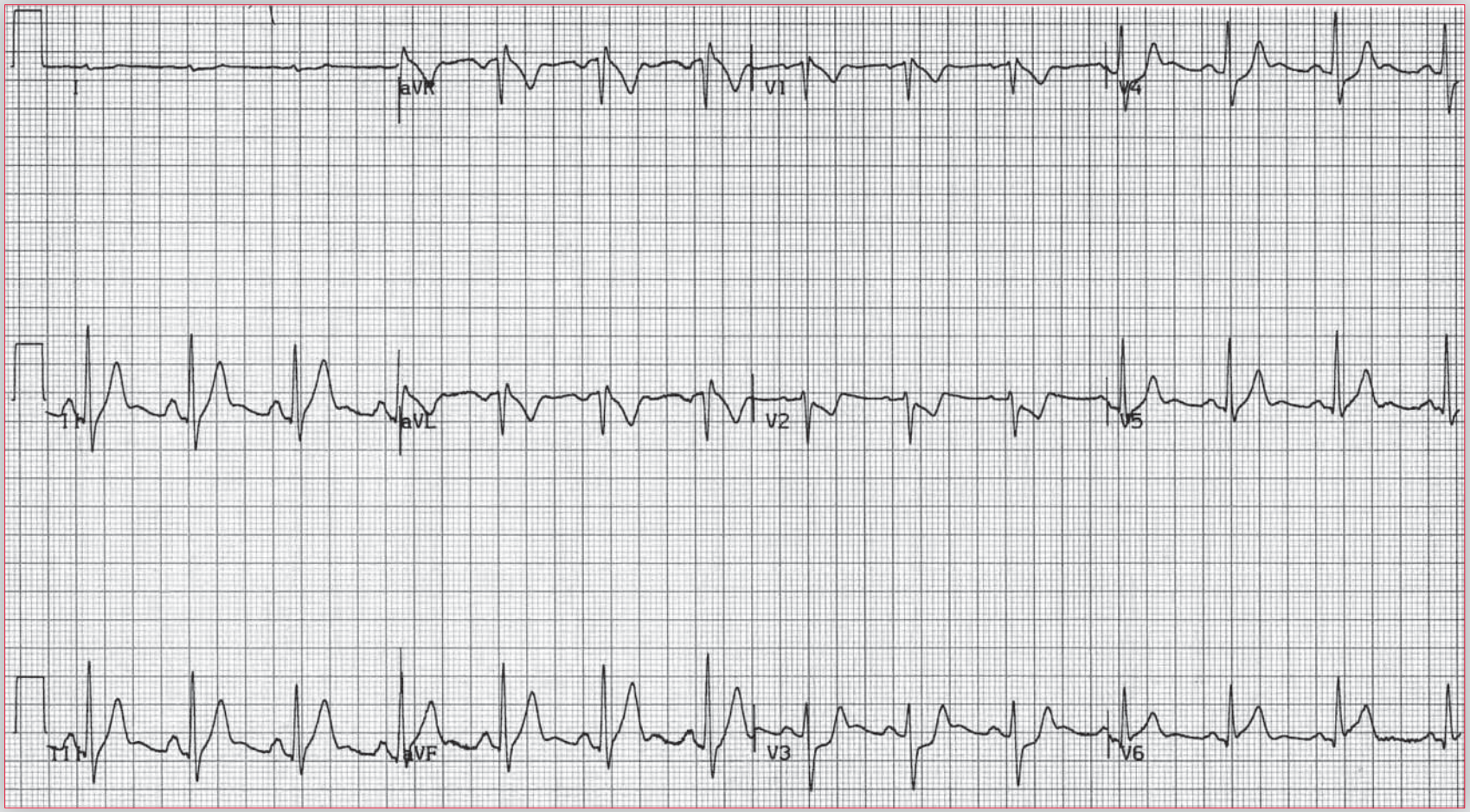

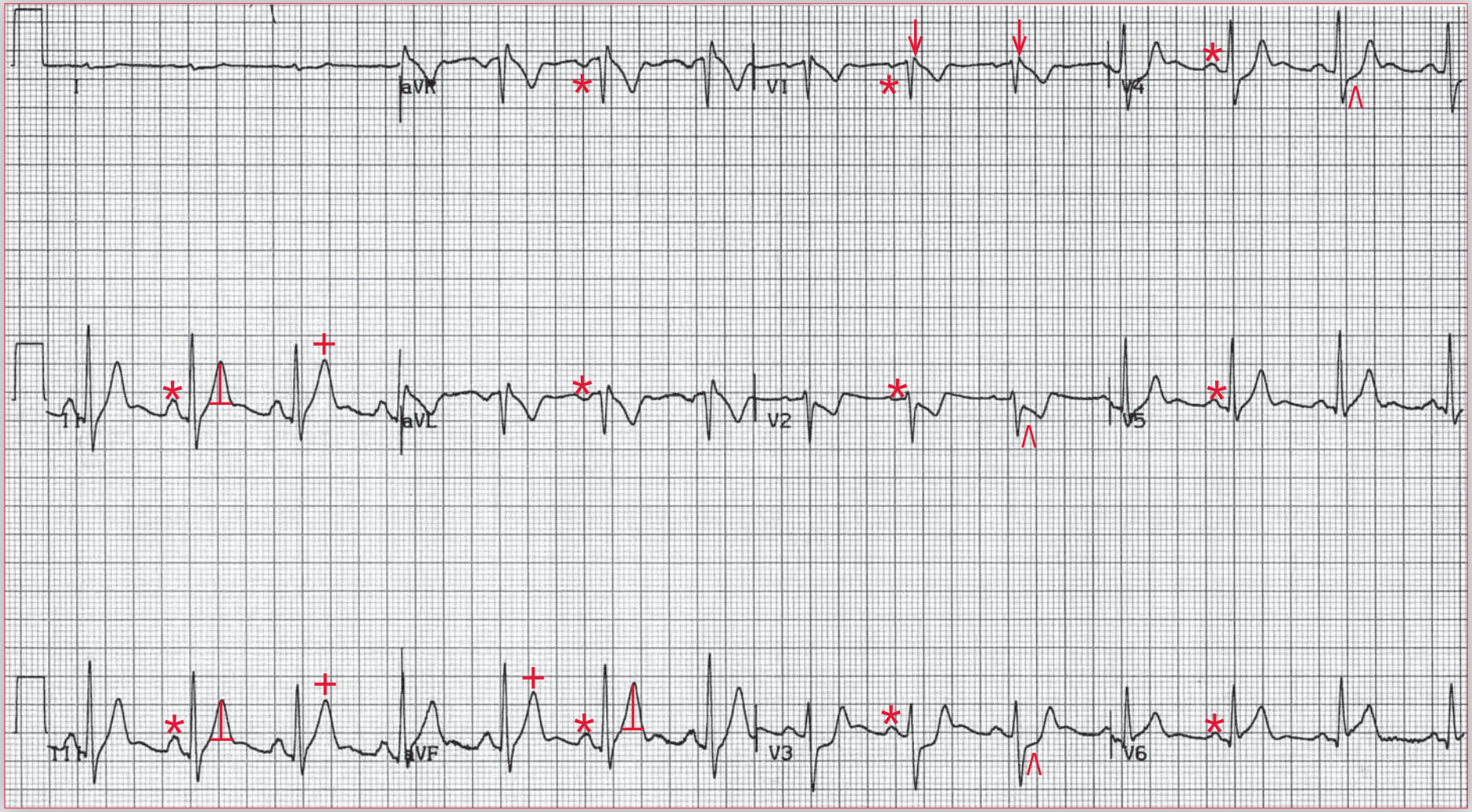

ECG 24 Analysis: Normal sinus rhythm, acute inferior wall MI, hyperacute T waves

There is a regular rhythm at a rate of 84 bpm. There is a P wave (*) in front of each QRS complex, with a stable PR interval (0.18 sec). The P wave is upright in leads I, II, aVF, and V4-V6 and negative in lead aVR. The P-wave morphology is normal. This is a normal sinus rhythm.

The QRS complex duration is normal (0.08 sec), and there is a small R′ in lead V1 (↓), indicating delayed activation of the right ventricle. The axis is normal, between 0° and +90° (positive QRS complex in leads I and aVF). The QT/QTc intervals are short (280/330 msec) as a result of a short ST segment.

The T waves (+) in leads II, III, and aVF are tall and hyperacute (T-wave upstroke and downstroke are equal) in contrast to the normal T wave, which is asymmetric (*ie*, the upstroke of the T wave is slower than the downstroke). T waves that are tall, peaked and, most importantly, symmetric (hyperacute) are seen with hyperkalemia. Hyperkalemia may be systemic or localized, as is seen in acute transmural myocardial infarction (MI). Hyperacute T waves are the first abnormality noted in an acute transmural MI as a result of localized hyperkalemia. They occur in the area of myocardium involved and are seen even before there are any ST-segment changes. Hence this is a very early acute inferior wall MI. Also noted are ST-segment depressions in leads V2-V4 (^), which possibly represent involvement of the posterior wall. This can be confirmed by recording from posterior leads placed on the back below the left scapula (leads V7-V8). These ST-segment depressions may also represent reciprocal ST-segment changes (*ie*, the same ST-segment changes [elevations] viewed from another angle or direction). However, the ST segments in leads II, III, and aVF are not yet elevated, so these are probably not reciprocal ST-segment changes.

An acute MI occurring shortly after percutaneous coronary intervention, as seen in this case, is likely related to acute stent thrombosis. Acute stent thrombosis is a rare but life-threatening complication of the use of coronary stents to treat obstructive coronary disease. The risk factors for stent thrombosis include procedural factors (*eg*, stent underdeployment or stent fracture), complicated target lesions (*eg*, bifurcation lesions), local factors (*eg*, poor blood flow, residual thrombus), and hematologic factors (*eg*, hypercoagulable state or incomplete platelet inhibition). Patients require immediate intervention to restore adequate blood flow through the stent. Since acute stent thrombosis is very often caused by a mechanical problem with the stent (such as underdeployment or fracture), intravascular ultrasound can be used to assess the apposition of the stent to the vessel wall and the integrity of the stent struts. Patients should be treated with intensified dual antiplatelet therapy (usually aspirin and double-dose clopidogrel). Although data on long-term outcomes are still being collected, most practitioners will continue dual antiplatelet therapy indefinitely in the absence of contraindications. ■

Notes

A 38-year-old man presents to the emergency department within 30 minutes of developing chest discomfort. The discomfort occurred after using intranasal cocaine and has been unrelenting since its onset.

What does his ECG show?

What is the likely diagnosis?

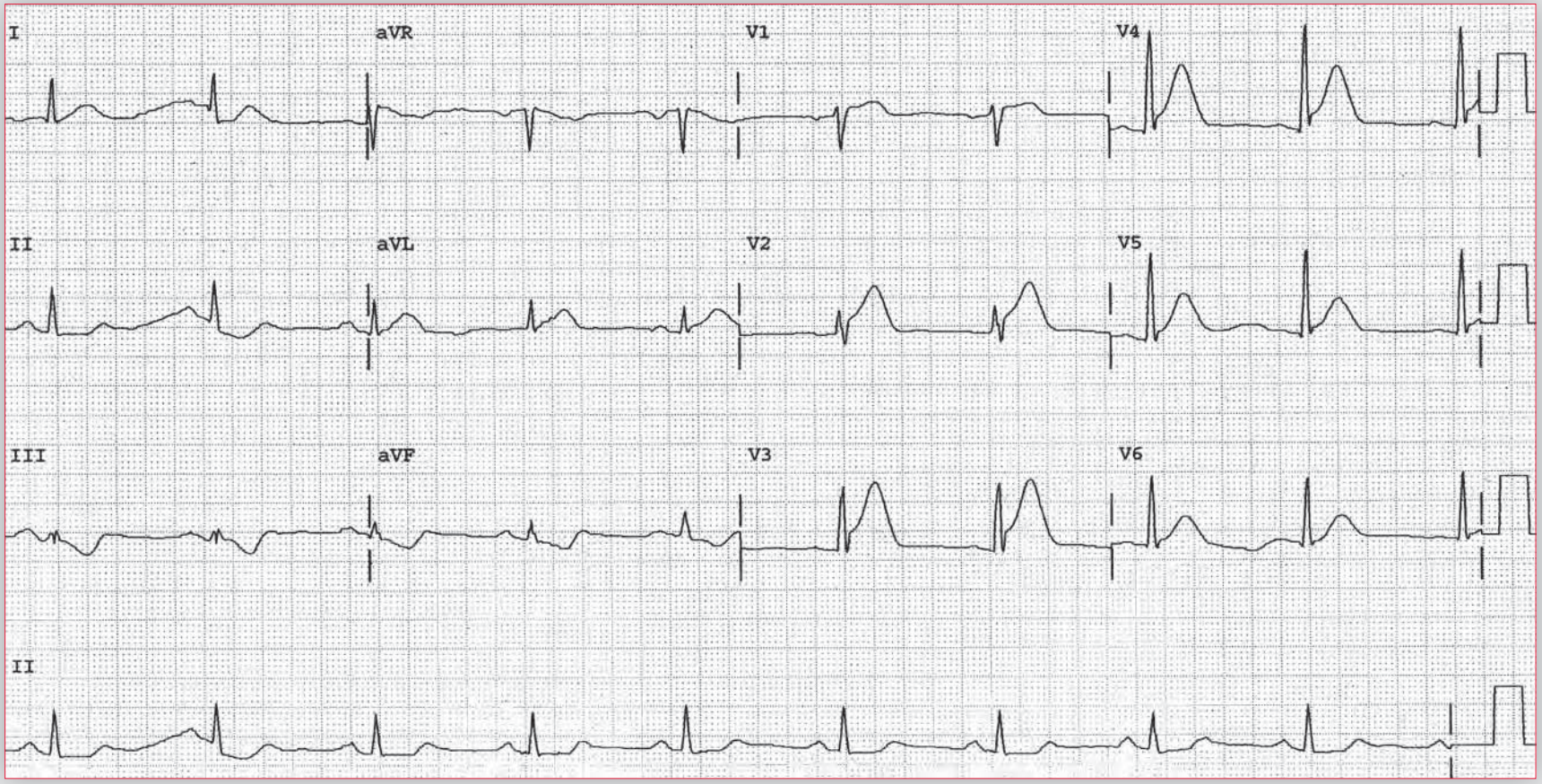

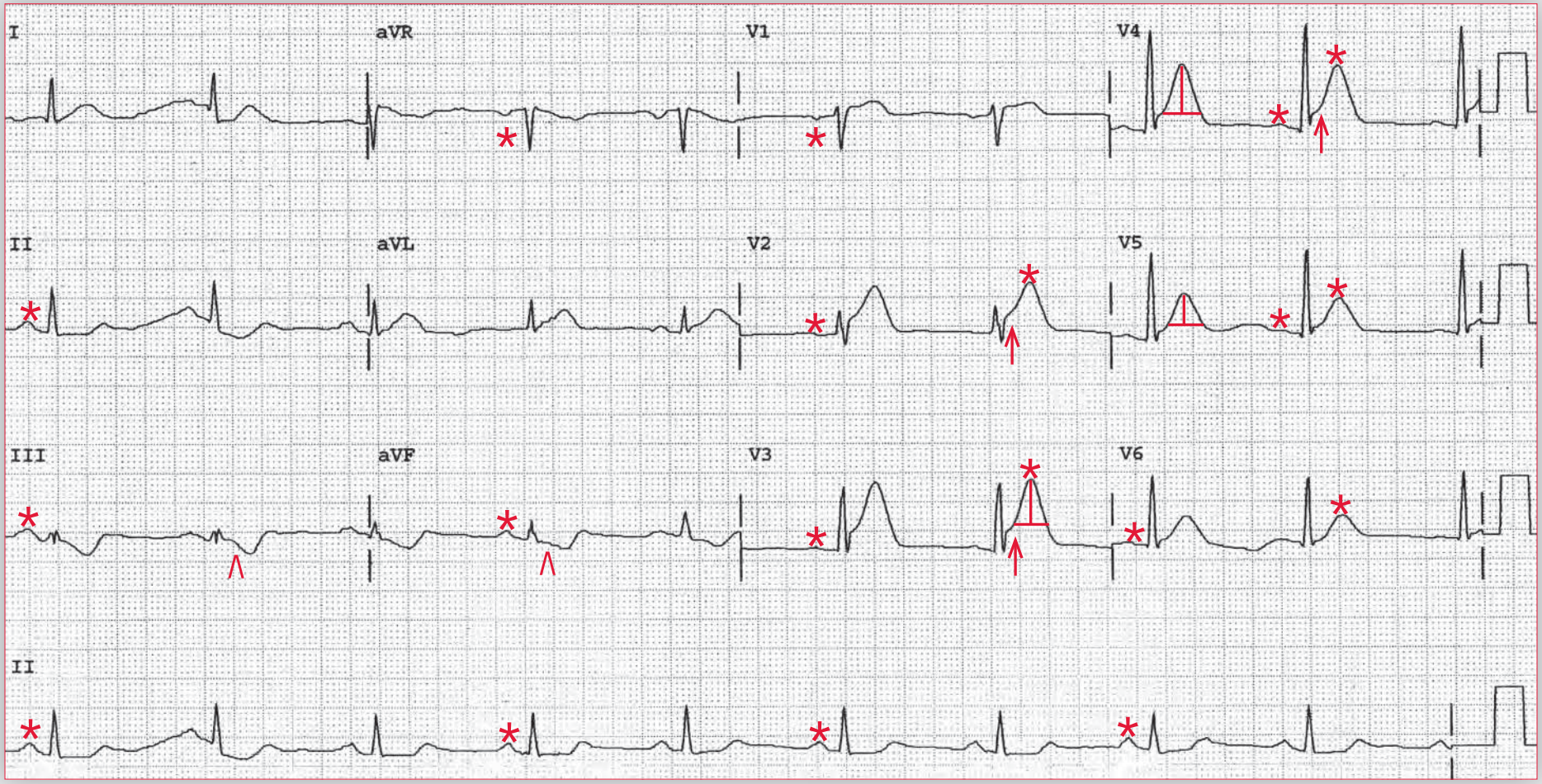

ECG 25 Analysis: Sinus bradycardia, acute anterior wall ST-segment elevation myocardial infarction (STEMI)

There is a regular rhythm at a rate of 56 bpm. There is a P wave (*) before each QRS complex, with a stable PR interval (0.20 sec). The P wave is upright in leads I, II, aVF, and V4-V6 and negative in lead aVR. The P-wave morphology is normal. This is a normal sinus bradycardia.

The QRS complex duration is normal (0.08 sec); there is a normal axis, between 0° and +90° (positive QRS complex in leads I and aVF), and normal morphology. The QT/QTc intervals are normal (400/390 msec). There are tall and symmetric T waves (+) in leads V2-V6. The normal T wave is asymmetric (*ie*, the upstroke is slower than the downstroke). T waves that are tall, peaked and, most importantly, symmetric (hyperacute) are seen with hyperkalemia. Hyperkalemia may be systemic or localized, as is seen in acute transmural myocardial infarction (MI). Hyperacute T waves are the first abnormality noted in an acute transmural MI and are due to localized hyperkalemia. They occur in the area of myocardium involved and are seen even before there are any ST-segment changes. Also noted is ST-segment elevation (↑) in leads V2-V4, and the ST segments are convex. Hence this is an early acute anteroapical ST-segment elevation MI (STEMI). In addition, ST-segment depressions (^) are noted in leads III and aVF; these are reciprocal ST-segment changes that are due to the same ST-segment changes viewed from another angle or direction.

This patient is having acute transmural myocardial ischemia and possibly an acute anterior wall MI, likely resulting from his recent cocaine use. If the T-wave and ST-segment abnormalities resolve with nitrate therapy, the cause is most likely spasm. Persistent changes would suggest an acute transmural MI. Non-ischemic chest pain is common in patients who use intranasal cocaine, so differentiating myocardial ischemia from noncardiac chest pain can be challenging. Cocaine can cause ischemic chest discomfort by inducing vasospasm and increasing myocardial oxygen demand by increasing heart rate, blood pressure, and inotropy. Although uncommon, cocaine can provoke an acute MI by spasm associated with thrombus formation due to increasing thrombogenicity as a result of enhanced platelet activation and aggregation. Chronic use is associated with hypertension, left ventricular hypertrophy, cardiomyopathy, myocarditis, and occasionally aortic dissection and stroke. Chronic cocaine use can also result in accelerated atherosclerosis as a result of endothelial dysfunction. Therefore, it is also possible that the infarction is the result of an acute plaque rupture, induced by cocaine and vasospasm. This would occur if the spasm occurs in the area of an atherosclerotic plaque, with resultant plaque disruption, setting up the usual mechanism for thrombus formation and a typical MI.

There are several considerations that the practitioner should take into account when treating cocaine-related myocardial ischemia and/or infarction. β-blockers are relatively contraindicated because of a theoretical risk for severe hypertension and arterial vasoconstriction caused by unopposed α-adrenergic stimulation with ongoing cocaine use. Thrombolysis is relatively contraindicated because of the risk for intracranial hemorrhage and because many patients with ST-segment elevation may also have vasospasm that will not respond to thrombolysis. Also, the treating physician must consider the likelihood of compliance with clopidogrel before placing an intracoronary stent. Balloon angioplasty is a reasonable alternative to restore adequate coronary blood flow with minimal long-term risks. ■

Notes

A 49-year-old man with chronic obstructive pulmonary disease (COPD) develops severe retrosternal chest tightness, diaphoresis, and lightheadedness while eating lunch. This continues without relief for several minutes, so he has a friend drive him to the emergency department. An ECG is obtained immediately upon arrival.

What does his ECG show?

What is the likely diagnosis?

What further treatment is indicated?

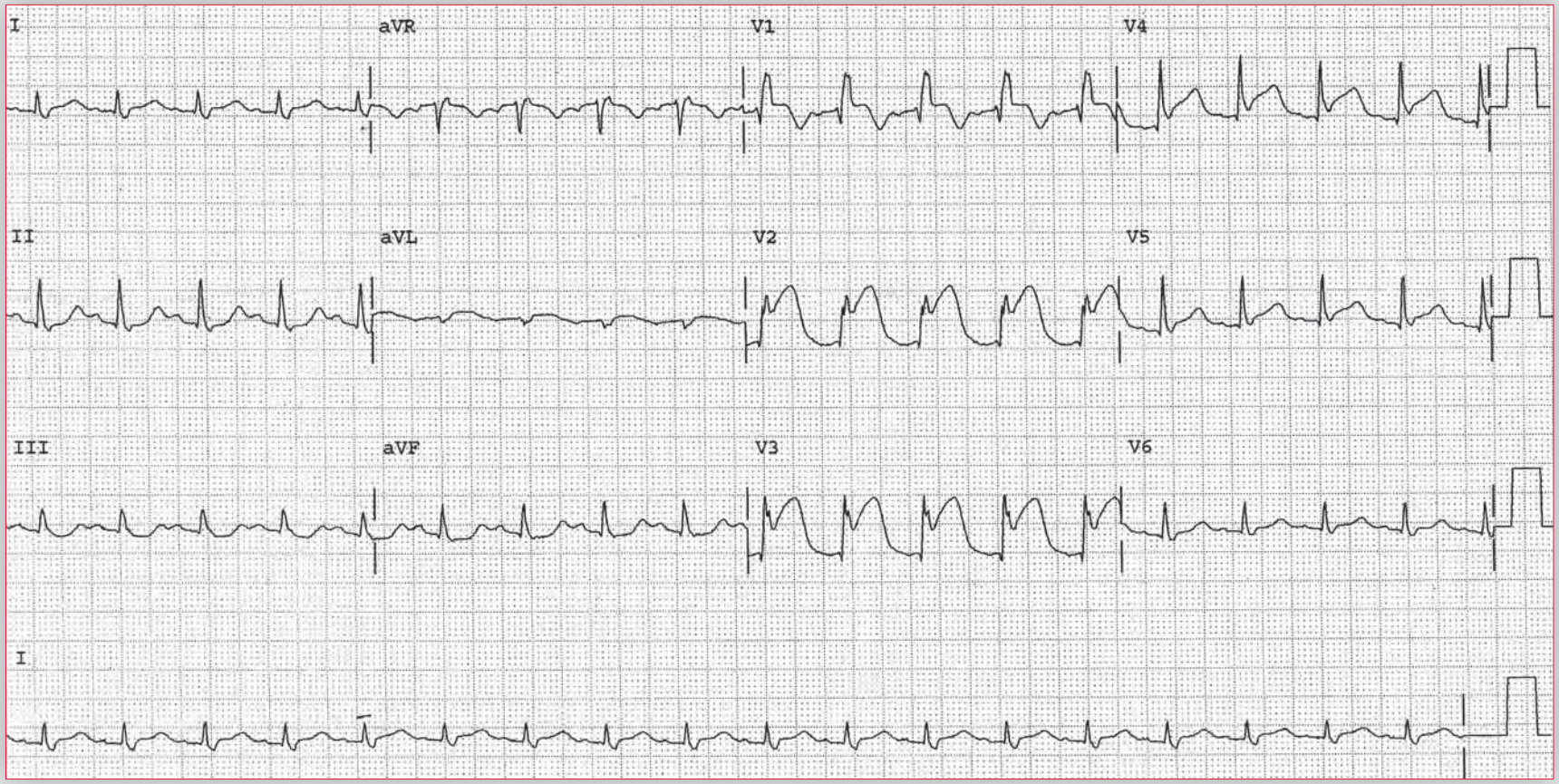

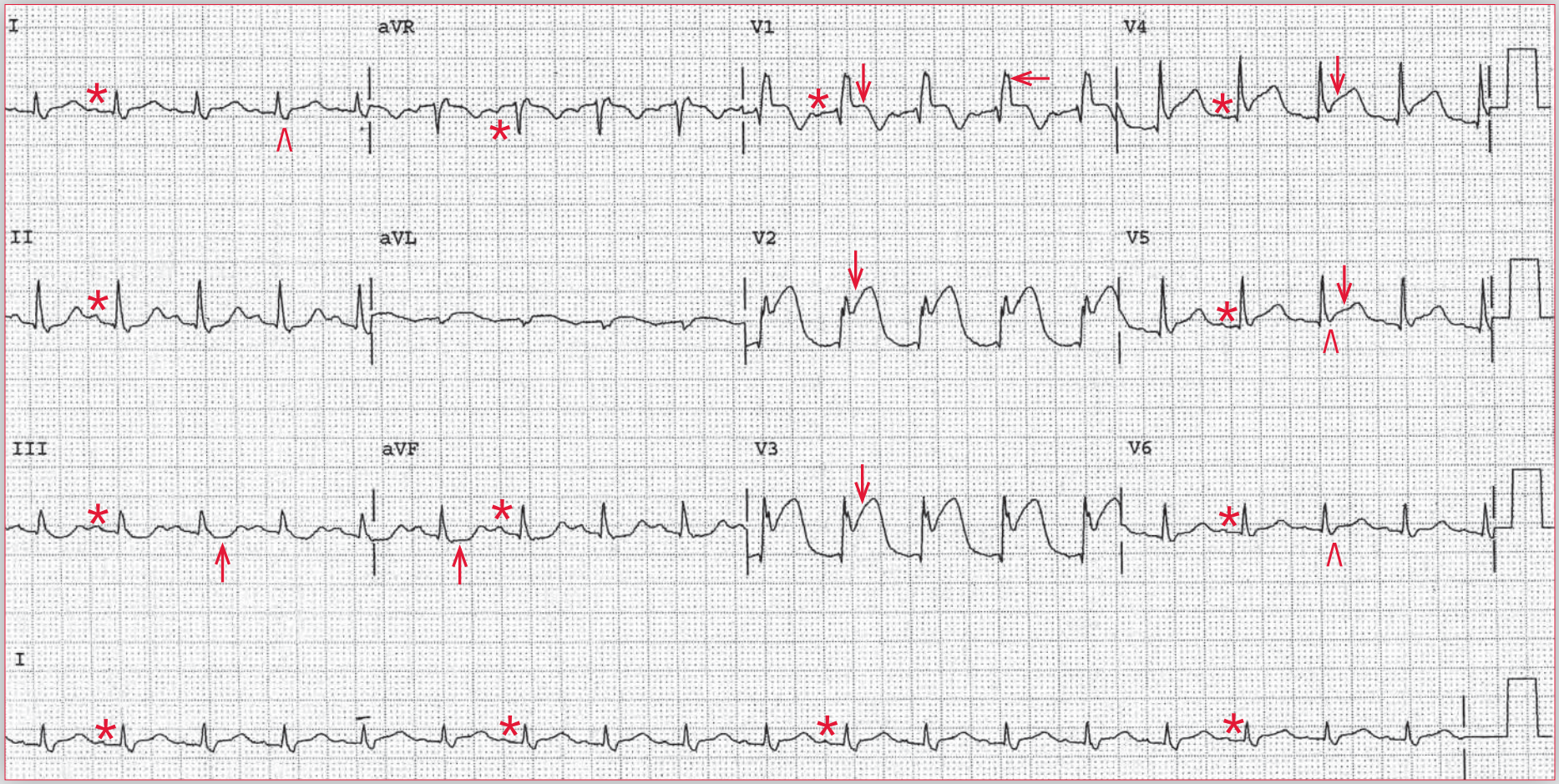

ECG 26 Analysis: Sinus tachycardia, right bundle branch block (RBBB), acute anterior wall ST-segment elevation myocardial infarction (STEMI)

There is a regular rhythm at a rate of 110 bpm. There is a P wave (*) before each QRS complex, and the PR interval is stable (0.16 sec). The P wave is upright in leads I, II, aVF, and V4-V6 and negative in lead aVR. The P-wave morphology is normal. This is a sinus tachycardia.

The QRS complex duration is increased (0.12 sec), and there is a pattern of a right bundle branch block with an RSR′ complex (←) in lead V1 and broad S waves (^) in leads I and V5-V6. The QRS axis is normal, between 0° and +90° (positive QRS complex in leads I and aVF). The QT/QTc intervals are normal (320/430 msec and 280/380 msec when corrected for the prolonged QRS complex duration). There is significant ST-segment elevation (↓) in leads V1-V5. The ST-segment morphology is no longer concave but is now convex and merges with the T wave. Also noted are minimal ST-segment depressions in leads III and aVF (↑); these are reciprocal changes. Hence this is an acute anterior wall ST-segment elevation myocardial infarction (STEMI) involving the septum and apex of the left ventricle.

Interpretation of ischemic changes on ECG in the setting of a right bundle branch block (RBBB) requires an understanding of the effects of an RBBB on the phases of the QRS complex. An RBBB does not alter left ventricular depolarization, which is normal. It does result in a delay in activation of the right ventricle and primarily affects the terminal portion of the QRS complex. Since it does not affect the initial depolarization involving the left ventricle, abnormalities affecting the left ventricle can be interpreted on the ECG, including left ventricular hypertrophy, acute and chronic MI, and pericarditis. Thus Q waves that arise from left ventricular infarction are not affected. Therefore, the diagnoses of old anterior, inferior, apical, or lateral wall MIs are not affected by the presence of an RBBB.

The diagnosis of an acute MI is slightly more challenging. Disruption of the terminal phase of the QRS complex by an RBBB often results in ST-segment depression and T-wave inversion in the right precordial leads. Therefore, the more subtle findings of myocardial ischemia (unstable angina or a non–ST-segment elevation MI [NSTEMI]) of the anterior septum or apex can be obscured by the presence of an RBBB. However, a STEMI, as seen in this case, results in ST-segment elevations that will be obvious on the 12-lead ECG despite the presence of an RBBB.

This patient likely has a chronic RBBB on the basis of his known COPD. However, an RBBB can also develop acutely in the context of an MI that involves the intraventricular septum. A large anterior MI can disrupt the path of the right bundle, although this is uncommon. More often, acute anteroseptal MI results in a left bundle branch block. When an RBBB occurs as a result of an MI, the degree of myonecrosis is usually extensive and the prognosis is poorer. Occasionally, an RBBB reflects acute right ventricular dilation and pressure overload in the context of heart failure with elevated left ventricular filling pressures and pulmonary hypertension.

An acute STEMI is treated with prompt revascularization, with either a thrombolytic agent or percutaneous coronary intervention (*ie*, stenting), which should optimally be performed within 90 minutes of symptom onset. This depends largely on the time it takes for the patient to present to the emergency room. ■

Notes

A 34-year-old woman presents with crushing retrosternal chest pain occurring at rest. She has no prior medical history, although she had an uneventful term pregnancy and delivery 3 weeks prior. The pain is unrelenting and associated with mild dyspnea. Upon arrival to the emergency department, an ECG is obtained.

What does her ECG show?

What is the likely diagnosis?

What further treatment is indicated?

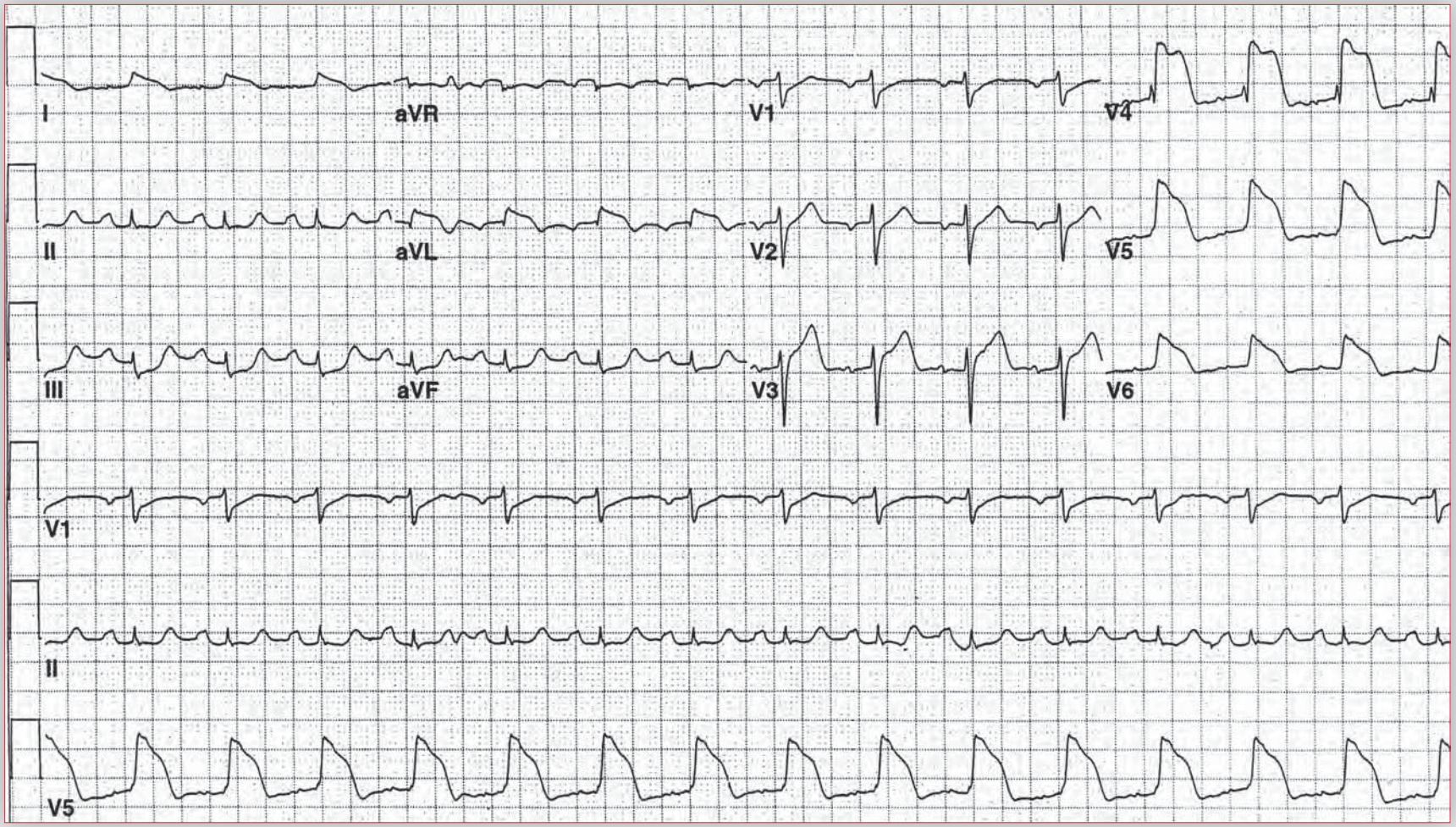

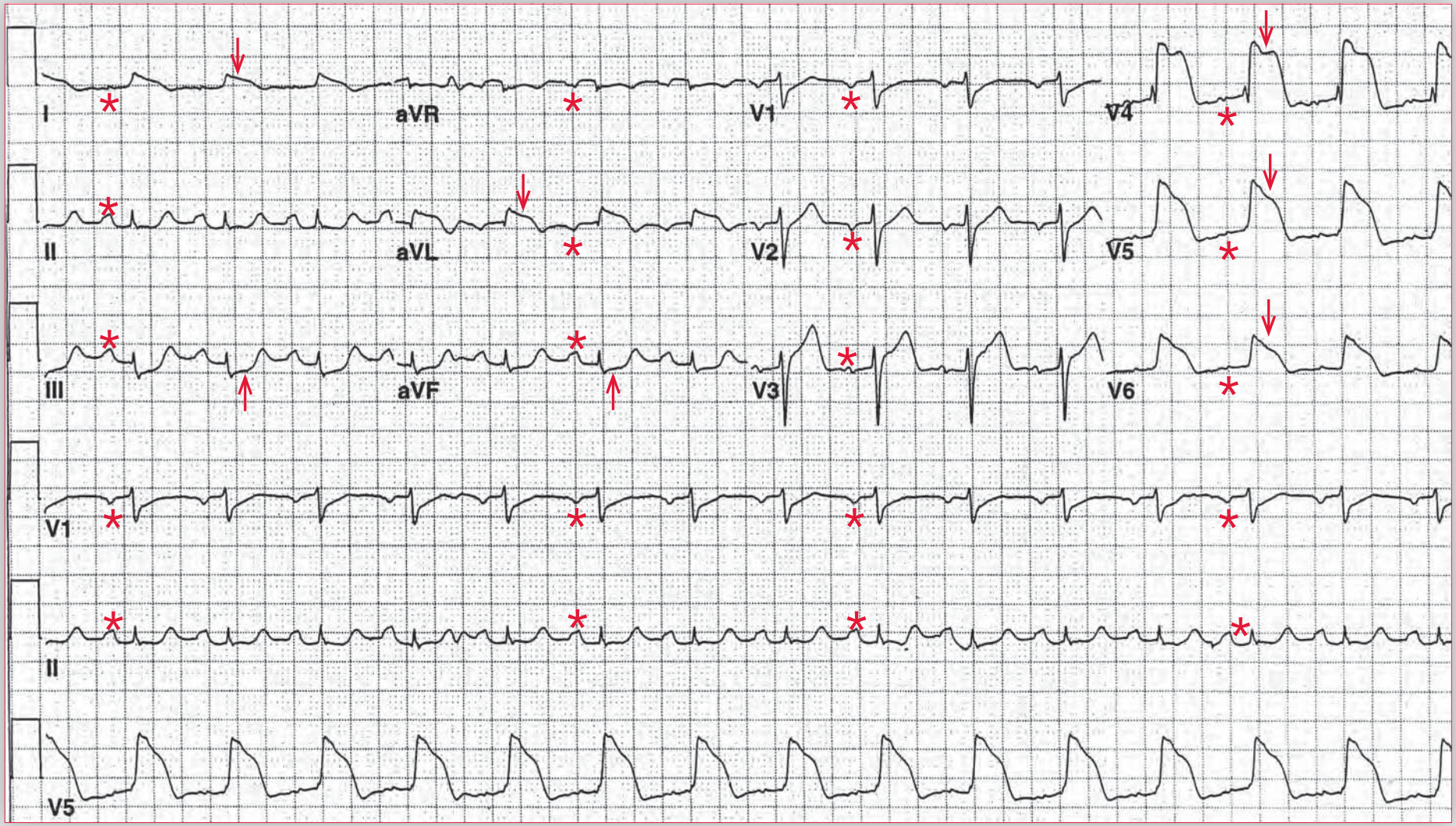

ECG 27 Analysis: Normal sinus rhythm, first-degree AV block, acute anterior wall ST-segment elevation myocardial infarction (STEMI), acute lateral wall MI, left atrial hypertrophy (left atrial abnormality)

There is a regular rhythm at a rate of 90 bpm. There is a P wave (*) before each QRS complex, with a stable PR interval (0.22 sec). The P wave is negative in leads V1-V2, suggesting left atrial hypertrophy. This is a normal sinus rhythm with a first-degree AV block.

The QRS complex duration is normal (0.08 sec), and there is a normal QRS morphology and axis, between 0° and +90° (positive QRS complex in leads I and aVF). The QT/QTc intervals are normal (320/390 msec).

There is significant ST-segment (↓) elevation in leads I, aVL, and V4-V6, representing an acute ST-segment elevation myocardial infarction (STEMI) of the anterolateral and lateral walls. The ST segments are convex and are merged with the T waves; there is loss of R-wave amplitude. This type of QRS complex has been termed "tombstone," but actually the QRS complex morphology has a current of injury and resembles the fast action potential that is generated by the ventricular myocardium as a result of the rapid influx of sodium ion. This is, therefore, a monophasic action potential. Also noted are significant ST-segment depressions (↑) in leads III and aVF, which are reciprocal changes.

An acute STEMI is identified by the presence of localized ST-segment elevation, hyperacute T waves (tall, peaked, and symmetric), and reciprocal ST-segment depressions (due to the same ST-segment changes viewed from another angle or direction). The location of these changes identifies the region of the myocardium involved.

This young woman may have a coronary artery dissection, which might be due to an acute dissection of the aortic root or an isolated coronary artery dissection. Although coronary artery dissection is rare, it is an important cause of MI in young, otherwise healthy individuals. There is a particular increase in the risk for coronary dissection in the peripartum period. It has been suggested that arterial dissection during or soon after pregnancy is related to structural changes in the intima and media of the arterial wall that are produced by hormonal and hemodynamic changes. Although dissection can occur in the absence of risk factors, it may occur more frequently in conditions associated with hypertension that independently damage the arterial wall. The finding of spontaneous coronary artery dissection should trigger the search for a previously undiagnosed connective tissue disease, such as Marfan or Ehler-Danlos syndrome.

Unfortunately, the treatment for coronary artery dissection is difficult and complications of MI, including malignant ventricular arrhythmias and sudden cardiac death, can occur. Patients are often treated with systemic anticoagulation in order to minimize thrombosis at the site of the dissection. There is a potential role for coronary stenting, although this is controversial. In theory, placing an intracoronary stent may stabilize the leading edge of the dissection flap, although there is a risk for stenting into the false lumen and thus propagating the dissection and jeopardizing flow through distal vessel branches. ■

Notes

A 72-year-old woman presents for her first clinic visit with a new primary care provider. She has a history of hypertension and diabetes and suffered a myocardial infarction 18 months earlier. She is currently feeling well but does note heartburn on a nearly daily basis when she lies down to go to sleep at night. Concerned about her heartburn symptoms possibly being related to cardiac ischemia, her primary care physician obtains an ECG.

What does her ECG show?

What is the likely diagnosis?

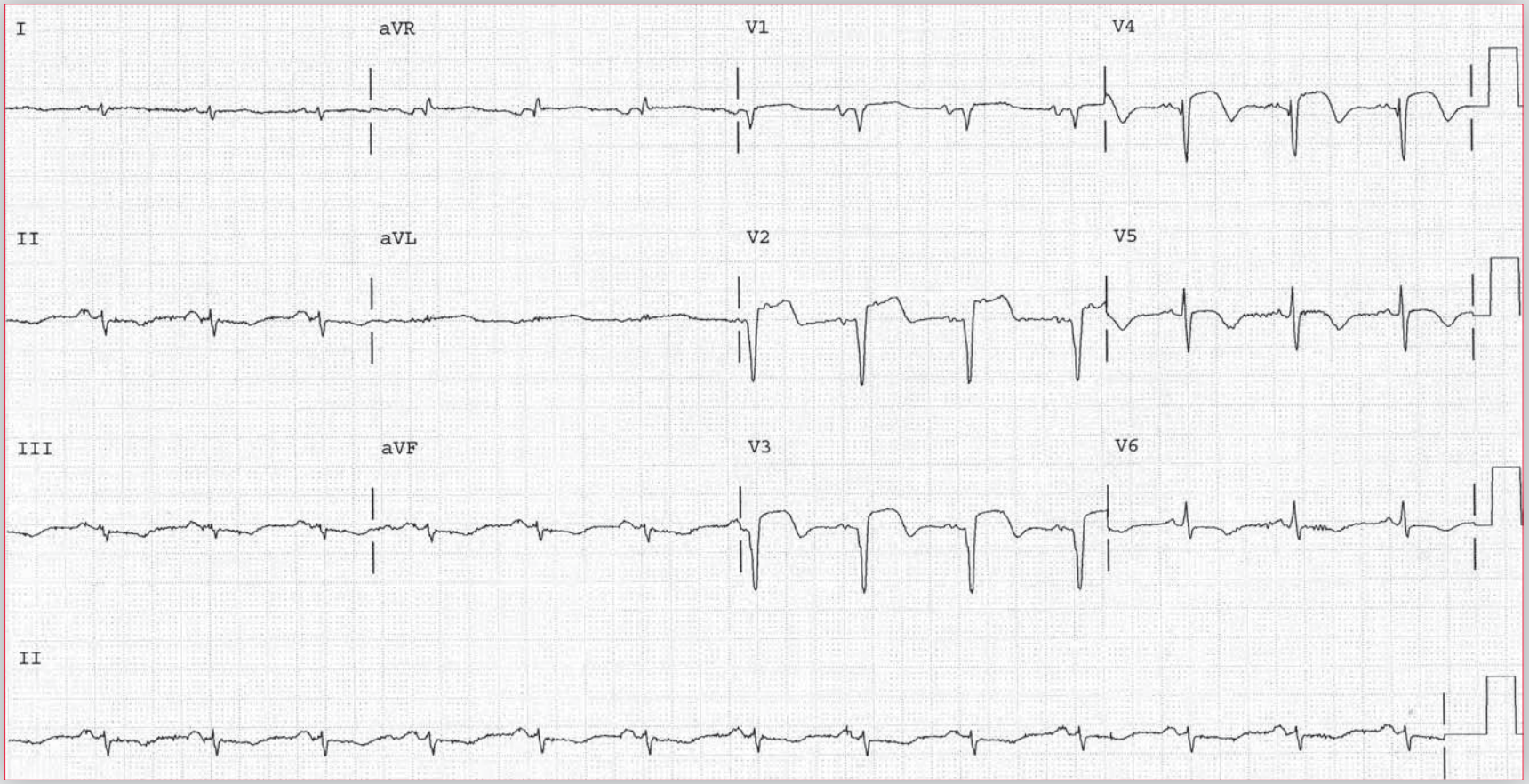

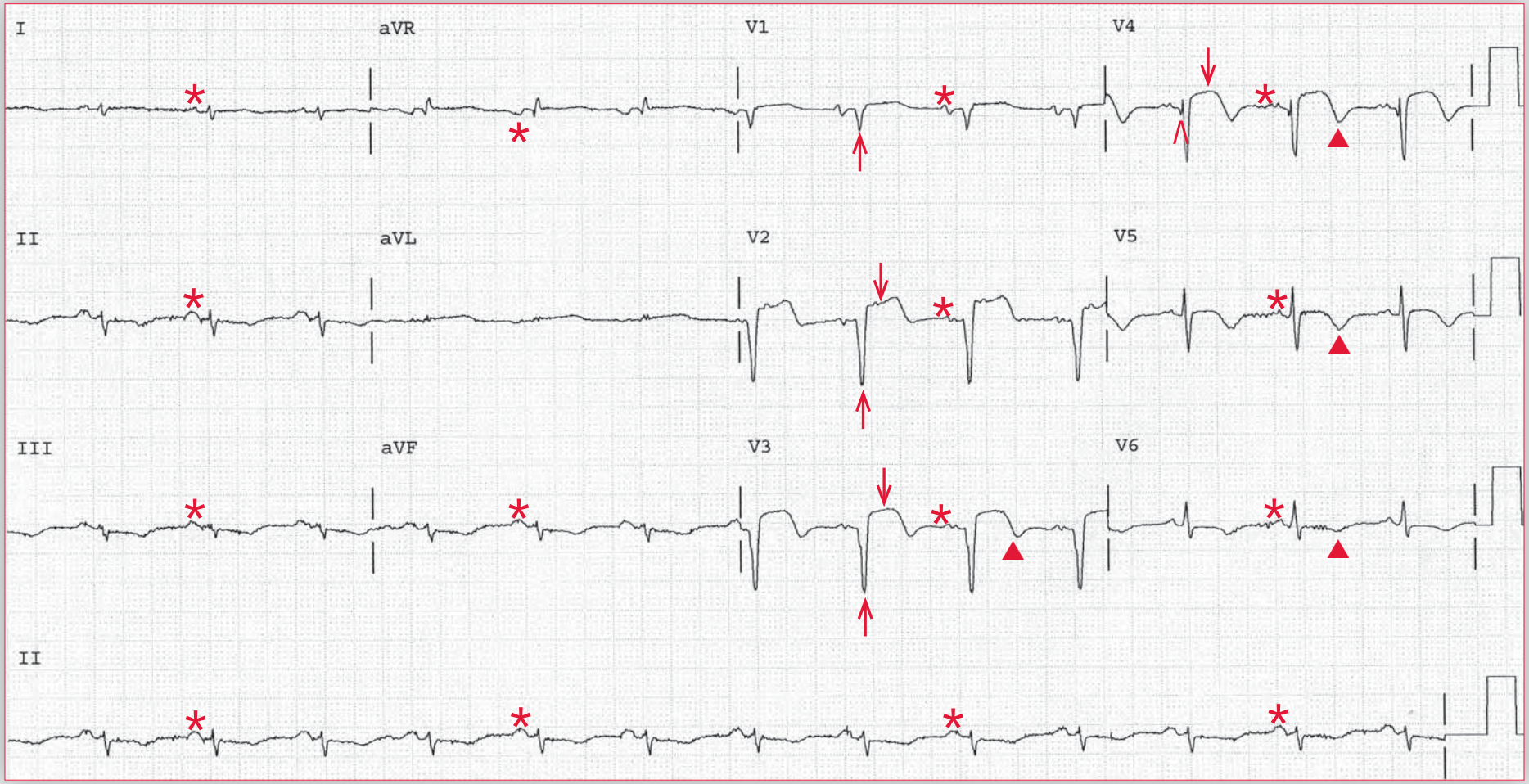

ECG 28 Analysis: Normal sinus rhythm, left anterior fascicular block, old anterior wall myocardial infarction (MI), ST-segment elevation due to aneurysm

There is a regular rhythm at a rate of 80 bpm. There is a P wave (*) before each QRS complex, with a stable PR interval (0.14 sec). The P wave is positive in leads I, II, aVF, and V4-V6. This is a normal sinus rhythm. The P wave is broad in leads II and aVF and notched in leads V2-V4, suggesting left atrial hypertrophy.

The QRS complex duration is normal (0.08 sec). There is low voltage in the limb leads (defined as a QRS complex amplitude ≤ 5 mm in each lead). The QRS axis is extremely leftward, between –30° and –90° (positive QRS complex in lead I and negative QRS complex in leads II and aVF). As there are no Q waves in leads II, III, or aVF, indicating an old inferior wall myocardial infarction (MI) accounting for the left axis deviation, this is a left anterior fascicular block. The QT/QTc intervals are prolonged (420/480 msec).

There is a QS complex (↑) in leads V1-V3 and an initial Q wave in lead V4 (^), diagnostic for an MI involving the left ventricular septum and apex. The ST segments are still elevated (↓), and the T waves (▲) are inverted. Based on the patient's history of an MI 18 months earlier, the ST-segment elevation, which is persistent, represents an old MI and development of an apical left ventricular aneurysm. However, without this history it would be unclear whether the ST-segment elevation was persistent and the result of an aneurysm or had recently occurred in the setting of an acute MI and hence represents evolution of the ECG changes. A left ventricular aneurysm is a complication of ST-segment elevation (transmural) MI (STEMI), which results from a thin and dyskinetic region of myocardium in the distribution of a prior MI. Left ventricular aneurysms are associated with mural thrombus formation and systemic cardio-embolization (when they develop early in the setting of an acute MI), re-entrant ventricular arrhythmia, and heart failure. Patients are treated with anticoagulation with warfarin for 3 months after an acute MI if thrombus is seen. Some physicians will anticoagulate patients with a left ventricular aneurysm even in the absence of thrombus to minimize the risk for thrombus formation that occurs as a result of the acute inflammation of the myocardium. Occasionally, surgery (aneurysmectomy) is necessary when symptoms of recurrent embolization, heart failure, or intractable arrhythmias develop.

A true left ventricular aneurysm should be distinguished from a pseudo-aneurysm, both of which can arise as sequelae of MI. A pseudo-aneurysm is a contained myocardial rupture in which the outer layer of the outpouching is comprised of adherent pericardium rather than myocardium. Pseudo-aneurysms are at risk for rupture and often require surgical resection. ■

Notes

A 54-year-old man develops epigastric discomfort and nausea while driving home from his job as a night watchman. The sensation does not abate and when he arrives home he begins to feel diaphoretic and the chest and epigastric pain intensify. He calls emergency medical services, who obtain an ECG immediately upon arrival.

What does his ECG show?

What is the likely diagnosis?

What coronary artery is likely involved?

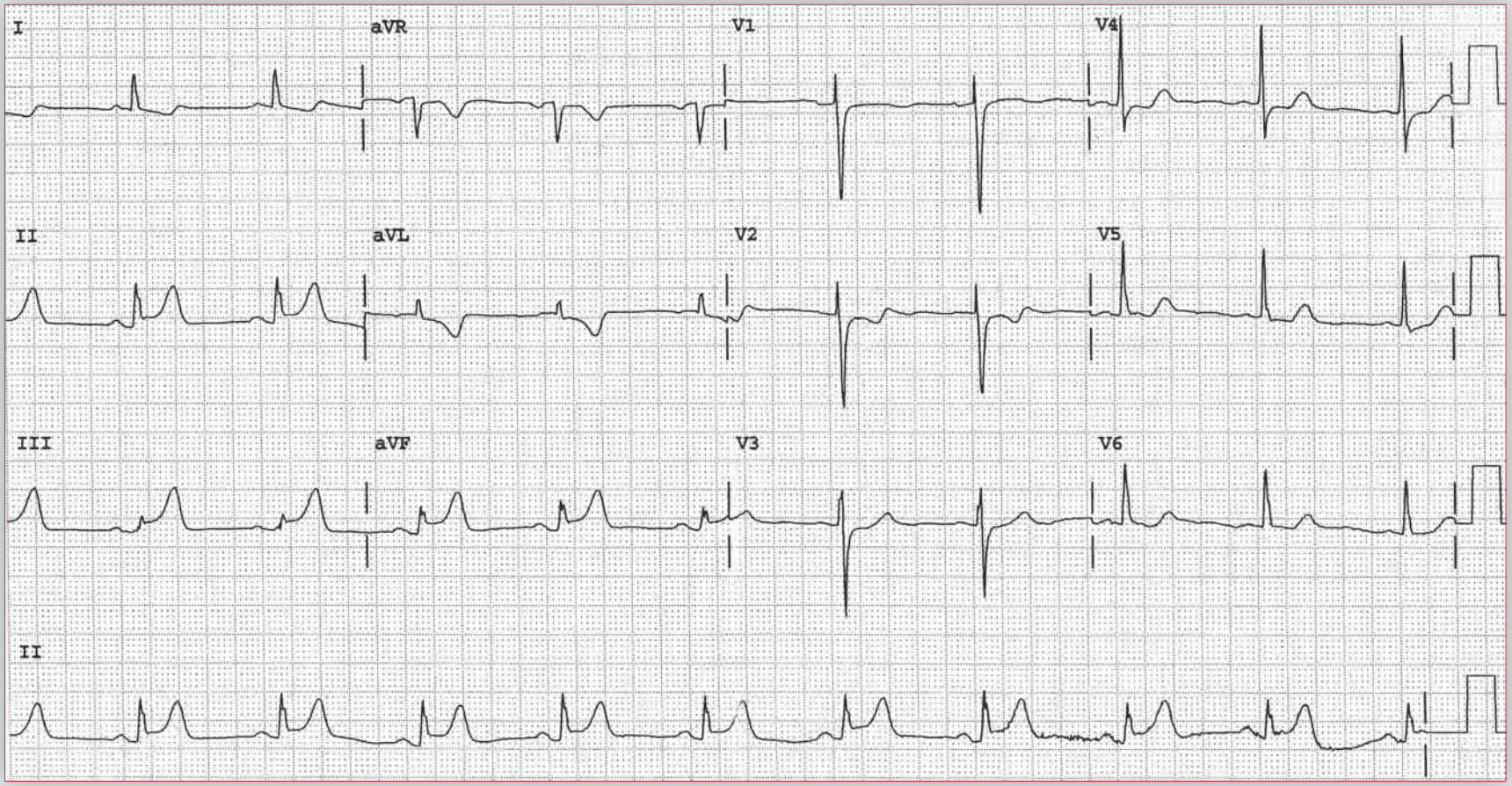

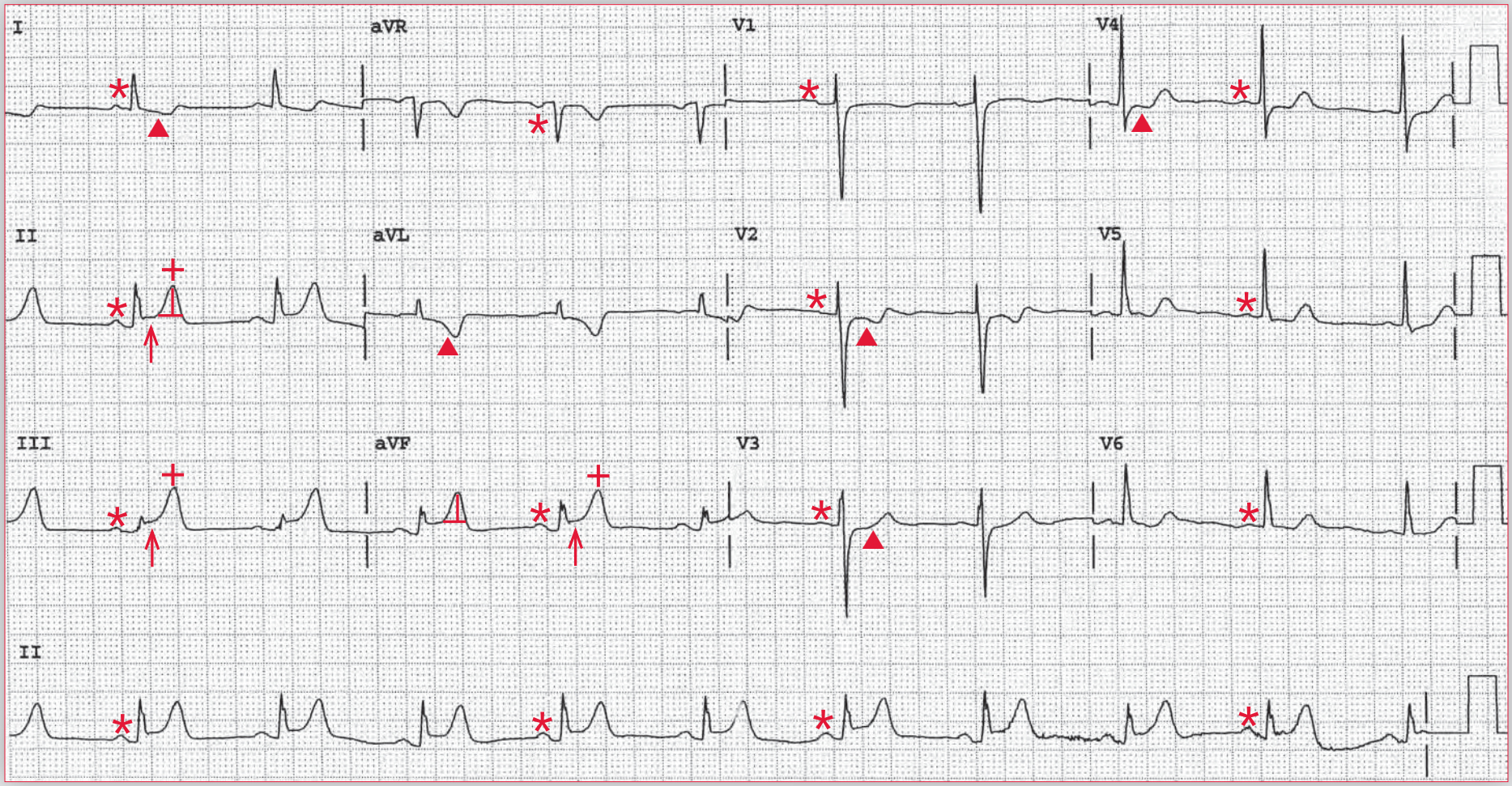

ECG 29 Analysis: Normal sinus rhythm, acute inferior wall ST-segment elevation myocardial infarction (STEMI)

There is a regular rhythm at a rate of 60 bpm. There is a P wave (*) before each QRS complex with a stable PR interval (0.16 sec). The P wave is positive in leads I, II, aVF, and V4-V6 and negative in lead aVR. This is a normal sinus rhythm.

The QRS complex duration is normal (0.08 sec), with a normal morphology and axis, between 0° and +90° (positive QRS complex in leads I and aVF). The QT/QTc intervals are normal (400/400 msec). The T waves (+) are tall and symmetric in leads II, III, and aVF, and the ST segments (↑) are slightly elevated in these leads and have a normal concave morphology. This is an early acute inferior wall ST-segment elevation myocardial infarction (STEMI). The ST segments (▲) in leads I, aVL, and V2-V4 are depressed and there is T-wave inversion, representing reciprocal changes. However, it is possible that the ST-segment changes in leads V2-V4 are the result of posterior wall involvement. A posterior wall MI can be confirmed by obtaining posterior leads V7-V8, placed under the left scapula.

This patient should undergo urgent reperfusion therapy. If he can be transferred within 90 minutes to a tertiary care center that has cardiac catheterization capability, he should undergo primary percutaneous coronary intervention. Otherwise, he should receive thrombolytic therapy. Coronary angiography is likely to show occlusion of the right coronary artery (RCA), although an inferior MI can also be caused by occlusion of a dominant left circumflex coronary artery that supplies the posterior descending artery. A clue to the culprit vessel is the relative degree of ST-segment elevation in leads II and III. If the degree of ST-segment elevation in lead III is greater than that in lead II, the artery most likely to be involved is the RCA. If the degree of ST-segment elevation in lead II is greater than that in lead III, the occlusion is more likely to be in a dominant circumflex artery. The left circumflex artery would most likely be the culprit vessel if there were a posterior wall MI. ■

Core Case 30

A 48-year-old man with dyslipidemia and hypertension develops nausea and chest pressure while mowing the lawn. He stops to rest and the pain slowly abates. A few hours later the pain recurs and he takes an antacid with no effect. Over the course of the next 2 hours the pain waxes and wanes

ECG 30A

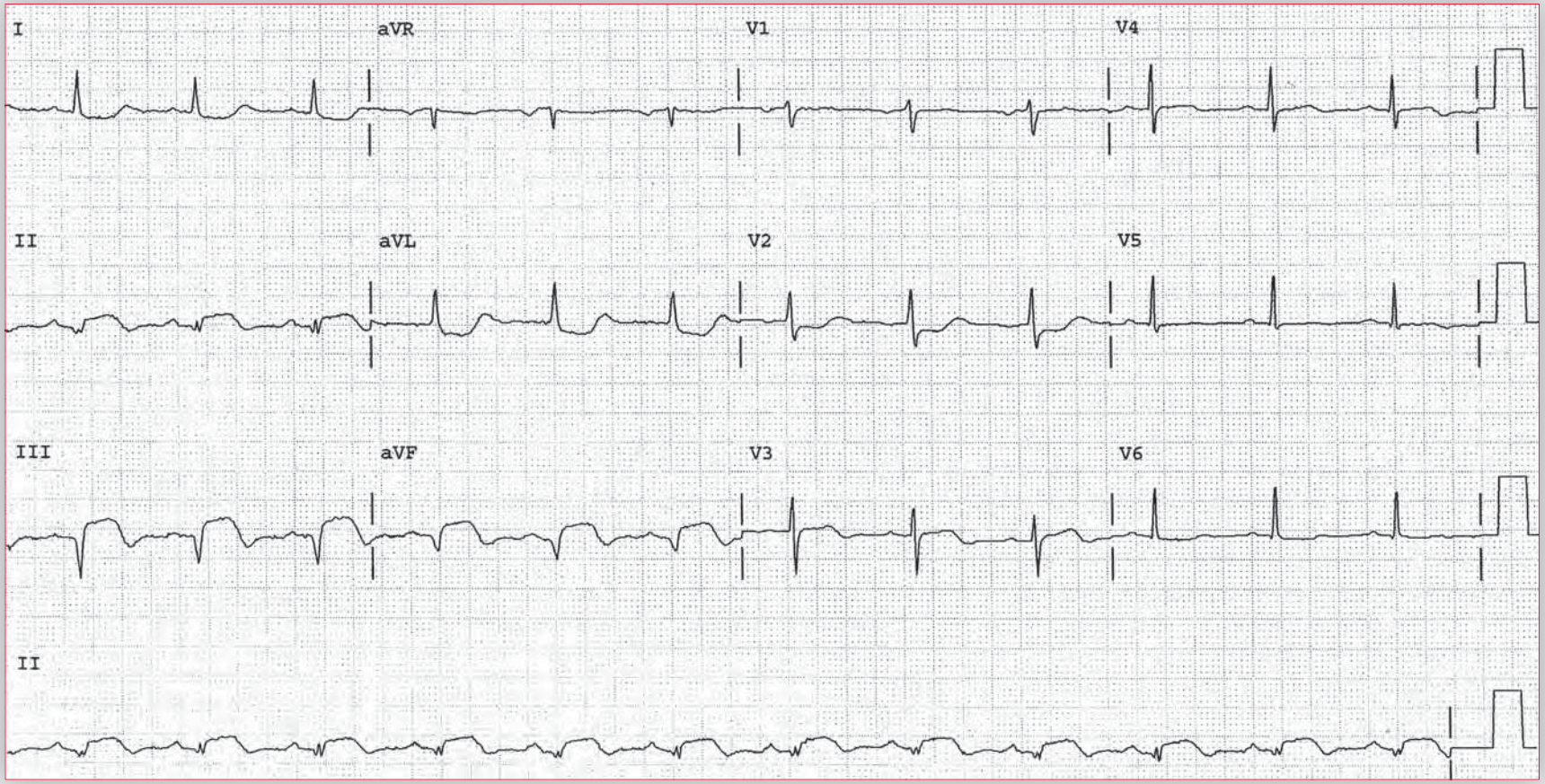

until he decides to seek medical attention. By the time he arrives in the emergency department, the man is nauseated and diaphoretic and he subsequently vomits. An ECG (30A) is obtained. Based on the results, a second ECG (30B) is recorded shortly thereafter.

What do the ECGs show?

What part of the myocardium is likely involved?

What simple noninvasive test can be performed at the bedside to clarify the diagnosis?

ECG 30B

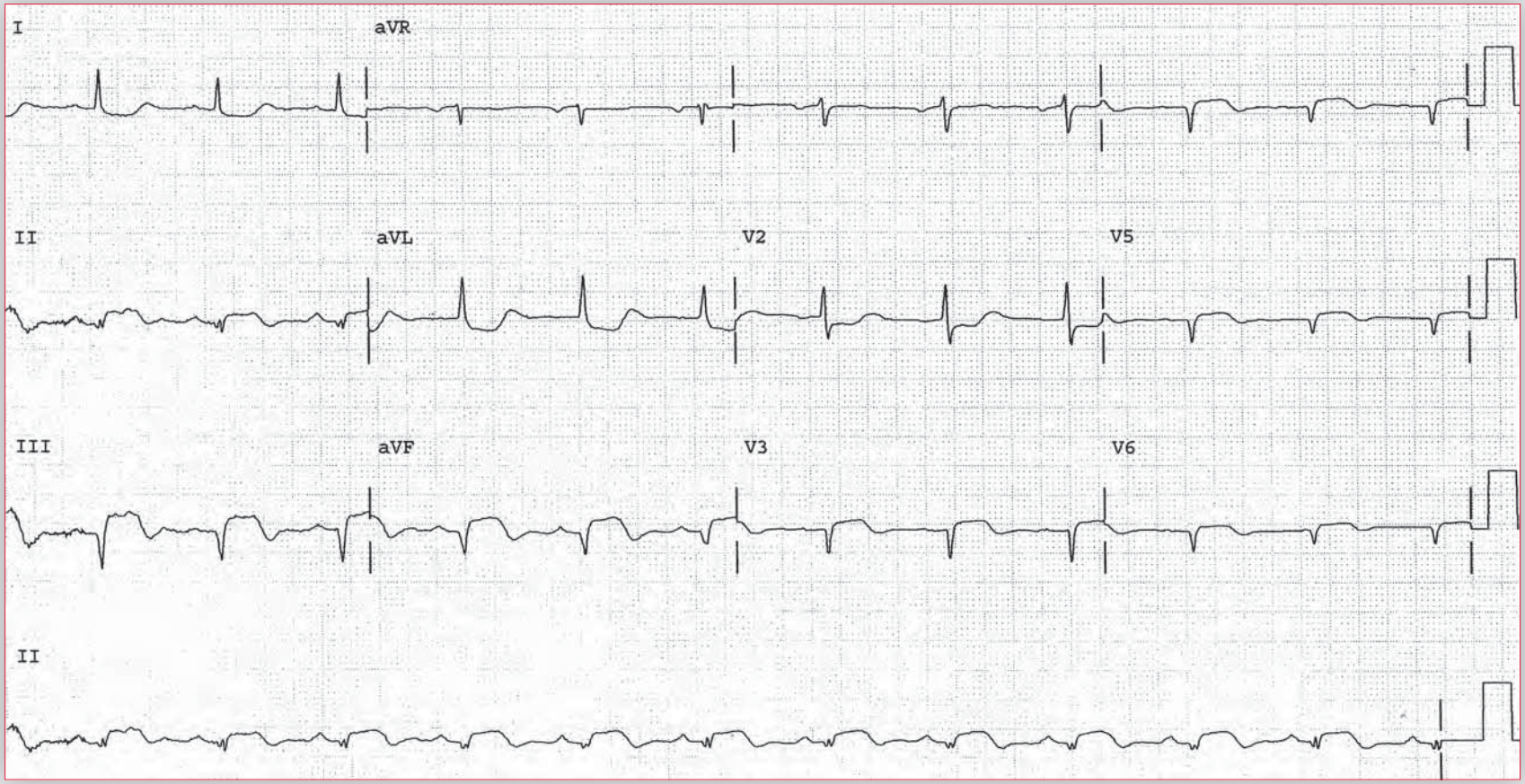

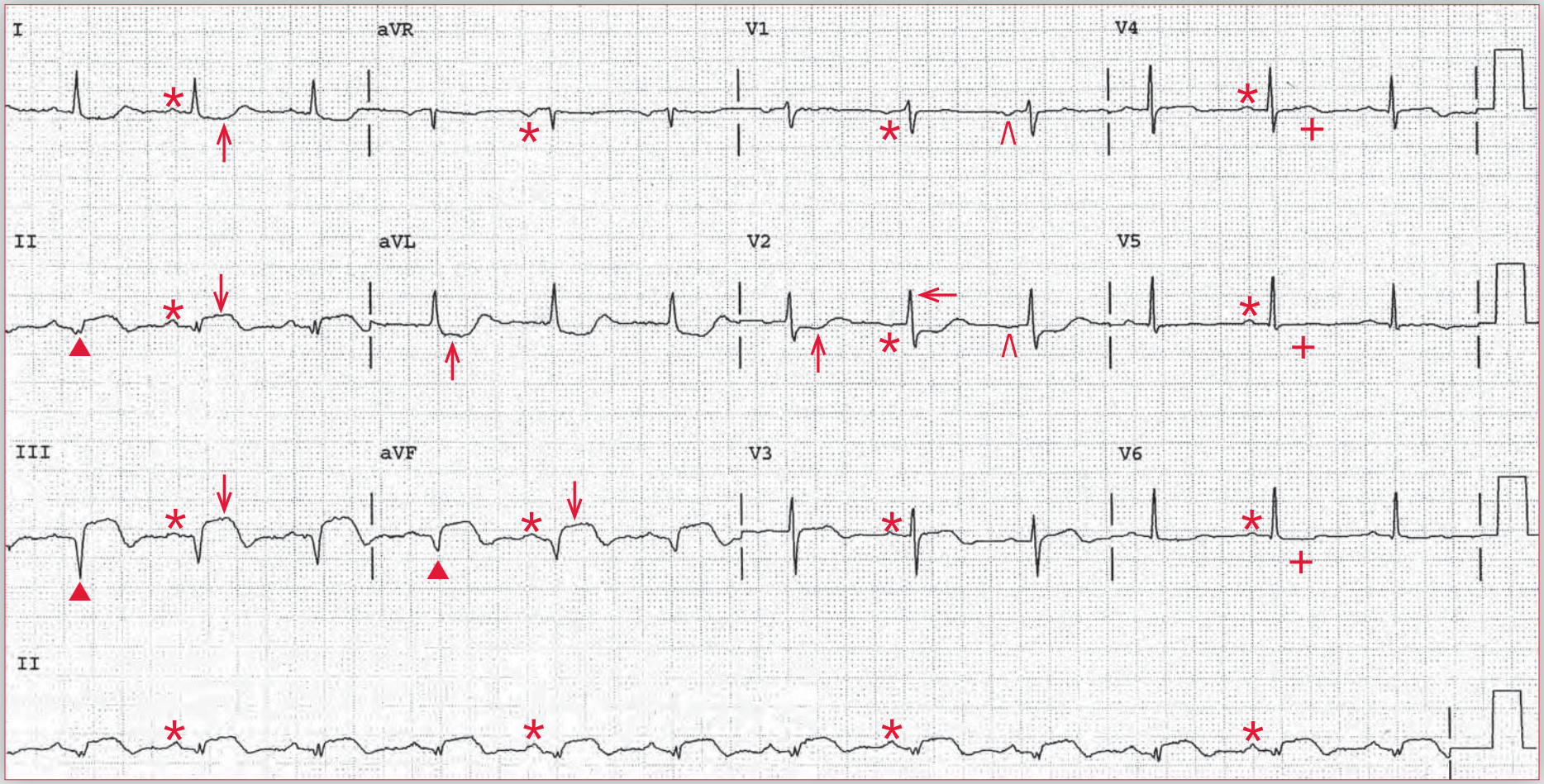

ECG 30A Analysis: Normal sinus rhythm, left atrial hypertrophy, counterclockwise rotation (early transition), acute inferior wall ST-segment elevation myocardial infarction (STEMI)

ECG 30A shows a regular rhythm at a rate of 74 bpm. There is a P wave (*) before each QRS complex, with a stable PR interval (0.18 sec). The P waves are positive in leads I, II, aVF, and V4-V6 and negative in lead aVR. This is a normal sinus rhythm. The P wave is negative in leads V1-V2 (^), suggesting left atrial hypertrophy.

The QRS complex duration is normal (0.08 sec). There is early transition, with a tall R wave (←) in lead V2. This is termed counterclockwise rotation, which is determined by imagining the heart as viewed from under the diaphragm. When there is counterclockwise electrical rotation, left ventricular forces are seen earlier in the precordial or chest leads, accounting for early transition with a tall R wave in lead V2. The QT/QTc intervals are normal (380/420 msec).

There is ST-segment elevation (↓) in leads II, III, and aVF, and the ST segments are convex and merge with the T waves. The T waves are biphasic in these leads. Therefore, this is an acute inferior wall ST-segment elevation myocardial infarction (STEMI) in evolution. There are also Q waves (▲) in these leads, giving the appearance of an extreme left axis deviation, between –30° and –90° (positive QRS complex in lead I and negative QRS complex in leads II and aVF). However, this is the result of an inferior wall infarction and not an axis shift due to a conduction abnormality (*ie*, this is not a left anterior fascicular block).

There are also ST-segment depressions (↑) in leads I and aVL as well as lead V2. These are reciprocal ST-segment changes, although the ST-segment depression in lead V2 might suggest posterior wall involvement. There are also nonspecific ST-T wave changes in leads V4-V6 (+).

continues

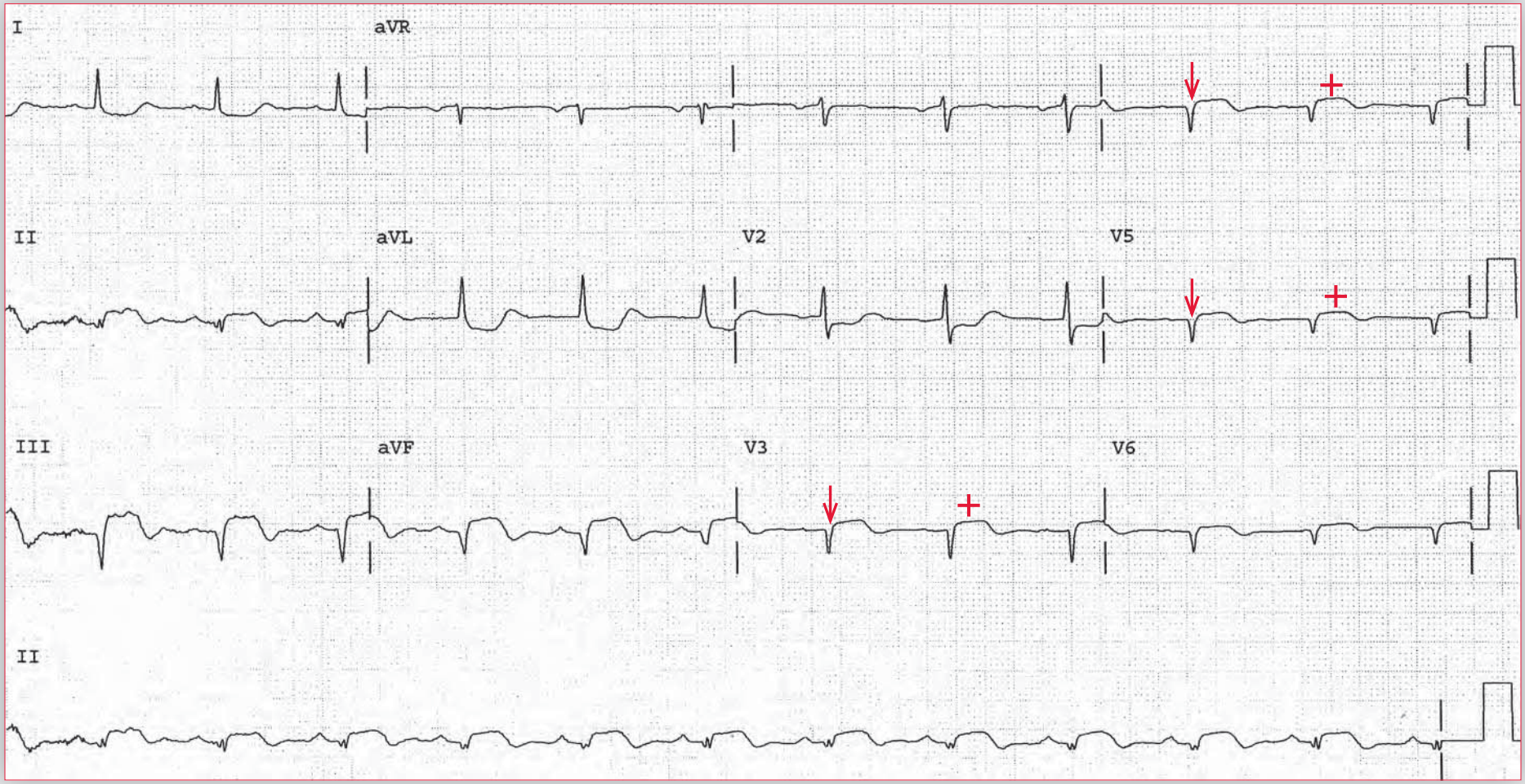

ECG 30B Analysis: Right-sided leads, right ventricular infarction

In **ECG 30B**, the limb leads are identical to those in **ECG 30A** and they show an acute inferior wall STEMI. However, the precordial leads are different and there is loss of R waves (↓) in leads V3-V6 with QS complexes noted. These are right-sided leads, which are often obtained in patients presenting with an acute inferior wall STEMI to evaluate for the presence of an infarction of the free wall of the right ventricle. Although the inferior wall of the right ventricle, which is contiguous with the inferior wall of the left ventricle, is often involved with an inferior wall MI, involvement of the free wall of the right ventricle, which is a true right ventricular wall infarction, is less common. The ST-segment elevation (+) seen in right-sided leads RV3-RV5 indicates that a right ventricular infarction is also present along with the inferior wall infarction. The presence of a right ventricular infarction means that the right coronary artery is the culprit vessel.

Establishing the presence of a right ventricular infarction is of clinical importance as the patient is volume dependent. Any change in venous return or vascular volume has major effects on right ventricular filling and stroke volume from the right ventricle, which then impacts left ventricular filling and left ventricular stroke volume. For example, the administration of nitroglycerin will reduce venous return to the right ventricle and in the presence of significant right ventricular dysfunction left ventricular preload and hence left ventricular stroke volume will be reduced, resulting in hypotension. A similar situation may occur if the patient receives a diuretic, which is often administered when there is evidence of pulmonary vascular congestion. The occurrence of hypotension might suggest the development of cardiogenic shock, rather than an issue of significant reduction in left ventricular preload.

In this patient, posterior leads placed under the left scapula (*ie*, leads V7-V8) should also be obtained given the ST-segment depression in lead V2, which may represent posterior wall involvement. Although the tall R wave in lead V2 is most likely due to early transition (counterclockwise rotation), there is a possibility that it may be a posterior wall MI. However, this is not likely given the absence of a tall R wave in lead V1. ■

Core Case 31

A 64-year-old woman with diabetes and a long smoking history presents with left-sided chest discomfort that awakened her from her sleep. The discomfort was unrelenting, and she sought immediate medical attention. An ECG (31A) is obtained upon arrival to the emergency department, and a second ECG (31B) is obtained before the patient is given nitroglycerin.

ECG 31A

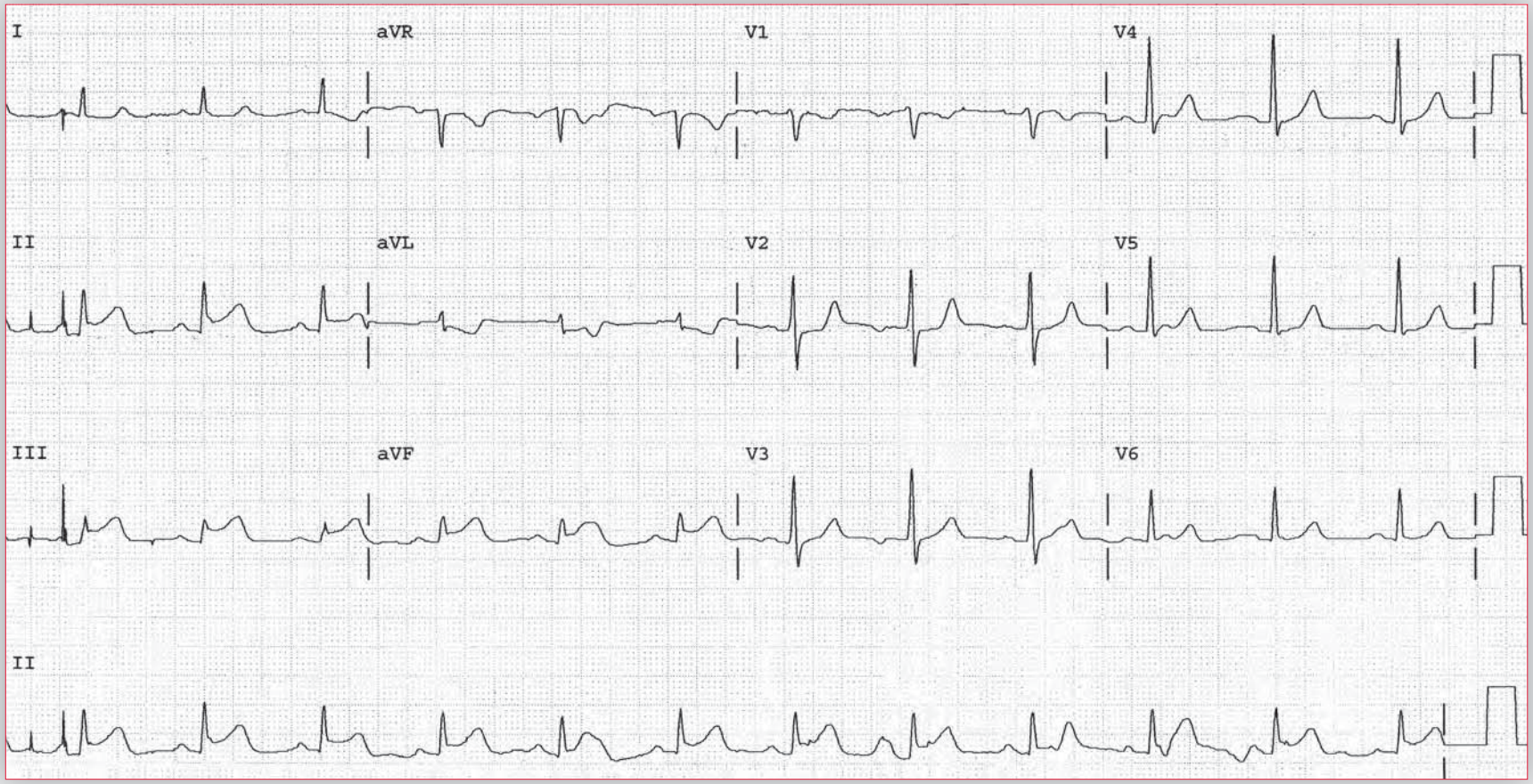

What do the ECGs show?

What is the rationale for obtaining ECG 31B?

What is the likely diagnosis?

What coronary artery is likely to be involved?

ECG 31B

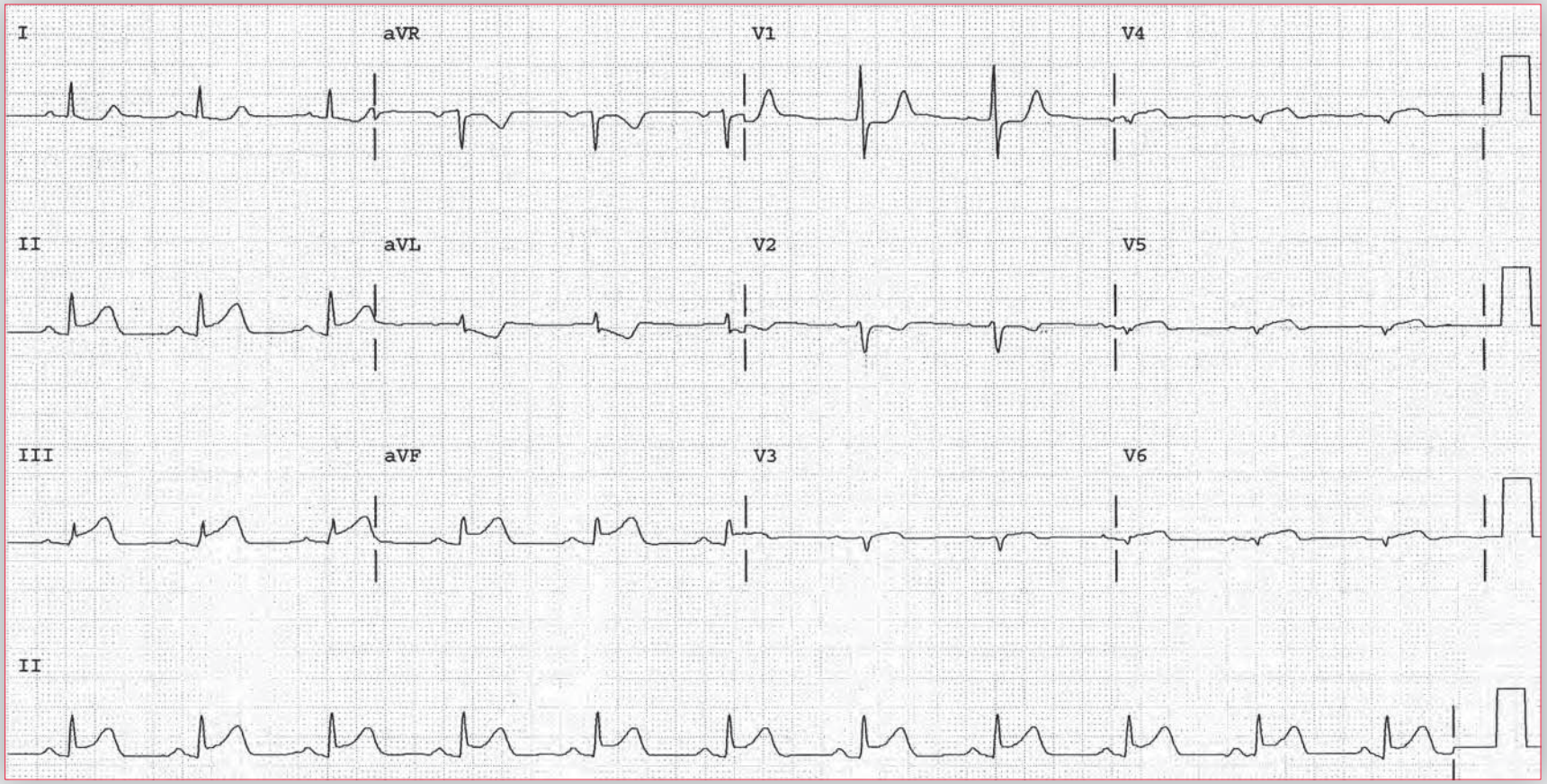

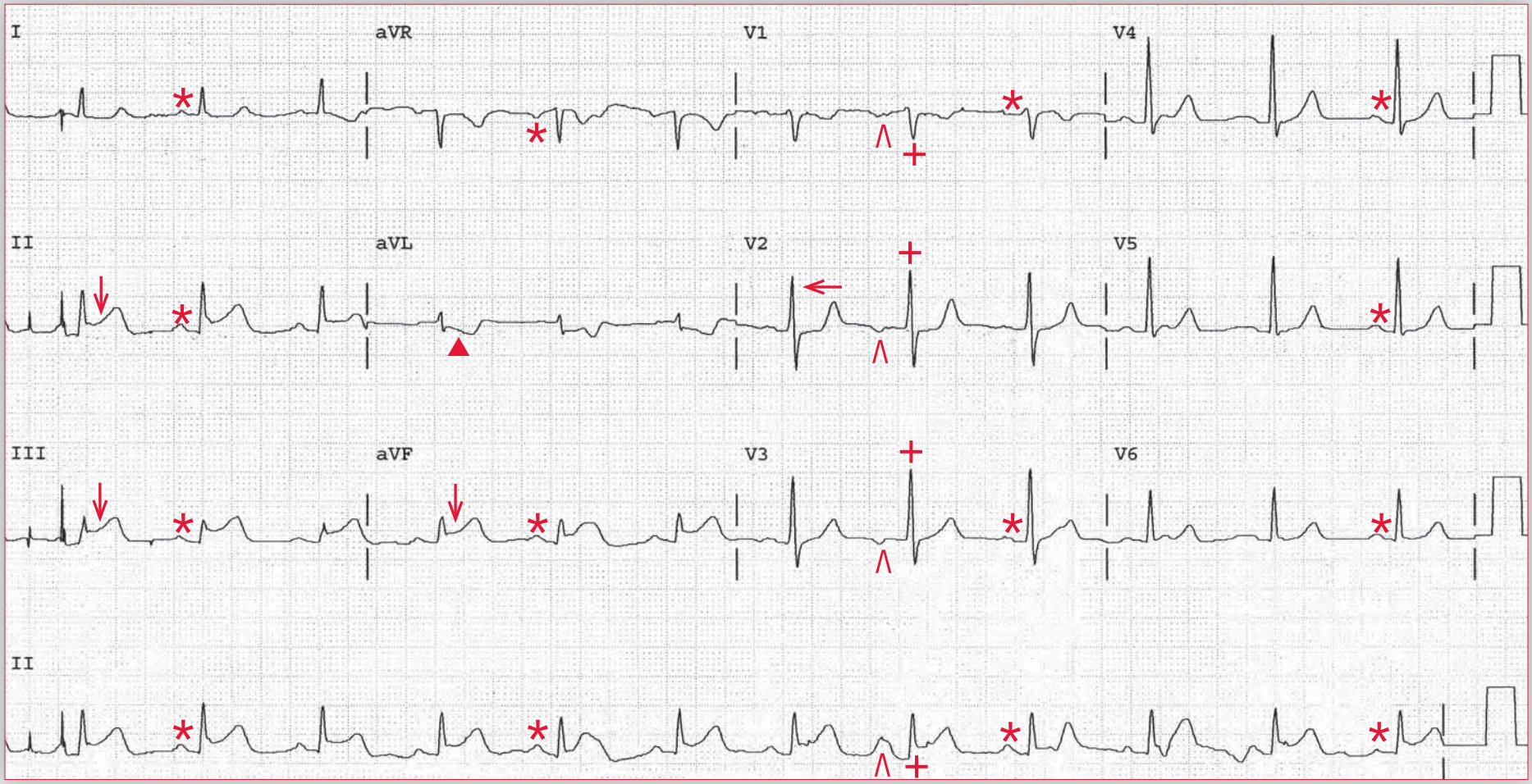

ECG 31A Analysis: Normal sinus rhythm, counterclockwise rotation (early transition), premature atrial complex, acute inferior wall ST-segment elevation myocardial infarction (STEMI)

The rhythm in **ECG 31A** is regular at a rate of 72 bpm. There are P waves (*) before each QRS complex with a stable PR interval (0.20 sec). The P wave is positive in leads I, II, aVF, and V4-V6 and negative in lead aVR. The P-wave morphology is normal. This is a normal sinus rhythm. The eighth QRS complex is early (+) and the P wave before it (^) has a different morphology (*ie*, it is negative in leads V1-V3) compared with the other P waves. This is a premature atrial complex.

The QRS complex duration is normal (0.08 sec), and there is a normal axis, between 0° and +90° (positive QRS complex in leads I and aVF). The QT/QTc intervals are normal (360/390 msec). There is early transition with a tall R wave (←) in lead V2. This is termed counterclockwise rotation, determined by imagining the heart as viewed from under the diaphragm. When there is counterclockwise electrical rotation, left ventricular forces are seen earlier in the precordial or chest leads, accounting for early transition with a tall R wave in lead V2.

There is ST-segment elevation (↓) in leads II, III, and aVF, and the ST segments have a normal convex morphology. This is an acute inferior wall ST-segment elevation myocardial infarction (STEMI). ST-segment depression (▲) can be seen in lead aVL, which represents a reciprocal change.

continues

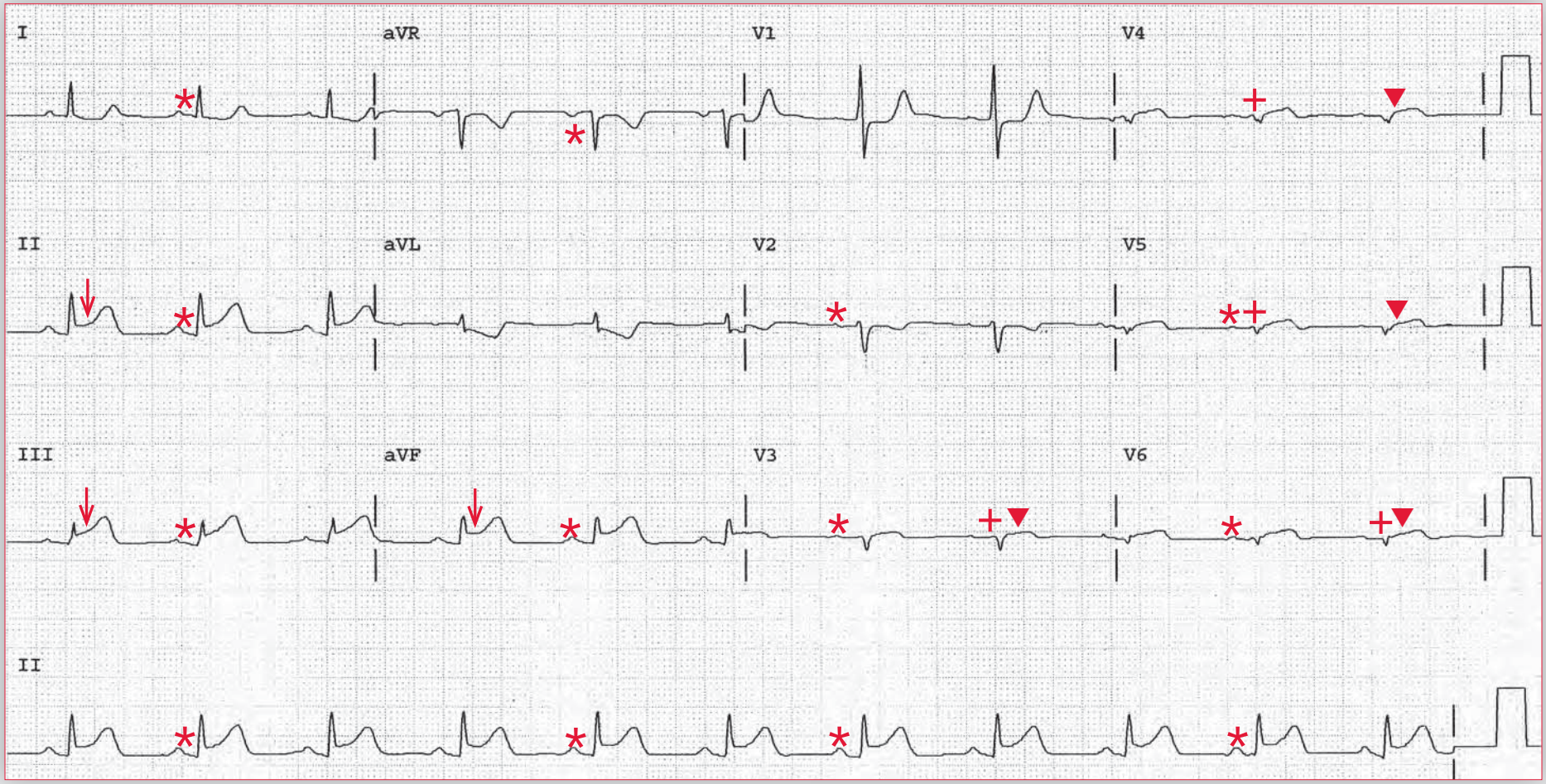

ECG 31B Analysis: Acute inferior wall ST-segment elevation myocardial infarction (STEMI), right-sided leads, no right ventricular infarction

In **ECG 31B**, the P waves (*), QRS complexes, and inferior ST-segment elevation (↓) are the same as in **ECG 31A**. Therefore, there is an acute inferior wall STEMI present. The precordial or chest leads are different from those in **ECG 31A**, and there is loss of R-wave amplitude (+) in leads V4-V6. These are right-sided leads and the ECG was recorded with the precordial leads on the right side of the chest. No ST-segment elevation (▼) is seen in leads RV3-RV6. Hence there has not been any acute involvement of the right ventricular free wall (*ie*, there is no right ventricular infarction present). This is typical for occlusion of either a dominant circumflex artery or the right coronary artery after the takeoff of the principal right ventricular branch.

Right-sided leads should be obtained routinely in patients presenting with an inferior wall STEMI as right ventricular involvement is not uncommon. When there is a right ventricular infarction, the patient is volume dependent (*ie*, there needs to be adequate volume in the setting of reduced right ventricular function for a normal stroke volume to fill the left ventricle). Situations that reduce right ventricular filling, such as administration of nitrates (reducing venous return and preload) and diuretics (reducing vascular volume), may result in underfilling of the right ventricle and hence underfilling of the left ventricle with resultant hypotension. ■

Core Case 32

A 57-year-old woman is awakened from sleep in the early morning with sudden-onset chest pressure. She calls emergency medical services, who obtain an ECG at her bedside. She is then given sublingual nitroglycerin, and the pain resolves within 5 minutes. A second ECG is then obtained.

ECG 32A

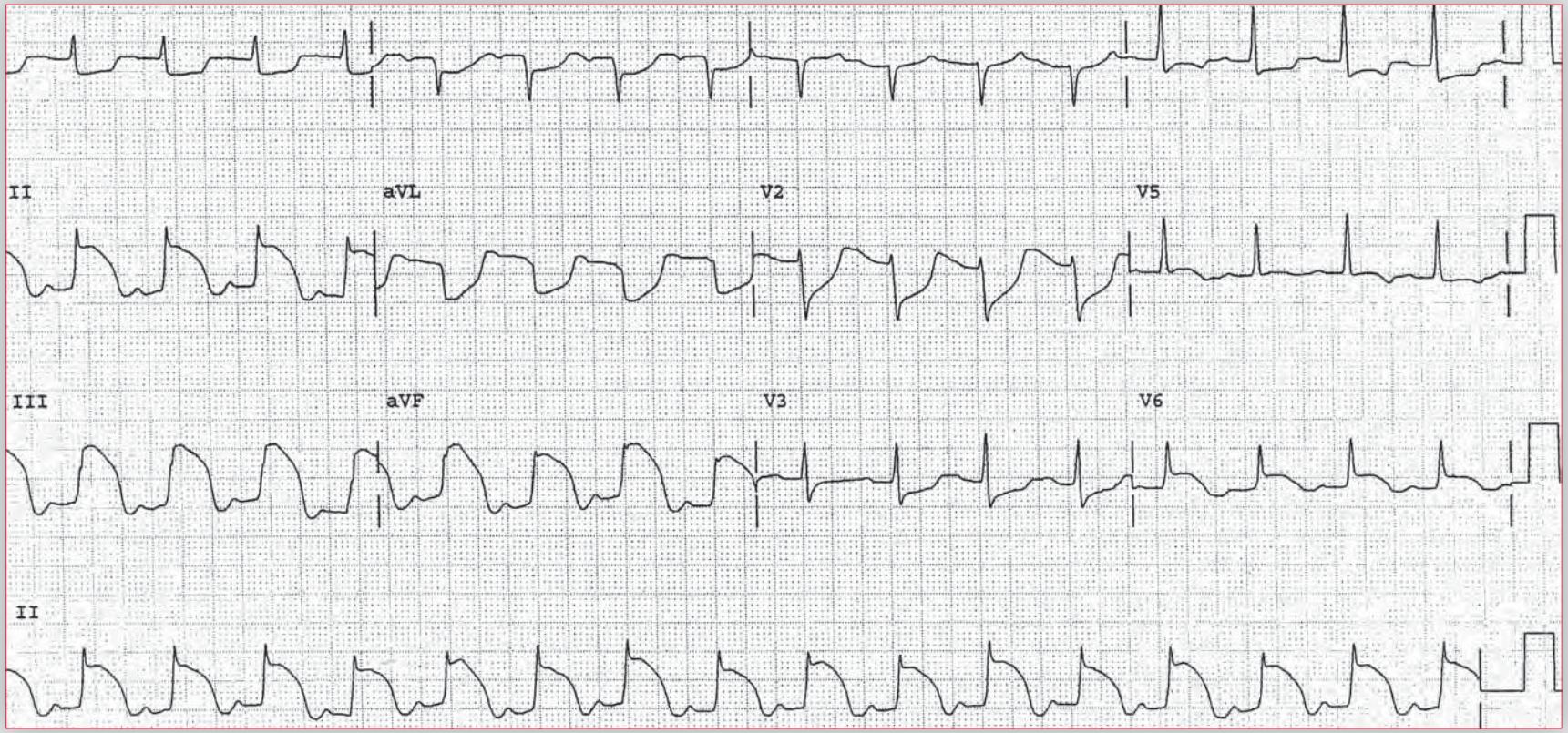

What does the initial ECG (32A) show?

What does the second ECG (32B) show?

What is the likely diagnosis?

ECG 32B

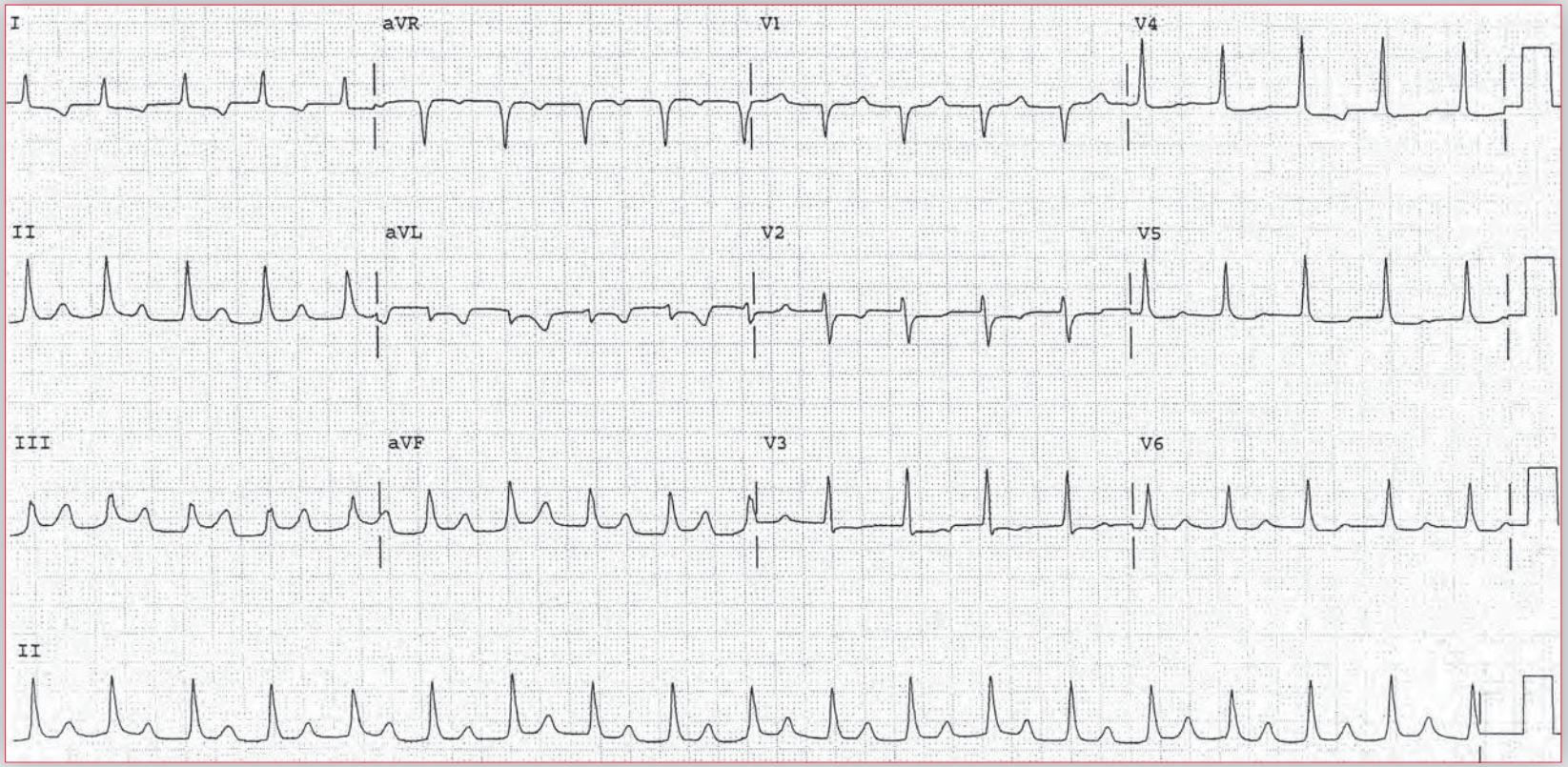

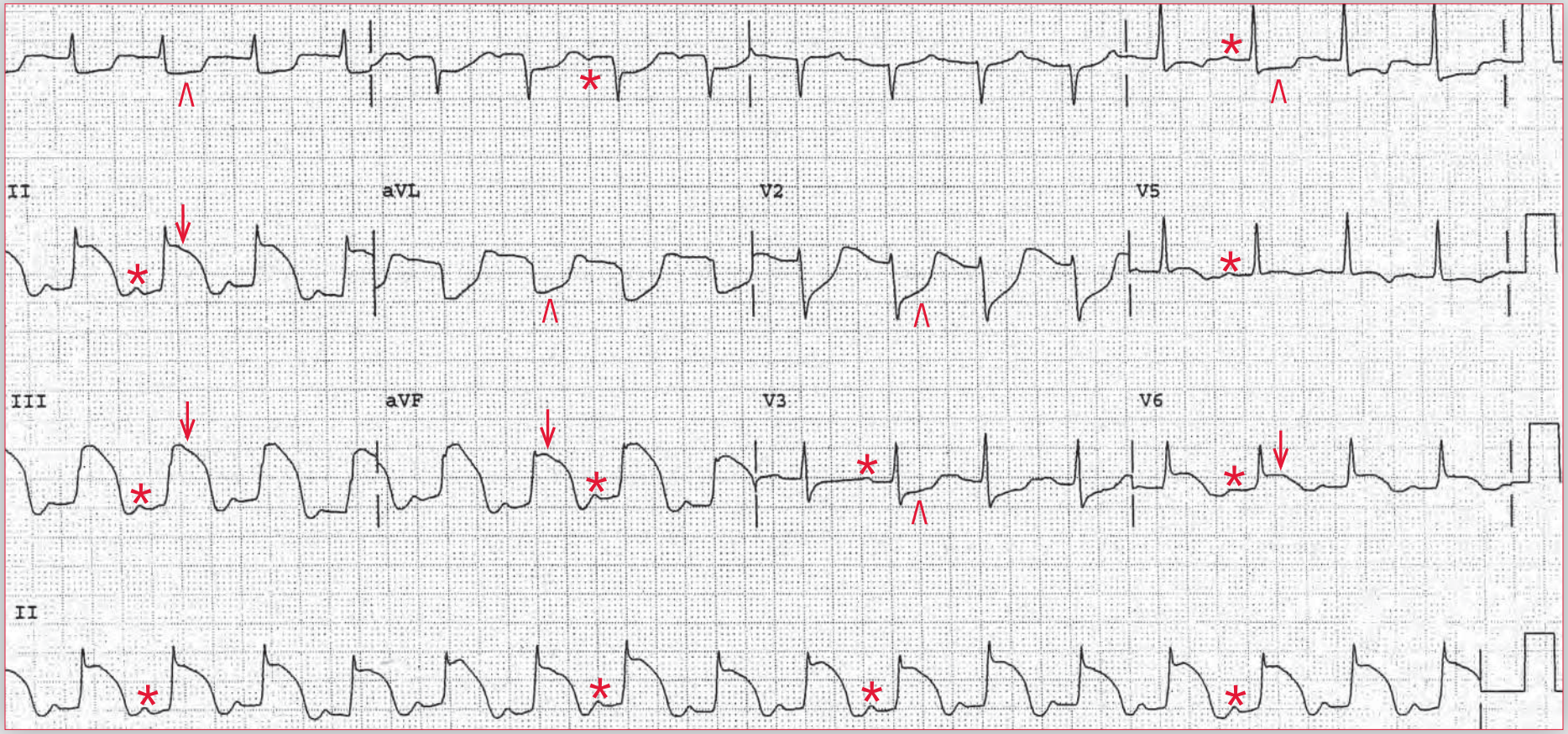

ECG 32A Analysis: Sinus tachycardia, acute inferior wall transmural ischemia due to vasospasm (variant or Prinzmetal's angina), ST-segment alternans

ECG 32A was obtained at 3:38 AM because of the acute-onset substernal chest pressure awakening the patient from sleep. There is a regular rhythm at a rate of 100 bpm, with a P wave (*) before each QRS complex and a stable PR interval (0.16 sec). The P wave is upright in leads II, aVF, and V4-V6 and negative in lead aVR. This is a sinus tachycardia.

The QRS complex duration (0.08 sec) and morphology are normal. The QRS axis is not able to be determined accurately because of very significant ST-segment elevation (↓) in leads II, III, and aVF. ST-segment elevation (↓) can also be seen in lead V6. The ST segments are convex and are merged with the T waves. There is also ST-segment depression (^) in leads I, aVL, and V2-V4. The ECG is typical for an acute inferior wall ST-segment elevation myocardial infarction (STEMI), and the ST-segment depressions are reciprocal changes, although in leads V2-V3 the depressions could represent involvement of the posterior wall of the left ventricle.

Interestingly, there is evidence of ST-segment alternans (*ie*, beat-to-beat changes in the height of the ST segment), best seen in leads aVL and aVF. This has primarily been described with coronary artery vasospasm and transient occlusion of a coronary artery during angioplasty. It is a marker of more severe transmural ischemia.

continues

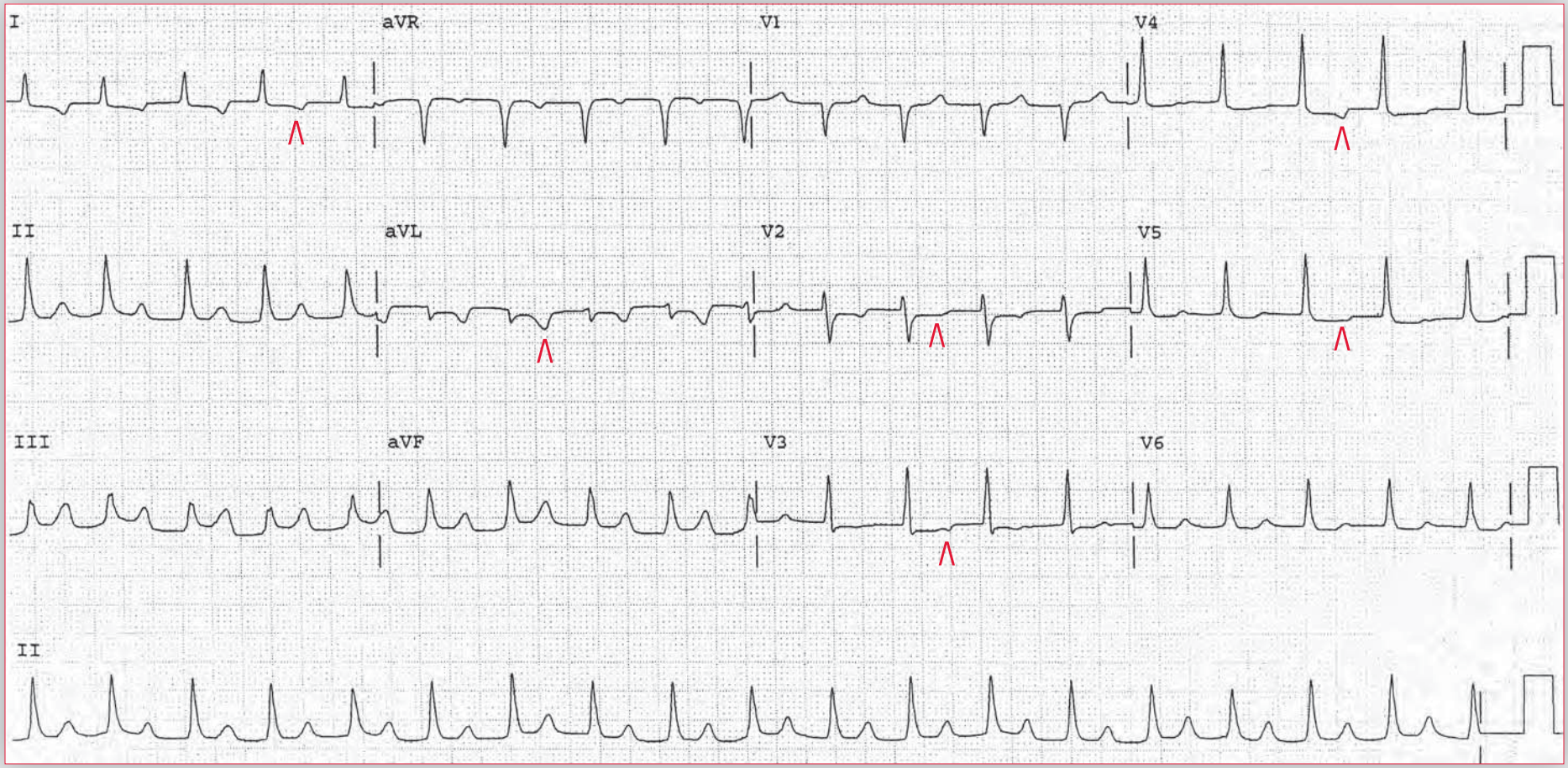

ECG 32B Analysis: Junctional tachycardia

ECG 32B was obtained at 4:00 AM, about 10 minutes after the administration of sublingual nitroglycerin and the relief of the chest discomfort. The rhythm is regular at a rate of 120 bpm. There are no obvious P waves seen before or after any of the QRS complexes, which have a normal duration (0.08 sec) and morphology. This is a junctional tachycardia. The QT/QTc intervals are slightly prolonged (320/450 msec).

The ST-segment elevations and depressions have resolved, and the ST segments are now normal and at baseline (as defined by the T-QRS segment). There are persistent T-wave inversions in leads I, aVL, and V2-V4 (^). Although **ECG 32A** showed evidence of acute transmural ischemia and what appeared to be an acute ST-segment elevation myocardial infarction (STEMI), the rapid resolution of the ECG changes (*ie*, the transmural ischemia) and relief of chest discomfort are characteristic of coronary artery vasospasm, which is termed variant, vasospastic, or Prinzmetal's angina. It results from acute spasm of a coronary artery, which most commonly occurs at night. The right coronary artery is most often involved. The diagnosis of vasospastic or Prinzmetal's angina is based on the presence of ST-segment elevation that is quickly reversed with nitroglycerin. The mechanism for the vasospasm is believed to be based on reflex activation of the sympathetic nervous system and increased α tone due to elevated vagal tone that occurs at night. The stimulation of α receptors in the coronary arteries results in vasospasm of susceptible coronary artery segments.

Although there is transmural ischemia, an acute myocardial infarction is uncommon as local autoregulatory mechanisms often occur, resulting in vasodilation. This may be due to the release of adenosine during ischemia. The initial treatment for vasospastic angina is a calcium-channel blocker and/or nitrates. The vasospasm and transmural ischemia are the same as that which is seen with cocaine-induced vasospasm. ■

Notes

A 22-year-old man with a strong family history of premature coronary artery disease presents to the emergency department with sudden-onset chest heaviness. He has had no prior episodes. He is noted in the emergency department to have several xanthomata on extensor surfaces.

What does his ECG show?

What is the likely diagnosis?

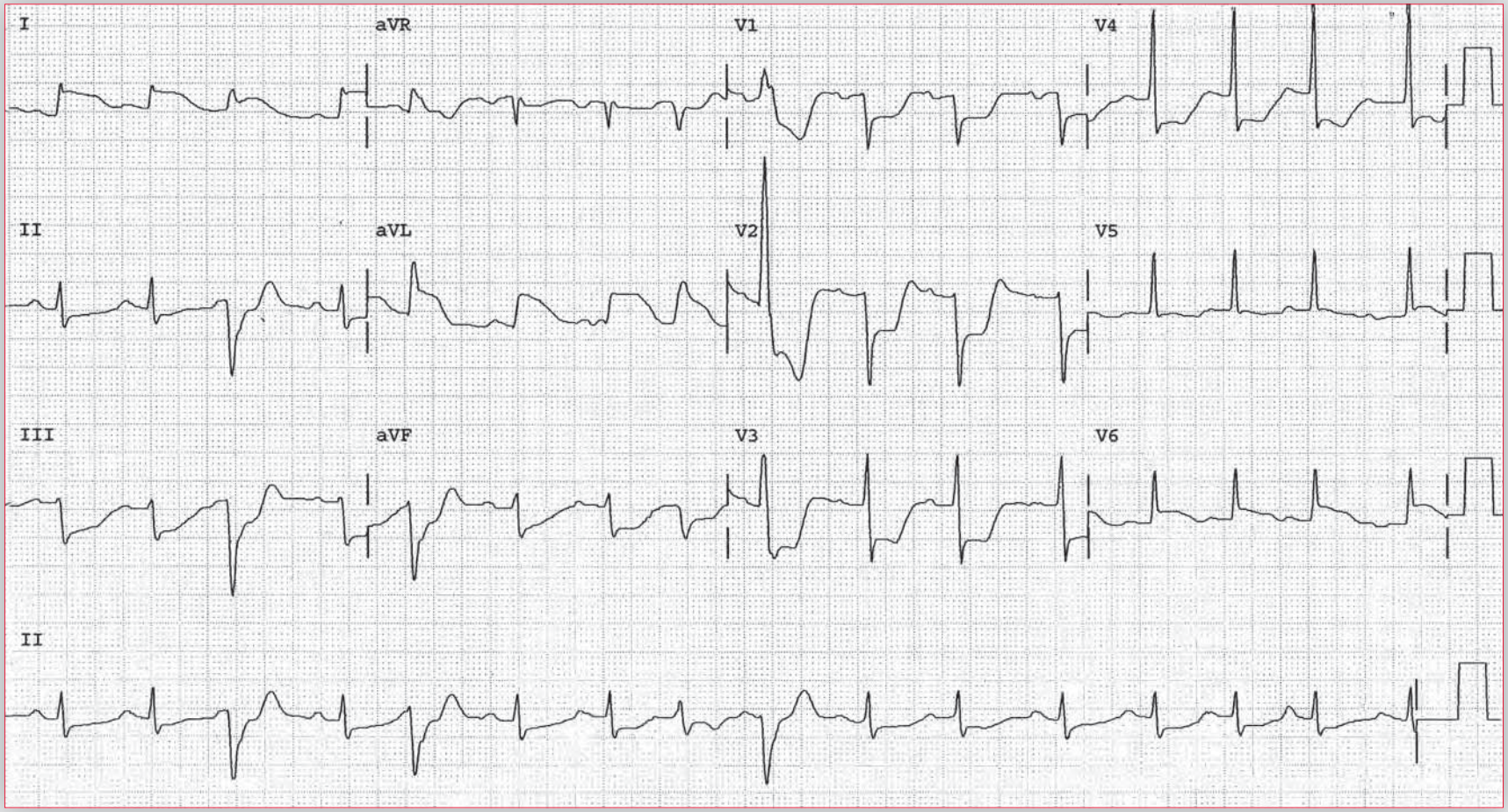

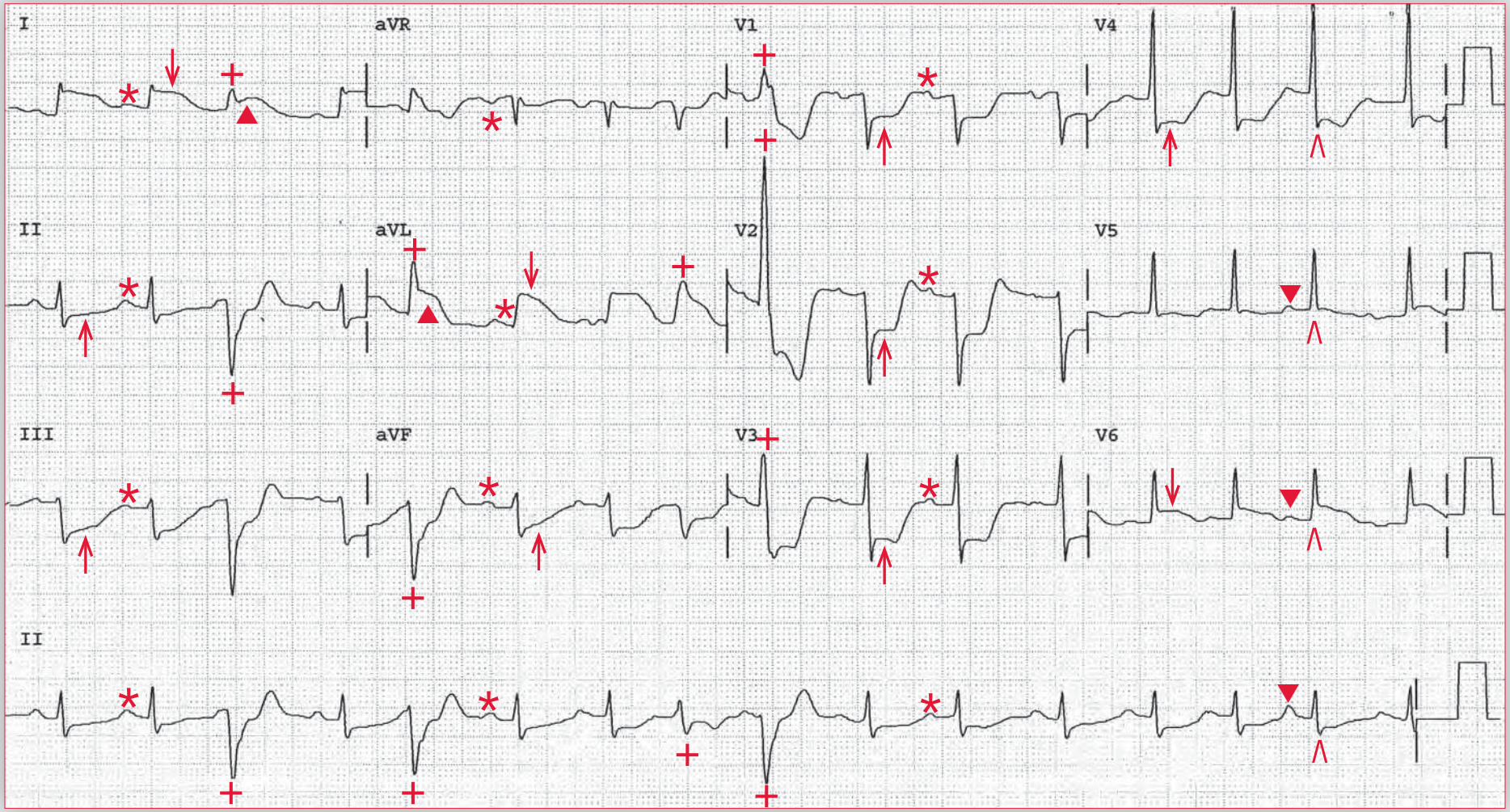

ECG 33 Analysis: Normal sinus rhythm, first-degree AV block, premature ventricular complexes, premature atrial complex, acute lateral wall ST-segment elevation myocardial infarction (STEMI)

There is a regular rhythm at a rate of 90 bpm. There is a P wave (*) before each QRS complex, with a stable PR interval (0.22 sec). The P wave is upright in leads I, II, aVF, and V4-V6 and negative in lead aVR. This is a normal sinus rhythm with a first-degree AV block. There are four wide QRS complexes (third, fifth, eighth, and ninth) (+) that are not preceded by a P wave and have an abnormal morphology. These are premature ventricular complexes. In addition, the 15th QRS complex (^) is early. There is a P wave of a different morphology (▼) preceding it, and the QRS complex morphology is the same as the sinus complexes. This is a premature atrial complex.

The sinus QRS complex duration is normal (0.10 sec). There is ST-segment elevation (↓) in leads I, aVL, and V6, and the ST segments have a convex morphology, merging with the T waves. This is an acute lateral wall ST-segment elevation myocardial infarction (STEMI). There is also significant ST-segment depression (↑) in leads II, III, aVF, and V1-V4; these are reciprocal changes. The premature ventricular complex in leads I and aVL also has ST-segment elevation (▲), indicating that evidence of an acute STEMI can be identified in QRS complexes that are generated by direct activation of the ventricular myocardium, bypassing the normal His-Purkinje pathway (*ie*, ventricular complexes, paced complexes, or supraventricular complexes with a left bundle branch block). This is based on the Sgarbossa criteria.

Sgarbossa Criteria for Acute Myocardial Infarction in Left Bundle Branch Block (and Paced Rhythm and Ventricular Complex)

Criterion	Score
ST-segment elevation ≥ 1 mm that is in the same direction (concordant) as the QRS complex in any lead	5
ST-segment depression ≥ 1 mm in any lead from V1 to V3	3
ST-segment elevation ≥ 5 mm that is discordant with the QRS complex (*ie*, associated with a QS or rS complex)	2

A minimum score of 3 is required for a specificity of 90%.

MI is quite rare in this age group, raising the possibility of an unusual etiology. MI in the young can be related to vasculitis (such as Kawasaki's disease), chronic inflammatory states, coronary dissection, coronary artery embolism from endocarditis or atrial fibrillation, or accelerated atherosclerosis from an inherited dyslipidemia. This young man with a strong family history of coronary disease and physical exam notable for xanthomata likely has an inherited dyslipidemia. The most common of these, familial hypercholesterolemia, is a monogenic, autosomal disorder caused by a defect in the low-density lipoprotein (LDL) receptor. Patients who harbor the homozygous form of the disease often present with MI during the second or third decade of life. Patients require very aggressive cholesterol-lowering therapy with high-dose statins, inhibitors of cholesterol absorption, and often apheresis. ■

Notes

A 55-year-old man with diabetes presents to a walk-in clinic for evaluation of 1 week of increased dyspnea on exertion. He does not recall any episodes of prolonged chest pain but decided to seek medical attention when the dyspnea persisted for more than a week. Prior to this episode he was in good physical condition and able to complete his work as a mail carrier without difficulty, but recently he has had trouble walking his route.

What does his ECG show?

What is the likely diagnosis?

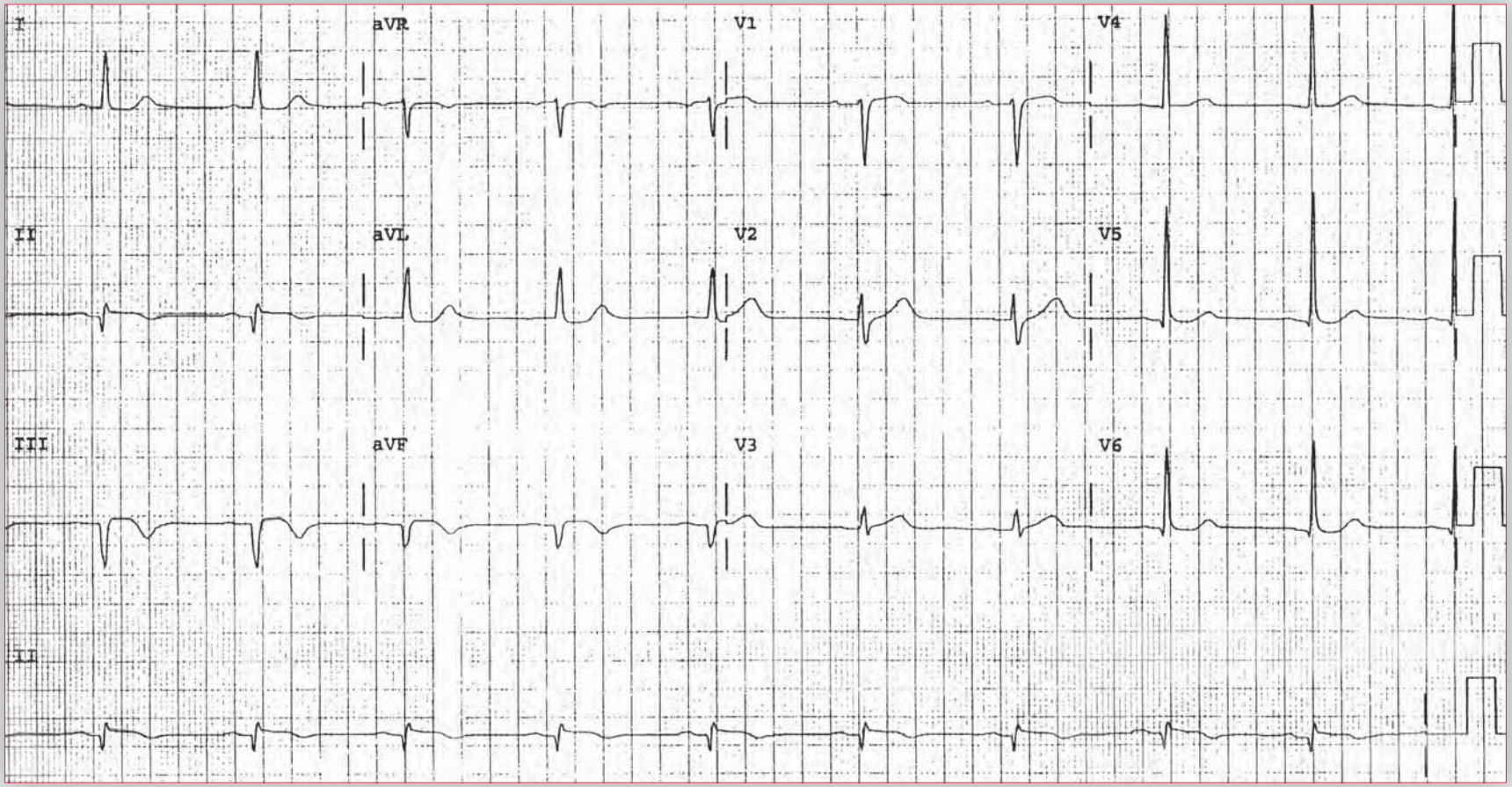

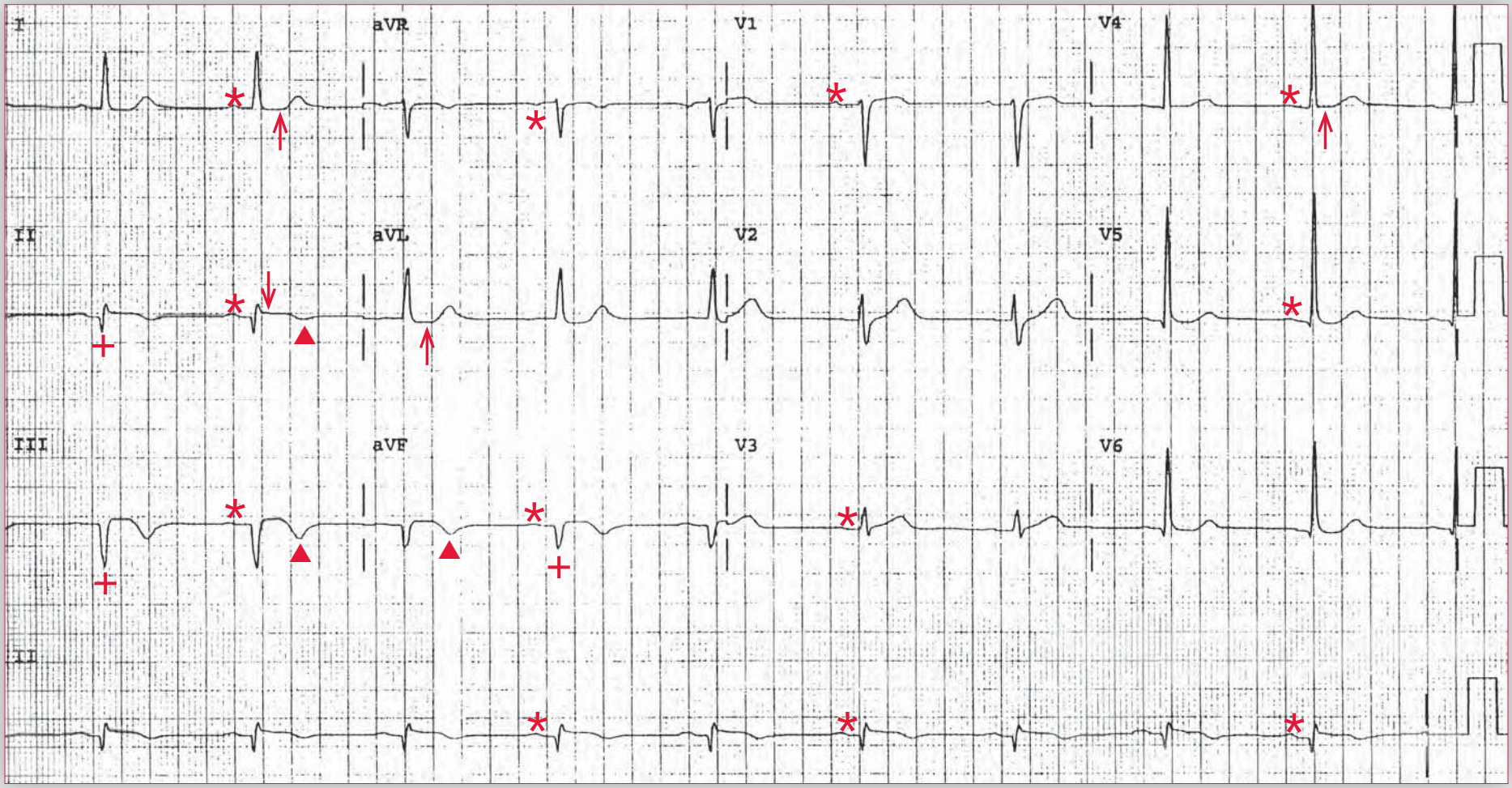

ECG 34 Analysis: Normal sinus rhythm, old inferior wall myocardial infarction (MI), nonspecific ST-segment changes, left axis deviation due to an old inferior wall MI

There is a regular rhythm at a rate of 58 bpm. There is a P wave (*) before each QRS complex, and the PR interval is stable (0.16 sec). The P wave is positive in leads I, II, aVF, and V4-V6 and negative in lead aVR. The P-wave morphology is normal. This is a normal sinus rhythm.

The QRS duration is normal (0.08 sec), as is the morphology. Although the axis appears to be extremely leftward due to a negative QRS complex in leads II and aVF and a positive QRS complex in lead I (*ie*, axis between –30° and –90°), this is a result of deep Q waves (+) in leads II and aVF. This, along with the Q wave in lead III (+), is diagnostic for an inferior wall myocardial infarction (MI). Hence the left axis deviation is not the result of a conduction abnormality (*ie*, it is not a left anterior fascicular block in which the QRS complex has an rS morphology) but of an inferior wall MI (*ie*, it has a Qr morphology). The QT/QTc intervals are normal (400/390 msec).

There is minor ST-segment elevation (↓) and T-wave inversion (▲) in leads II, III, and aVF, suggesting that the inferior wall MI may have been relatively recent (within the past few days or weeks). ST-segment flattening (↑) is also noted in leads I, aVL, and V4, which is a nonspecific abnormality.

A chronic or old MI is identified by the presence of abnormal Q waves, defined as any Q wave in leads V1-V3 or a Q wave 0.04 second or longer in leads I, II, aVF, or V4-V6 (in two or more contiguous leads) and at least 1 mm in depth. However, Q waves may be normal and are ignored in lead III (unless they are also in leads II and aVF), in lead V1 (unless also in lead V2), and in lead aVL (unless Q-wave height ≥ 50% R-wave height). The QS interval in leads V1-V2 may also be normal variant.

T-wave inversions are usually present in the leads showing Q waves. Persistent ST-segment elevation weeks, months, or years after an infarction suggests the presence of an aneurysm. The location of Q waves identifies the region of the left ventricle that is involved:

- Inferior wall MI: Q waves in leads II, III, and aVF
- Anteroseptal MI: Q waves in leads V1-V2
- Anteroapical MI: Q waves in leads V3-V4
- Anterolateral MI: Q waves leads V5-V6
- Anterior wall MI: Q waves in two or more contiguous precordial leads
- Lateral MI: Q waves in leads I and aVL

continues

- Posterior MI: Tall R wave in lead V1 (R-wave amplitude > 7 mm or R/S > 1) with a duration 0.04 second or longer. This is typically seen in association with inferior wall MI and in the absence of other conditions associated with a tall R wave in lead V1, including evidence of right ventricular hypertrophy, Wolff-Parkinson-White pattern, dextrocardia, lead misplacement, recording of right-sided leads, Duchenne muscular dystrophy, or hypertrophic cardiomyopathy. On occasion it may be a normal variant or due to counterclockwise rotation.

Although the patient does not give a history of a prior MI, silent infarctions are not uncommon and up to 40% may go unrecognized, especially those of the inferior wall. This may be seen even more frequently in patients with diabetes, who often do not have typical symptoms of an MI. They may have other symptoms, such as fatigue, shortness of breath, nausea, and diaphoresis, which may often be overlooked or not considered to be of any importance. Given the presenting symptoms, it is likely that the patient has developed signs and symptoms of heart failure as a result of significant left ventricular myocardial dysfunction due to the previous infarction. It is also possible that the patient may have mitral regurgitation as a result of papillary muscle dysfunction from a previous MI. ■

An 88-year-old man with insulin-dependent diabetes, hypertension, and a 60 pack-year smoking history presents to his primary care physician with dyspnea on exertion and a 10-pound weight gain. On exam, he has evidence of jugular venous distention, bilateral rales, and pedal edema. Echocardiography documents multiple wall motion abnormalities with areas of akinesis and a left ventricular ejection fraction of 25%.

What does his ECG show?

What is the likely diagnosis?

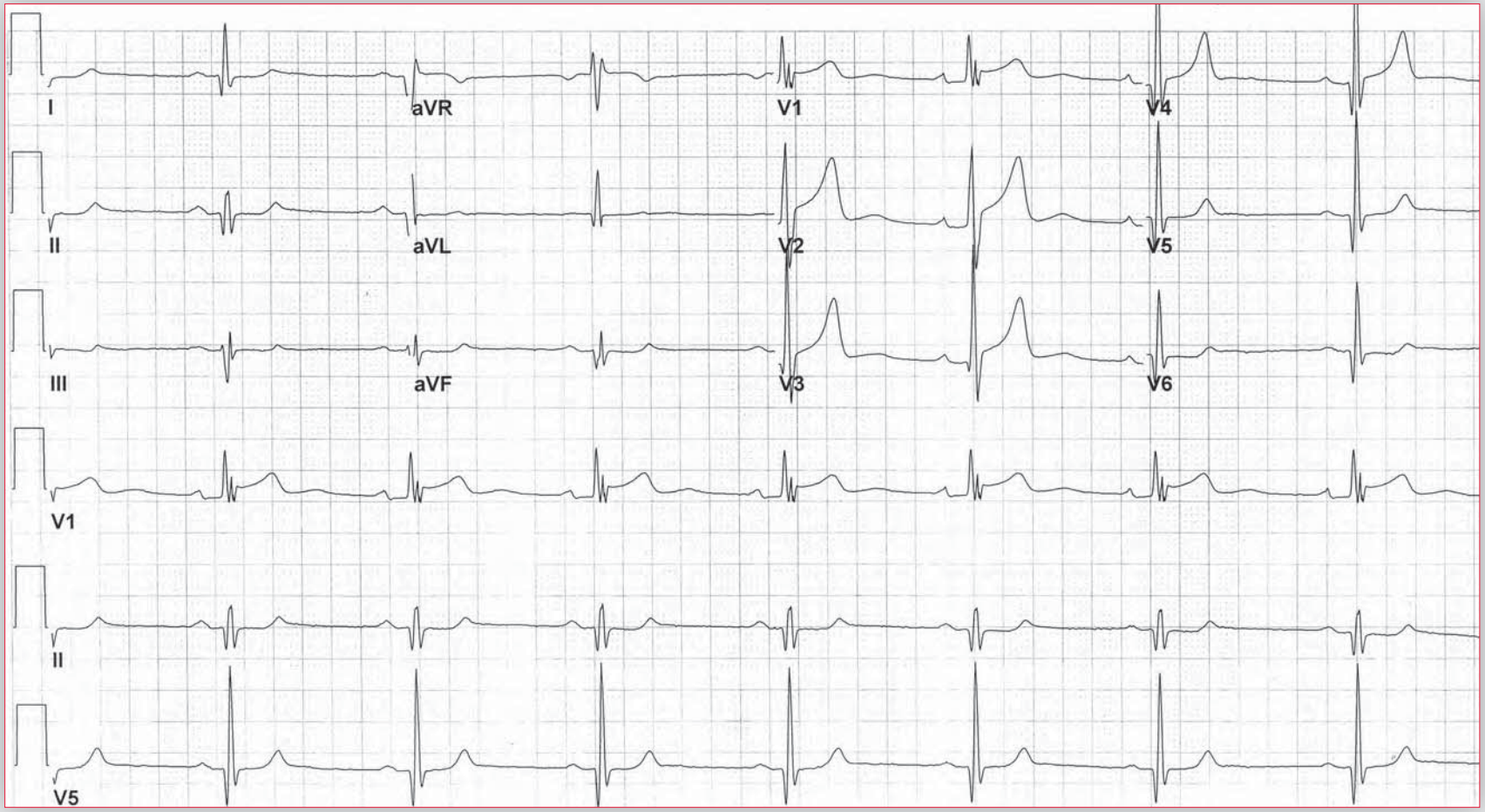

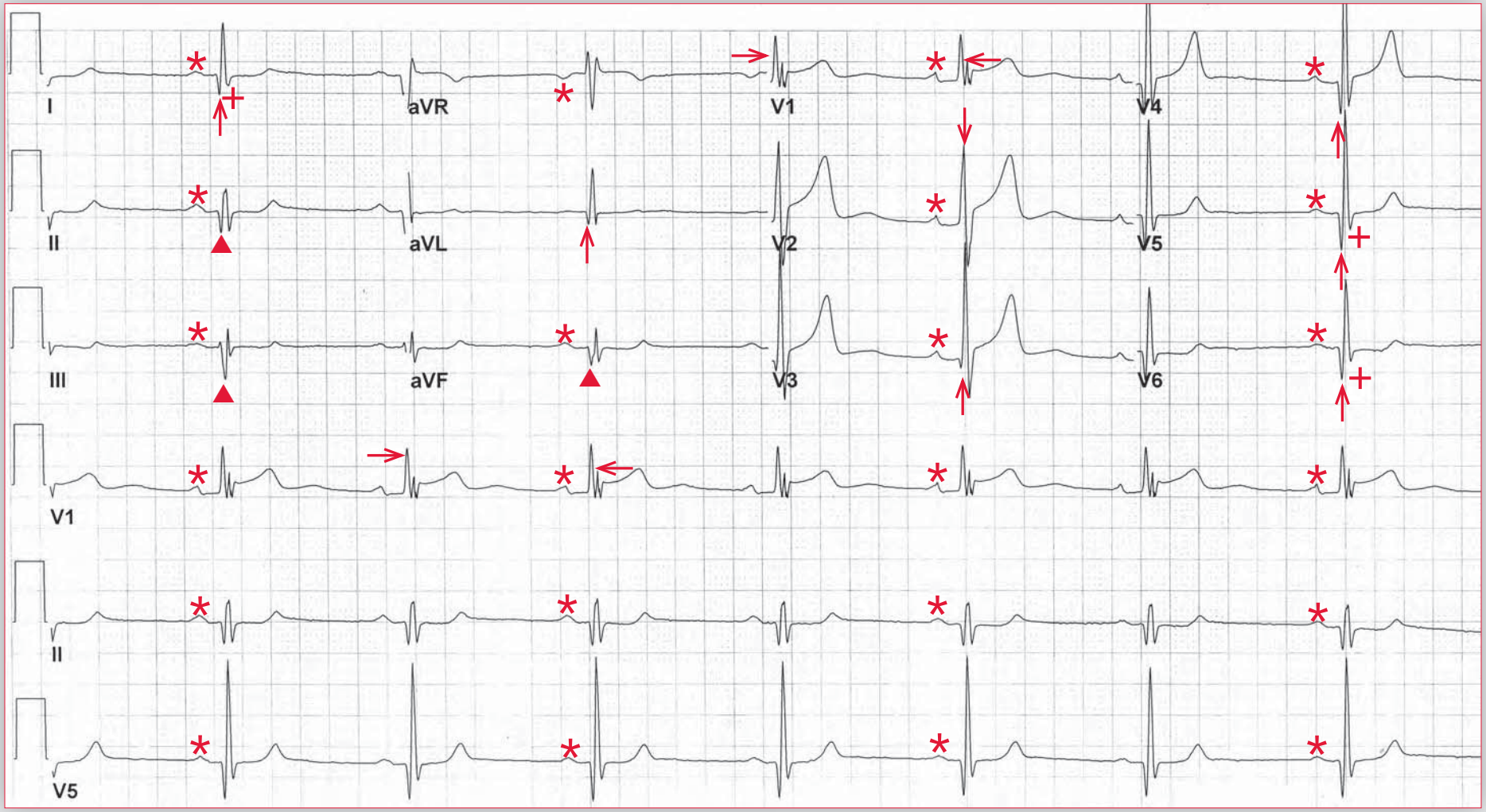

ECG 35 Analysis: Sinus bradycardia; first-degree AV block; intraventricular conduction delay; old lateral, anteroapical, and anterolateral myocardial infarction (MI); old inferior wall MI; old posterior wall MI; counterclockwise rotation (early transition)

There is a regular rhythm at a rate of 46 bpm. There is a P wave (*) before each QRS complex, with a stable PR interval (0.22 sec). The P-wave morphology is normal. This is a normal sinus rhythm with a first-degree AV block.

The QRS complex duration is slightly prolonged (0.11 sec), and there appears to be a delay in right ventricular conduction as there is an R′ (←) in lead V1 and prominent S waves (+) in leads I and V5-V6. This is an intraventricular conduction delay. The axis is normal, between 0° and +90° (positive QRS complex in leads I and aVF). The QT/QTc intervals are normal (460/400 msec and 430/380 when corrected for the prolonged QRS complex duration).

There are significant Q waves (↑) in leads I, aVL, and V3-V6, diagnostic for an old lateral, anteroapical, and anterolateral myocardial infarction (MI). There are also significant Q waves (▲) in leads II, III, and aVF, diagnostic for an old inferior wall MI. Lastly, there is a tall R wave (→) in lead V1; along with the inferior wall MI this indicates an old posterior wall MI. The tall R wave in lead V2 (↓), along with the tall R wave in lead V1, may also be due to the posterior wall MI. However, it may also be the result of counterclockwise rotation or early transition. This is due to a shift of the electrical axis in the horizontal plane and is established by imagining the heart as viewed from under the diaphragm. When the electrical axis is shifted in a counterclockwise direction, left ventricular forces occur early and are prominent in the right precordial leads (*ie*, a tall R wave in lead V2). There is ST-segment elevation in leads V1-V3. The etiology for this is not certain. It may actually represent ST-segment depression seen in posterior leads V7-V8 or early repolarization.

This patient has suffered multiple prior MIs involving several territories. As a result, there is a significant decline in systolic function resulting in heart failure. There is no evidence of active myocardial ischemia on the ECG, so clinical care should focus on medical therapy for heart failure, including diuresis to achieve euvolemia, afterload reduction with an angiotensin-converting enzyme inhibitor, and long-acting β-blockade. It has been proposed that establishing the presence of a viable hibernating myocardium in patients with an ischemic cardiomyopathy is important and that revascularization would help improve left ventricular function if there is substantial viable myocardium. However, a recent study (STICH) has reported that this approach does not lead to any improvement in outcome when compared with medical therapy and that establishing hibernation with imaging does not help. In this patient, there are multiple areas of infarction with fibrosis and akinesis that will not recover with revascularization. ■

Notes

A 56-year-old woman presents to a cardiologist for evaluation of exertional chest pressure. Over the course of the previous 3 weeks, the intensity and frequency of the chest discomfort have increased. She reports that she had a myocardial infarction about 3 years earlier. Her cardiologist diagnoses unstable angina on a clinical basis and arranges for her to undergo urgent coronary angiography. He performs an ECG in his office. On angiography she is found to have a chronic total occlusion of her right coronary artery with left-to-right collaterals to the posterior descending artery and an 80% mid-circumflex stenosis.

What does the ECG show?

Which lesion is likely to be responsible for her angina?

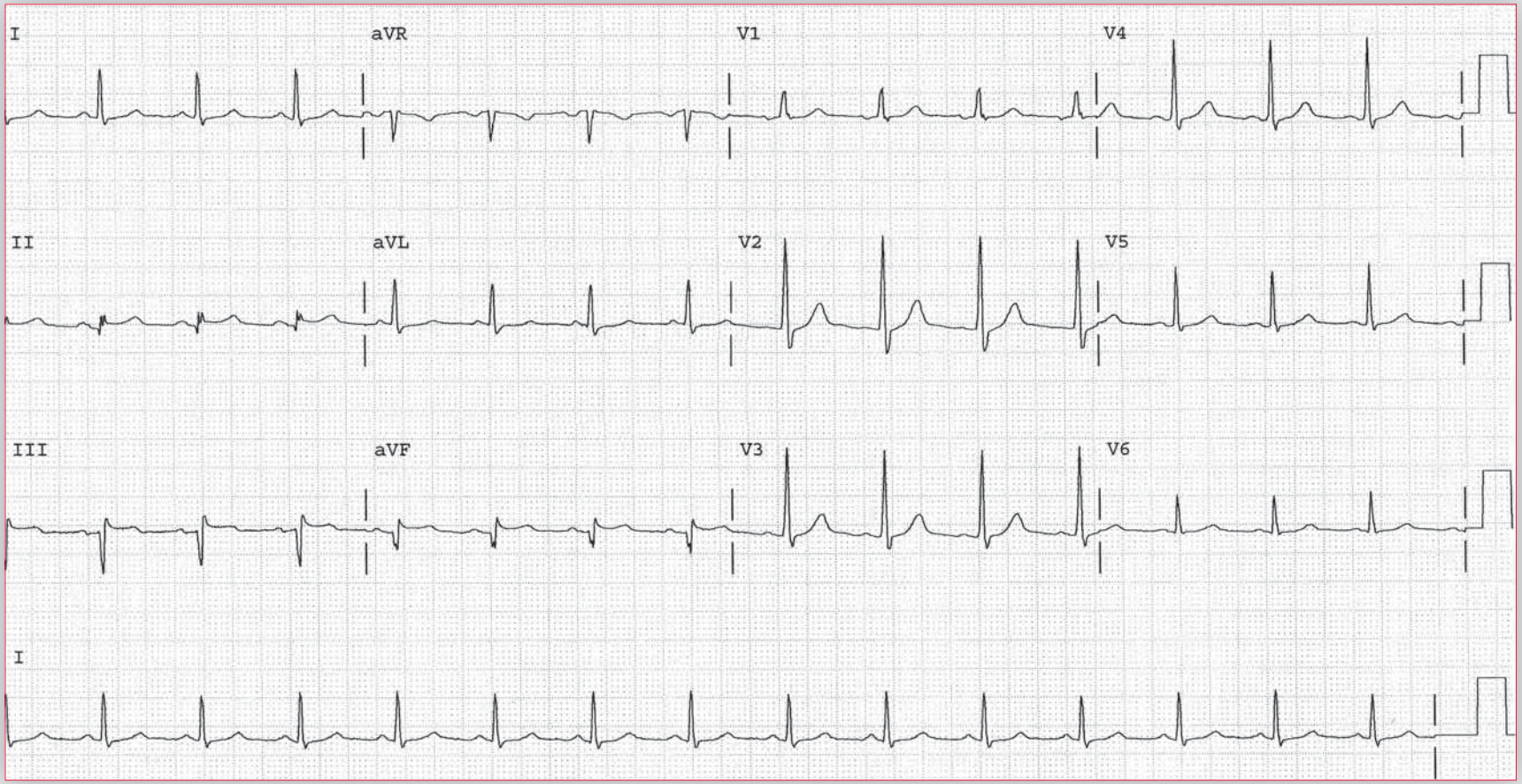

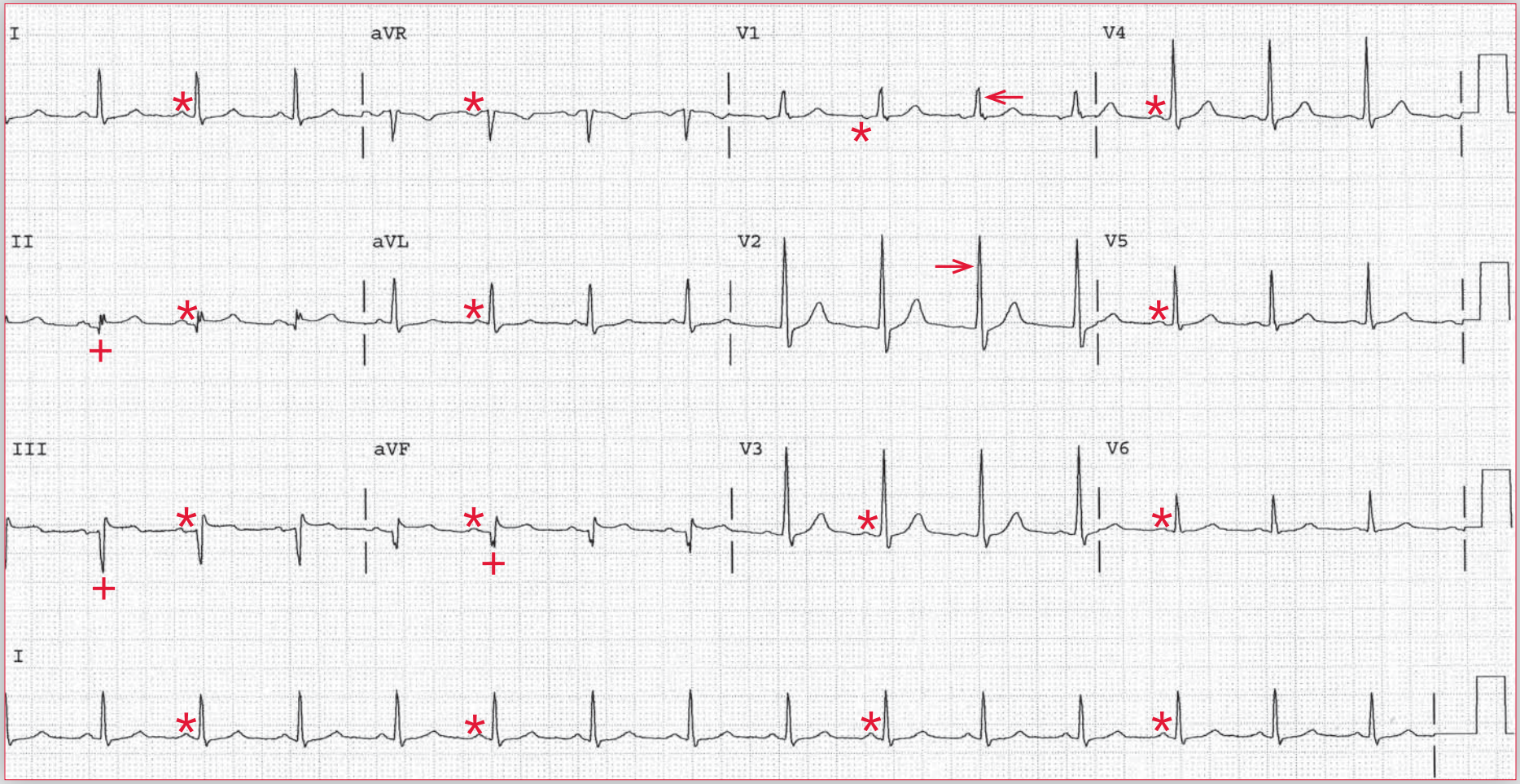

ECG 36 Analysis: Normal sinus rhythm, old inferior wall myocardial infarction (MI), old posterior wall MI, counterclockwise rotation (early transition)

There is a regular rhythm at a rate of 90 bpm. There is a P wave (*) before each QRS complex, with a stable PR interval (0.15 sec). The P wave is positive in leads I, II, aVF, and V4-V6 and negative in lead aVR. This is a normal sinus rhythm.

The QRS duration is normal (0.08 sec). The QT/QTc intervals are normal (320/390 msec). Although the axis is leftward (between 0° and –30°), this is the result of significant Q waves (+) in leads II, III, and aVF, diagnostic for an inferior wall myocardial infarction (MI). In addition, there is a tall R wave in lead V1 (←), which, along with an inferior wall MI, is characteristic of posterior wall involvement with the infarction; hence this is an inferoposterior wall MI. The tall R wave in lead V2 (→) is probably the result of counterclockwise rotation or early transition. This is due to a shift of the electrical axis in the horizontal plane and is established by imagining the heart as viewed from under the diaphragm. When the electrical axis is shifted in a counterclockwise direction, left ventricular forces occur early and are prominent in the right precordial leads (*ie*, a tall R wave in lead V2).

The old inferoposterior MI on the ECG corresponds with the finding of an occluded right coronary artery on angiography. It is likely that her unstable angina is attributable to the stenosis of the mid-circumflex artery. Not uncommonly, lesions of the left circumflex artery are electrically silent and there are no acute ECG changes seen with either ischemia or acute MI. Percutaneous coronary intervention of the circumflex artery is indicated. It has been shown that there is no benefit to opening a chronically occluded artery. Hence there would be no reason to perform a percutaneous coronary intervention of the right coronary artery, especially since there are left-to-right collaterals to the distal right coronary artery and posterior descending artery. ■

Notes

An 81-year-old woman is transferred from the coronary care unit to a cardiac step-down unit 1 week after suffering a large myocardial infarction (MI) complicated by hypotension and vascular congestion. She is currently feeling well and is pain free. She denies any lightheadedness or pre-syncope.

What does her ECG show?

What is the likely diagnosis?

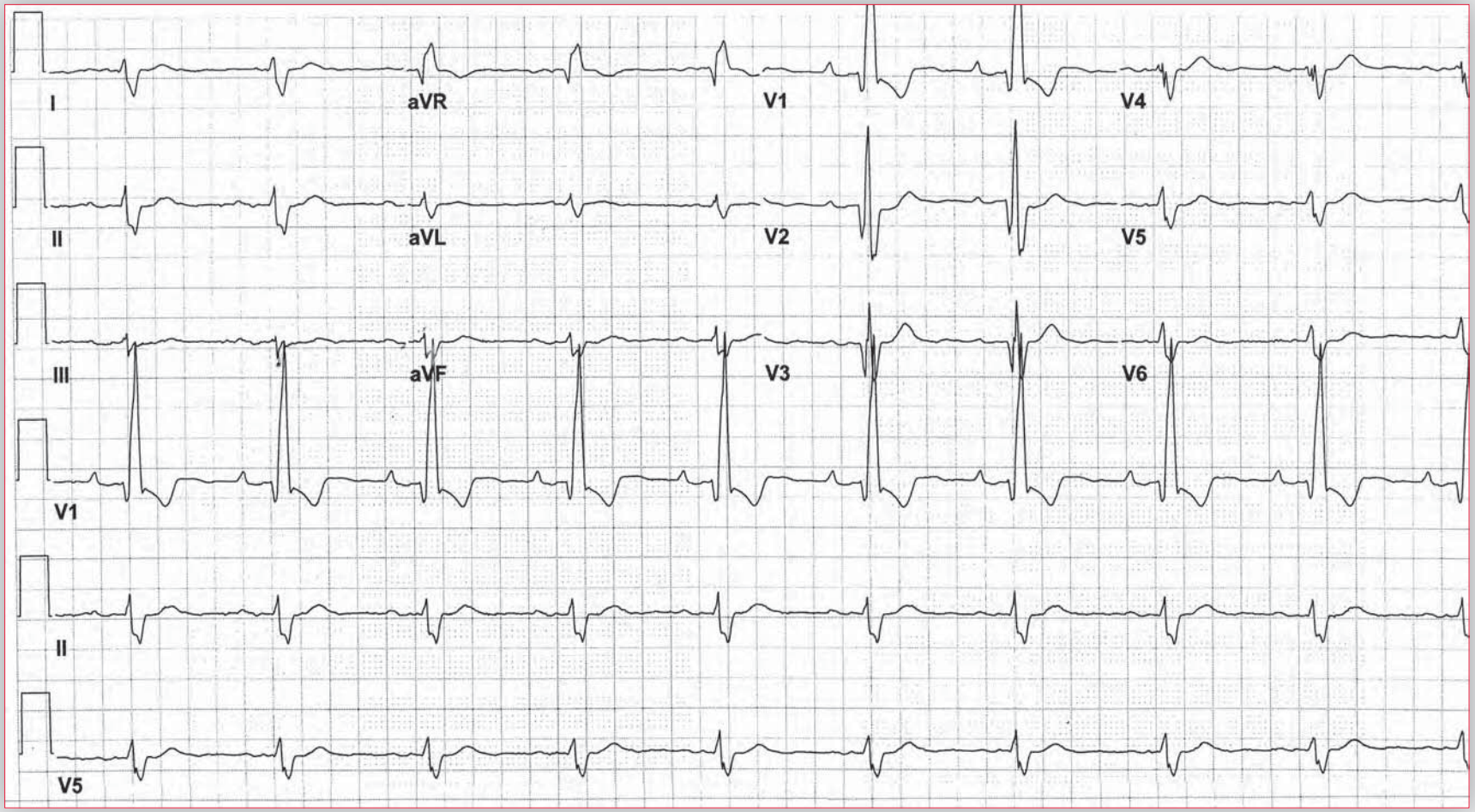

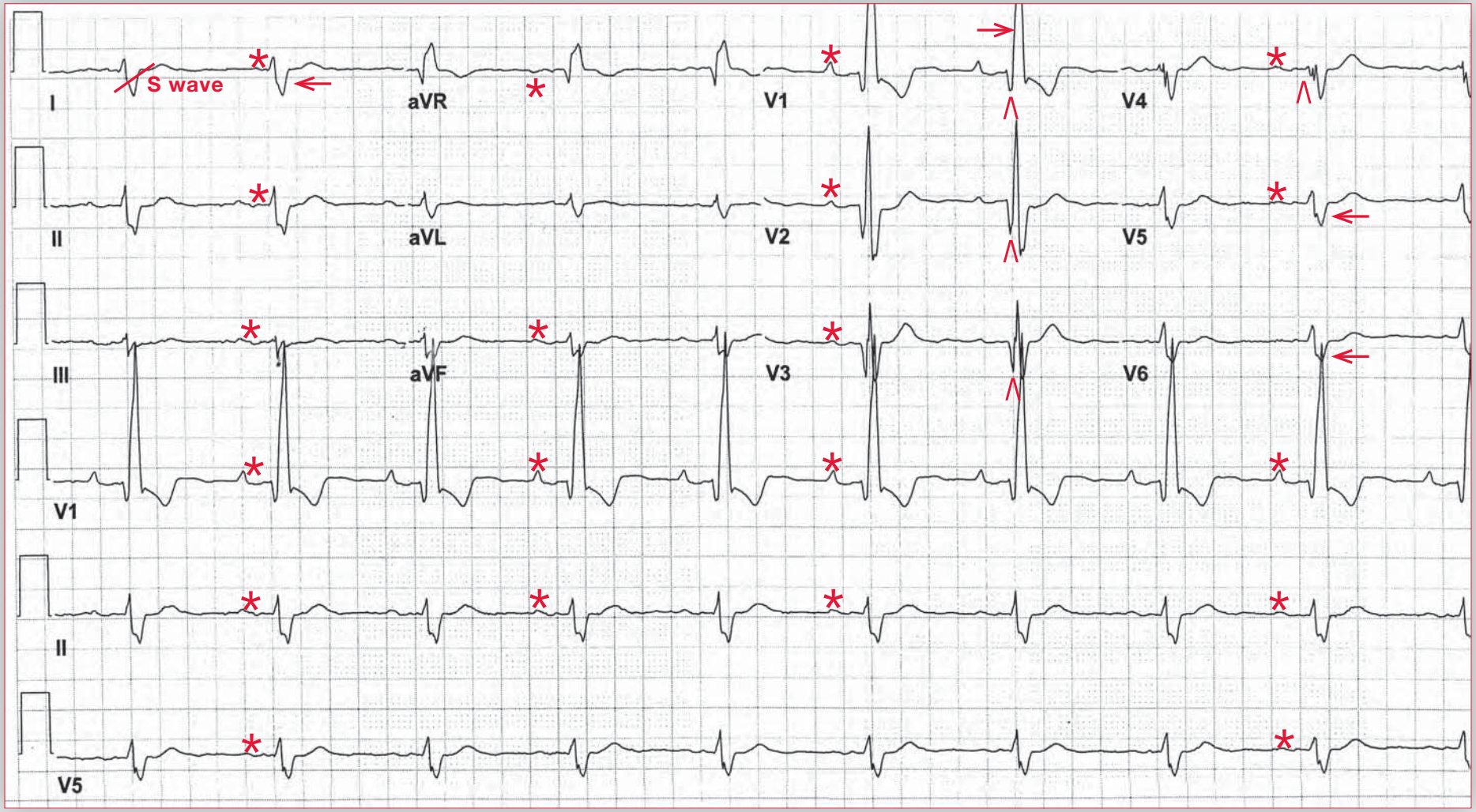

ECG 37 Analysis: Normal sinus rhythm, first-degree AV block, right bundle branch block, left anterior fascicular block (bifascicular block), old anteroseptal and anteroapical MI

There is a regular rhythm at a rate of 60 bpm. There is a P wave (*) before each QRS complex, with a stable PR interval (0.24 sec). The P wave is upright in leads I, II, aVF, and V4-V6 and negative in lead aVR. This is a normal sinus rhythm with a first-degree AV block.

The QRS complex duration is prolonged (0.14 sec), and the morphology has a right bundle branch block pattern with a broad S wave (←) in leads I and V5-V6 and a tall, broad R wave in lead V1 (→). The axis is extremely leftward, between –30° and –90° (positive QRS complex in lead I after eliminating the terminal S wave, which is the result of a right bundle branch block and delayed right ventricular activation, and negative QRS complex in leads II and aVF). This is termed a left anterior fascicular block. It should be noted that the broad S wave in lead I caused by the right bundle branch block gives the appearance that the QRS complex is negative in this lead; if this actually were a negative QRS complex, this would be an indeterminate axis. However, the S wave should not be considered as part of axis determination and, when eliminated, the QRS complex is indeed positive. The presence of a right bundle branch block and left anterior fascicular block is termed bifascicular block. There is also a first-degree AV block, and this has often been thought to represent trifascicular disease or block. However, this is not correct unless the etiology for the first-degree AV block is known to be the result of conduction slowing in the remaining fascicle (*ie*, left posterior fascicle). However, the first-degree AV block may also be due to slow conduction through the AV node, in which case this would be bifascicular block associated with AV nodal conduction slowing. The QT/QTc intervals are normal (440/440 msec and 380/380 when corrected for the prolonged QRS complex duration).

There are significant Q waves in leads V1-V4 (^), diagnostic for an anteroseptal and anteroapical myocardial infarction (MI). The left anterior fascicle and most of the fibers of the right bundle branch are supplied by the septal perforators of the left anterior descending artery. Therefore, an anteroseptal MI resulting in myocardial fibrosis can lead to a bifascicular block. This degree of conduction disease following MI is an indicator of an extensive amount of infarcted tissue and is a poor prognostic factor. In the absence of symptoms, this degree of conduction disease is not an indication for permanent cardiac pacing, although the clinician must remain vigilant for signs of high-grade heart block. ■

Notes

A 48-year-old man is transferred from a rural health clinic to an emergency department at a tertiary care center for evaluation of chest pain. The patient had been on a week-long hunting trip with his friends when he developed chest discomfort. The discomfort persisted for about an hour and eventually resolved partially with rest. He had continued intermittent chest discomfort for the next 48 hours and eventually decided to leave his hunting troop and seek medical attention. Upon arrival at a local medical clinic, he has continued to complain of 1/10 chest discomfort. An ECG is obtained.

What does his ECG show?

What is the likely diagnosis?

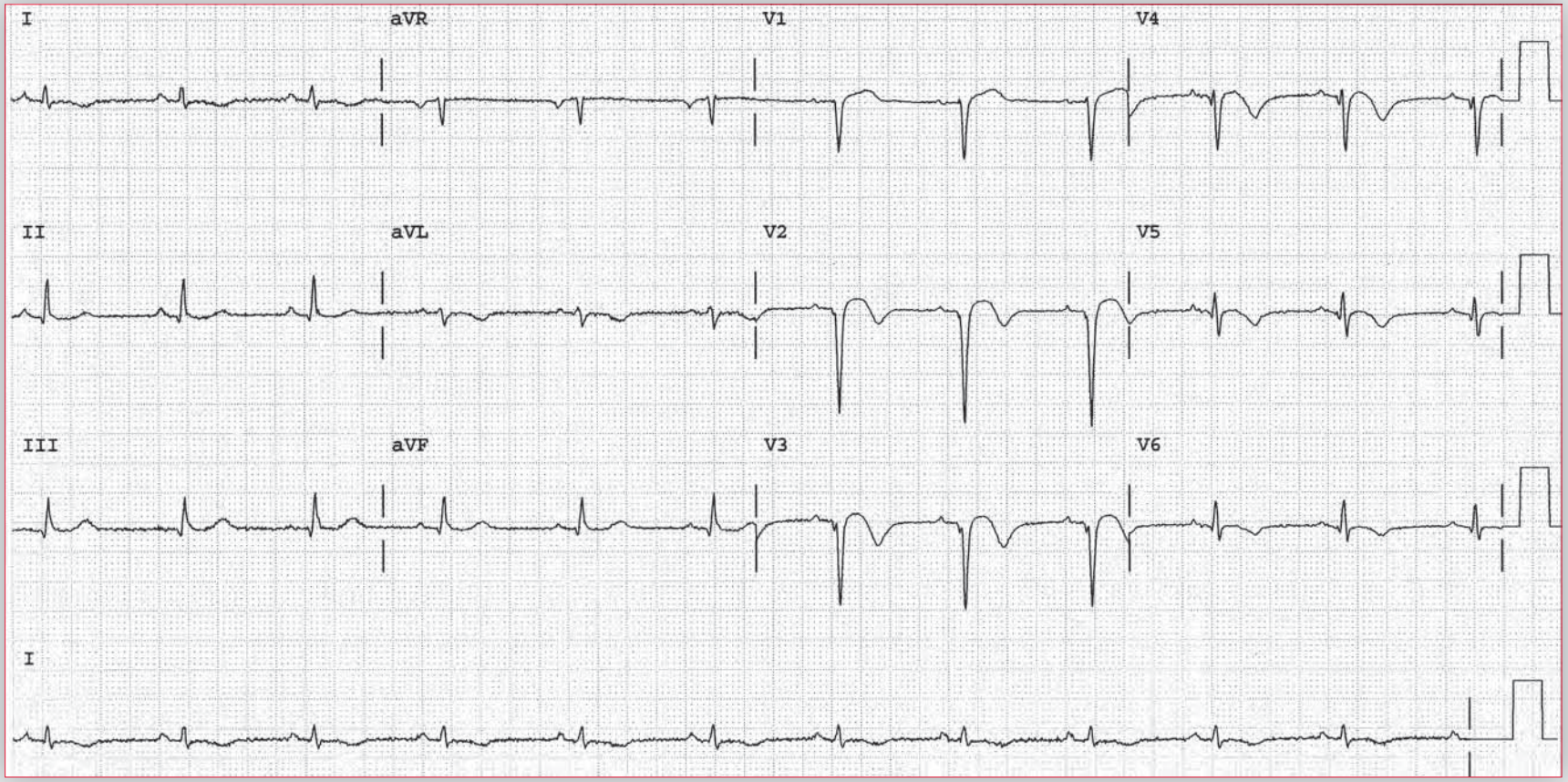

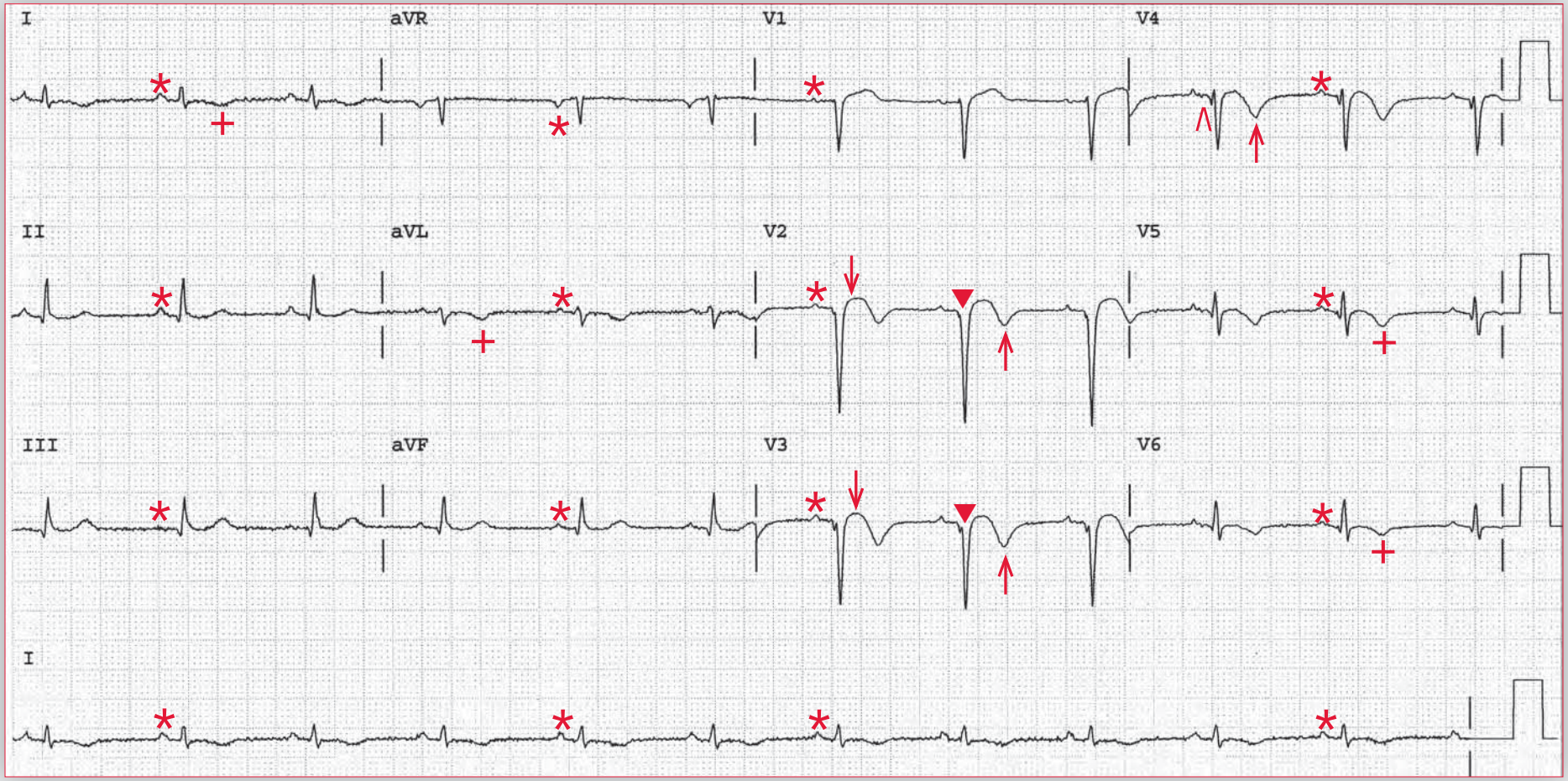

ECG 38 Analysis: Normal sinus rhythm, anteroapical myocardial infarction (MI) (age indeterminate), anteroapical aneurysm versus MI in evolution, nonspecific T-wave abnormalities

There is a regular rhythm at a rate of 68 bpm. There is a P wave (*) before each QRS complex, with a stable PR interval (0.16 sec). The P wave is positive in leads I, II, aVF, and V4-V6 and negative in lead aVR. The P-wave morphology is normal. This is a normal sinus rhythm.

The QRS complex duration is normal (0.08 sec), and there is a normal axis, between 0° and +90° (positive QRS complex in leads I and aVF). The QT/QTc intervals are normal (400/430 msec). There are Q waves (▼) (QS complexes) in leads V2-V3 and an initial Q wave in lead V4 (^), diagnostic for an anteroapical myocardial infarction (MI). In addition, there are T-wave inversions (↑) in these leads as well as in leads I, aVL, and V5-V6 that are nonspecific. There is minimal ST-segment elevation (↓) in leads V2-V3. This might be indicative of a recent MI with ongoing evolution of the ECG changes or an old infarction with the presence of an aneurysm of the infarcted area.

In this clinical setting (*ie*, the acute onset of symptoms about 1 week before being seen), the ECG findings likely represent an evolving MI. Since the patient presented late into his course, his ECG shows evidence of transmural myocardial necrosis. His ongoing chest discomfort may be evidence of some persistent ischemia in the remaining viable tissue. He is at high risk for mechanical complications of MI, including free wall rupture, ventricular septal defect, left ventricular aneurysm or pseudoaneurysm, and pericarditis. Cardiac catheterization is indicated due to the continued chest discomfort. Although the finding of a totally occluded vessel this long after the acute event would not require percutaneous coronary intervention if the patient were asymptomatic, the ongoing symptoms suggest areas of ischemia and hence percutaneous coronary intervention for a totally occluded vessel might be useful for symptom relief. ■

Notes

A 78-year-old man with longstanding hypertension and a prior myocardial infarction (MI) presents to his cardiologist's office with progressive chest discomfort on exertion. Over the course of the previous 6 weeks he has noticed increasing chest discomfort at progressively lower workloads. He is now having chest discomfort with walking only about half a flight of stairs. On his cardiologist's recommendation, he undergoes urgent cardiac catheterization and is found to have a right dominant circulation with a totally occluded proximal left anterior descending artery (LAD). The distal LAD fills via right-to-left collaterals. There is an 80% mid–right coronary artery stenosis.

What does his ECG show?

What is the likely diagnosis?

Which vessel is likely to be causing his symptoms?

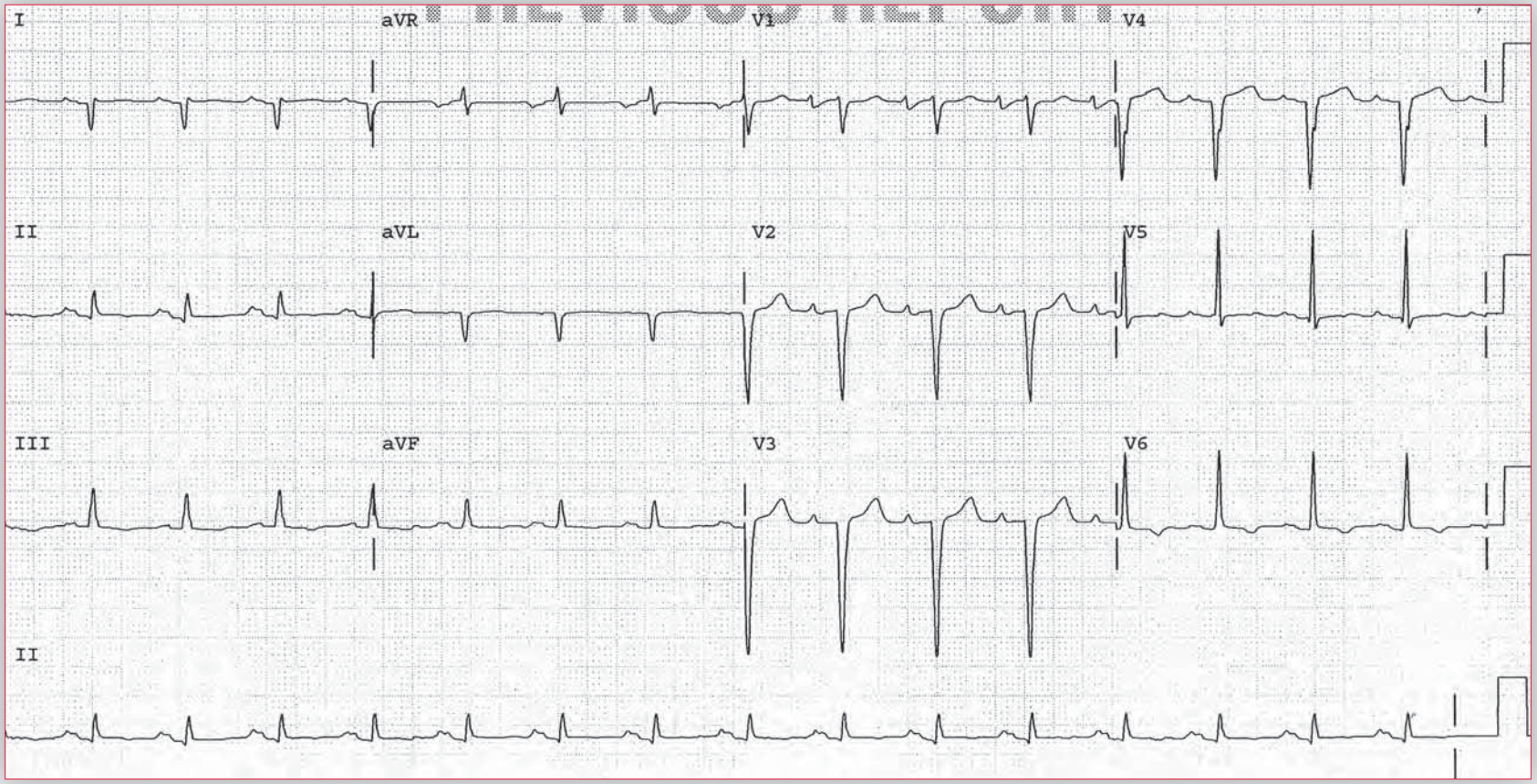

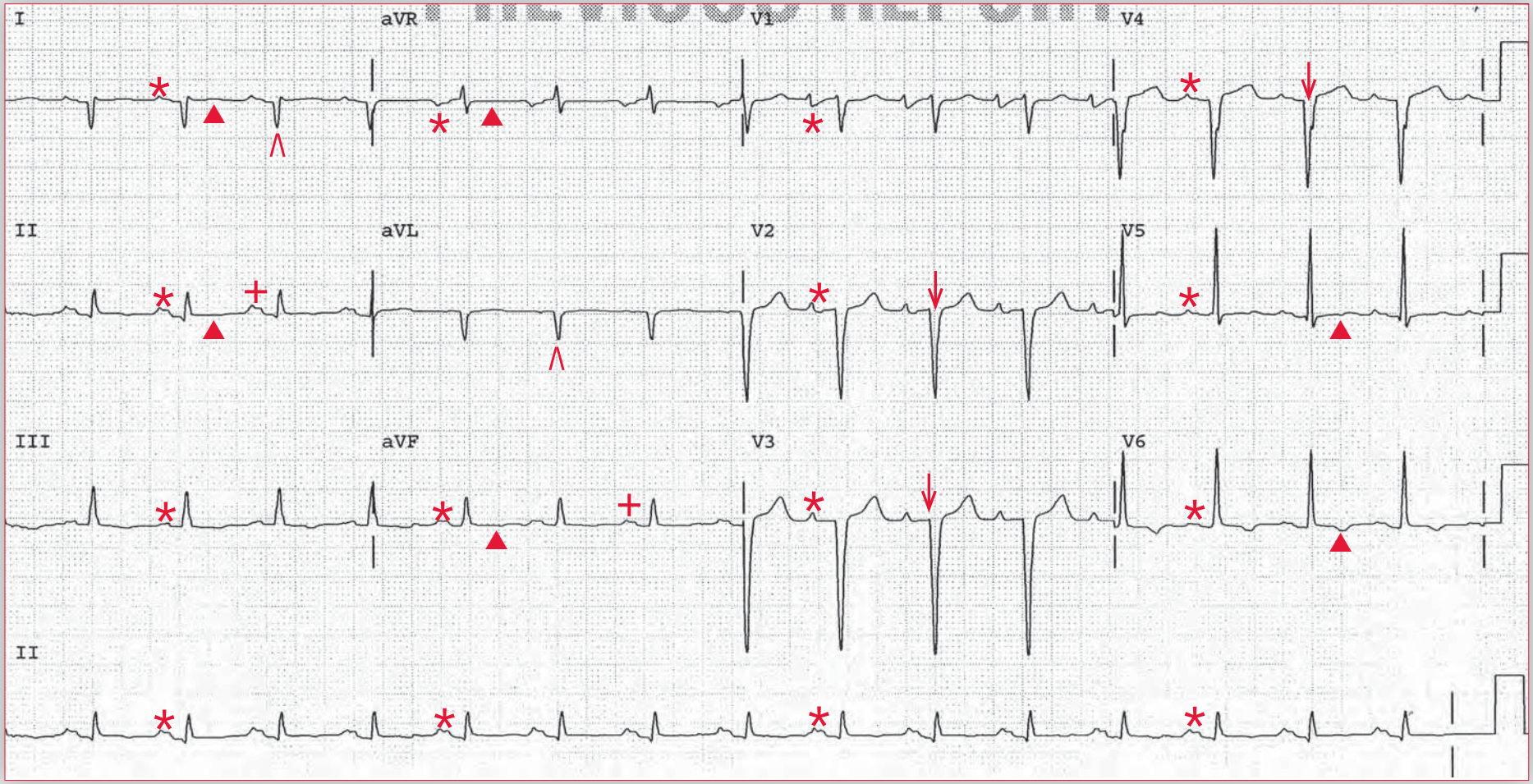

ECG 39 Analysis: Normal sinus rhythm, first-degree AV block, left atrial hypertrophy (abnormality), old lateral wall MI, old anteroapical MI, nonspecific T-wave abnormalities, right axis deviation due to an old lateral wall MI

There is a regular rhythm at a rate of 94 bpm. There are P waves (*) before each QRS complex, with a stable PR interval (0.22 sec). The P waves are upright in leads I, II, aVF, and V4-V6 and negative in lead aVR. This is a normal sinus rhythm with a first-degree AV block. The P waves (+) in leads II and aVF are broad and notched, characteristic of left atrial hypertrophy (abnormality).

The QRS complex duration is normal (0.08 sec). The QT/QTc intervals are normal (340/430 msec). The axis is rightward, between +90° and +180°, but this is the result of Q waves (QS complex) (^) in leads I and aVL, diagnostic for an old lateral wall myocardial infarction (MI). Hence the right axis deviation (negative QRS complex in lead I and positive QRS complex in lead aVF) is the result of a lateral wall infarction (QS morphology) and not a conduction abnormality resulting from a left posterior fascicular block, which would show a QRS complex with an rS morphology in leads I and aVL. Other causes of a right axis deviation include right ventricular hypertrophy (with a tall R wave in lead V1), right-to-left arm lead switch (which would also result in negative P waves in leads I and aVL), Wolff-Parkinson-White pattern (with a short PR interval and wide QRS complex due to a delta wave), or dextrocardia (with negative P waves in leads I and aVL). When there are no other causes for a right axis deviation, a left posterior fascicular block can be diagnosed. There are also Q waves (QS complexes) (↓) in leads V2-V4, diagnostic for an old anteroapical MI. Also noted are nonspecific T-wave abnormalities (▲) in the limb leads and leads V5-V6.

This patient has evidence of a completed infarction in the lateral and anteroapical territories. These have likely been caused by prior occlusion of his left anterior descending artery. It is most likely that the stenotic right coronary artery is causing incomplete collateral flow to the remaining anterior wall territory as well as the inferior wall. Revascularization of the right coronary artery would likely result in an improvement in his symptoms. ■

Notes

A 58-year-old woman is admitted to the cardiac care unit for management of decompensated heart failure. The treating physicians notice a marked left axis deviation on her ECG.

What does her ECG show?

What is the likely diagnosis and cause of her left axis deviation?

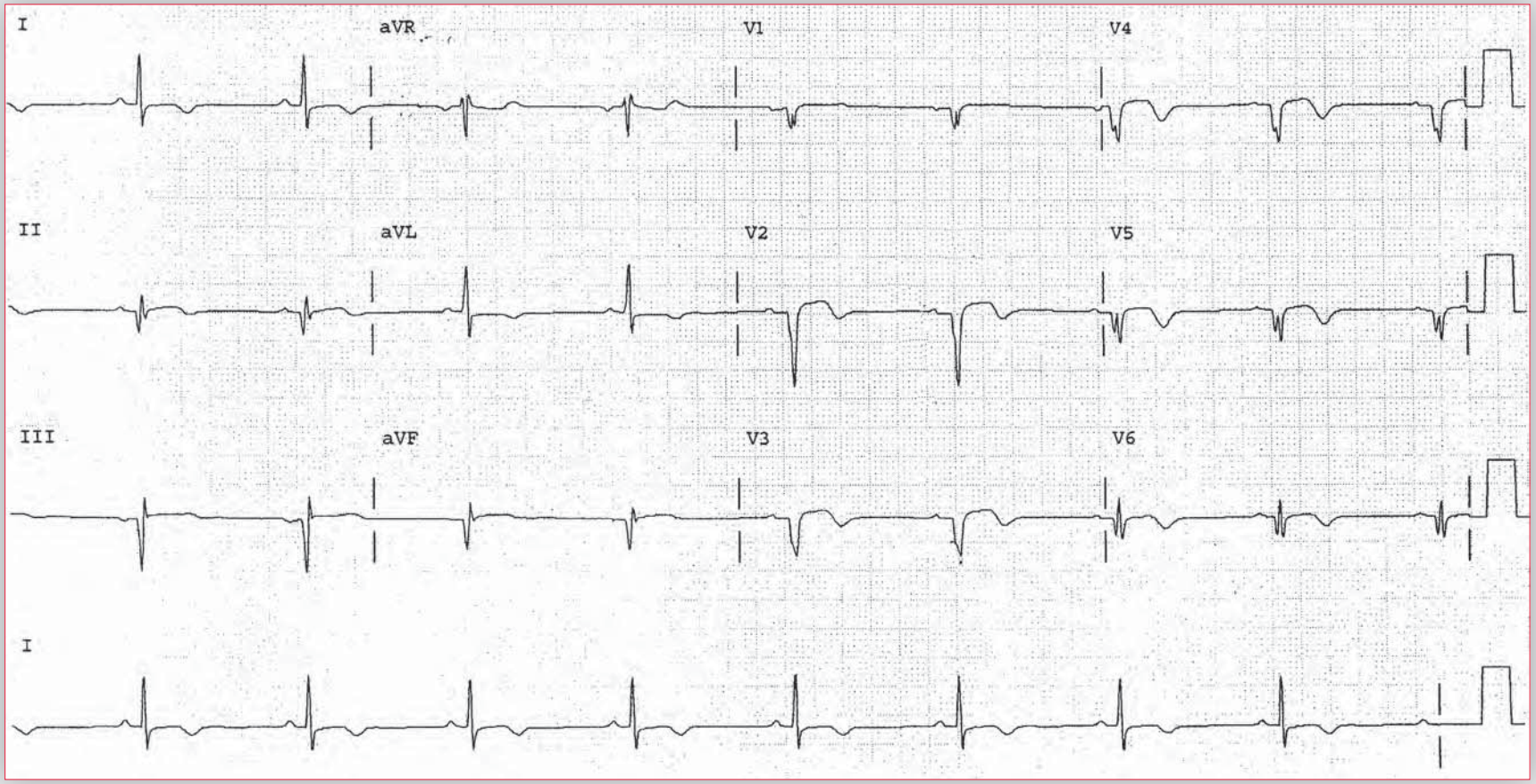

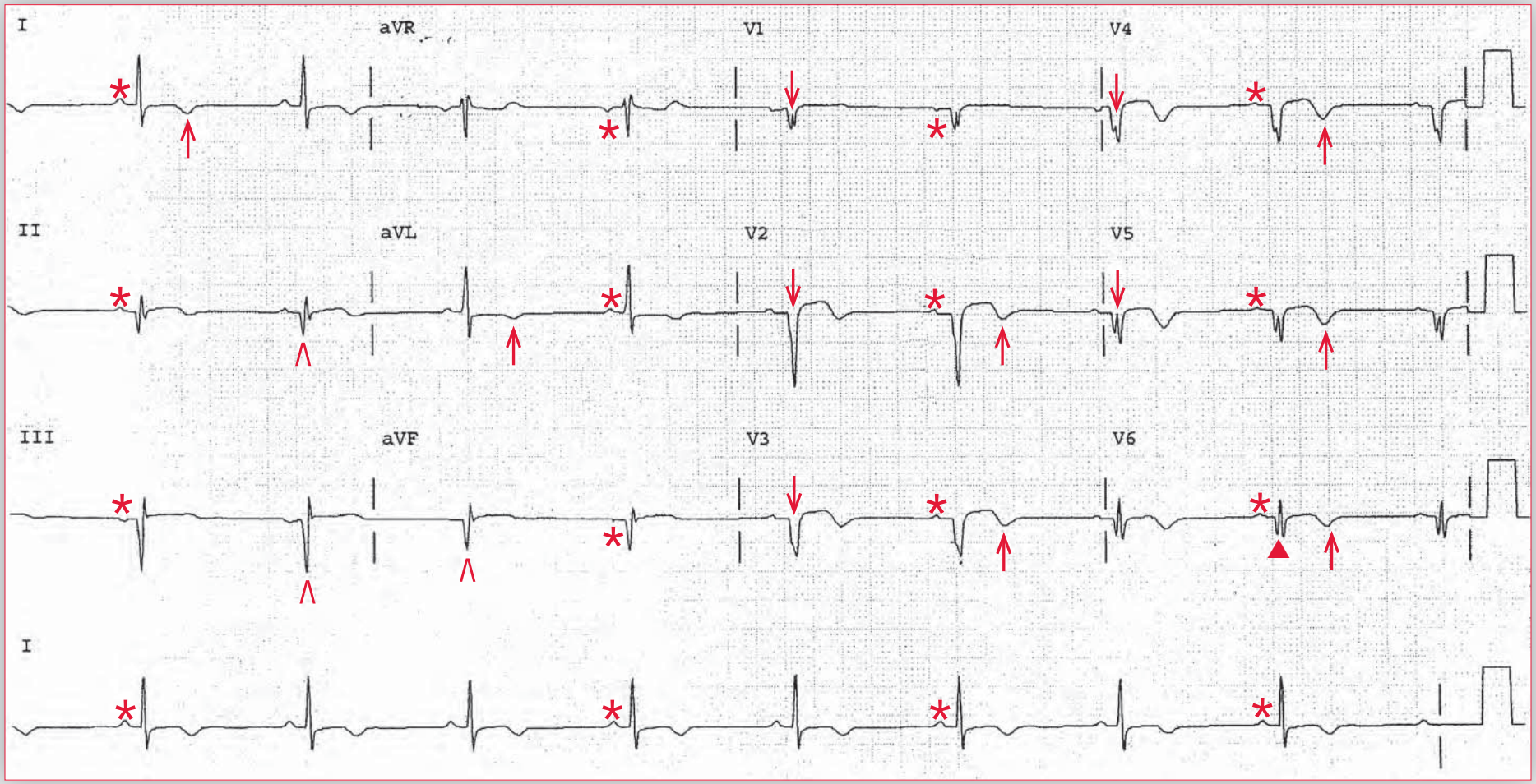

ECG 40 Analysis: Sinus bradycardia, old inferior wall myocardial infarction (MI), old anterior wall MI, left axis deviation due to an old inferior wall MI

There is a regular rhythm at a rate of 54 bpm. There are P waves (*) before each QRS complex, with a stable PR interval (0.16 sec). The P waves are upright in leads I, II, aVF, and V4-V6 and negative in lead aVR. This is a sinus bradycardia. The P-wave morphology is normal.

The QRS duration is normal (0.08 sec). The QT/QTc intervals are normal (440/420 msec). There are significant Q waves (^) in leads II, III, and aVF, diagnostic for an old inferior wall myocardial infarction (MI). As a result of the deep Q waves the axis is extremely leftward (positive QRS complex in lead I and negative QRS complex in leads II and aVF). However, this is not a conduction abnormality resulting from a left anterior fascicular block (in which the QRS complex would have an rS morphology) but rather is due to the inferior wall infarction (the QRS complex has initial Q waves and a Qs morphology). There are also Q waves (QS complex) (↓) in leads V1-V5 and a Q wave in lead V6 (▲), diagnostic for an old extensive anterior wall MI. The T waves (↑) are inverted in leads V2-V6 as well as leads I and aVL. ■

Core Case 41

A 58-year-old man is admitted to the hospital with a prolonged episode of chest discomfort. His initial laboratory studies are normal, and an ECG (41A) is obtained.

ECG 41A

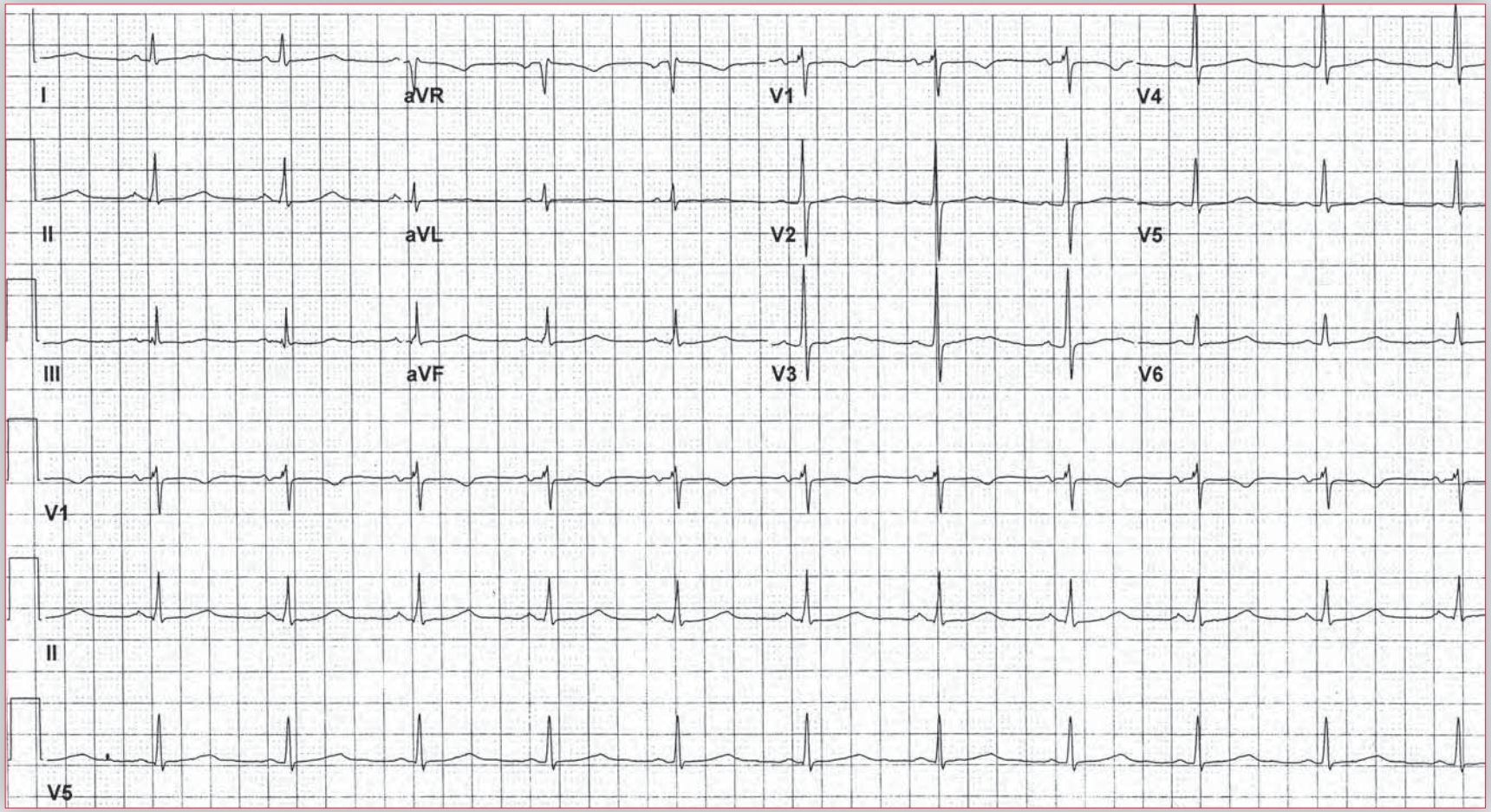

The following morning, his cardiac biomarkers become positive, with elevated creatine kinase (CK), CK-MB, and troponin I levels. A second ECG (41B) is obtained.

What do the ECGs show?

What is the likely diagnosis?

ECG 41B

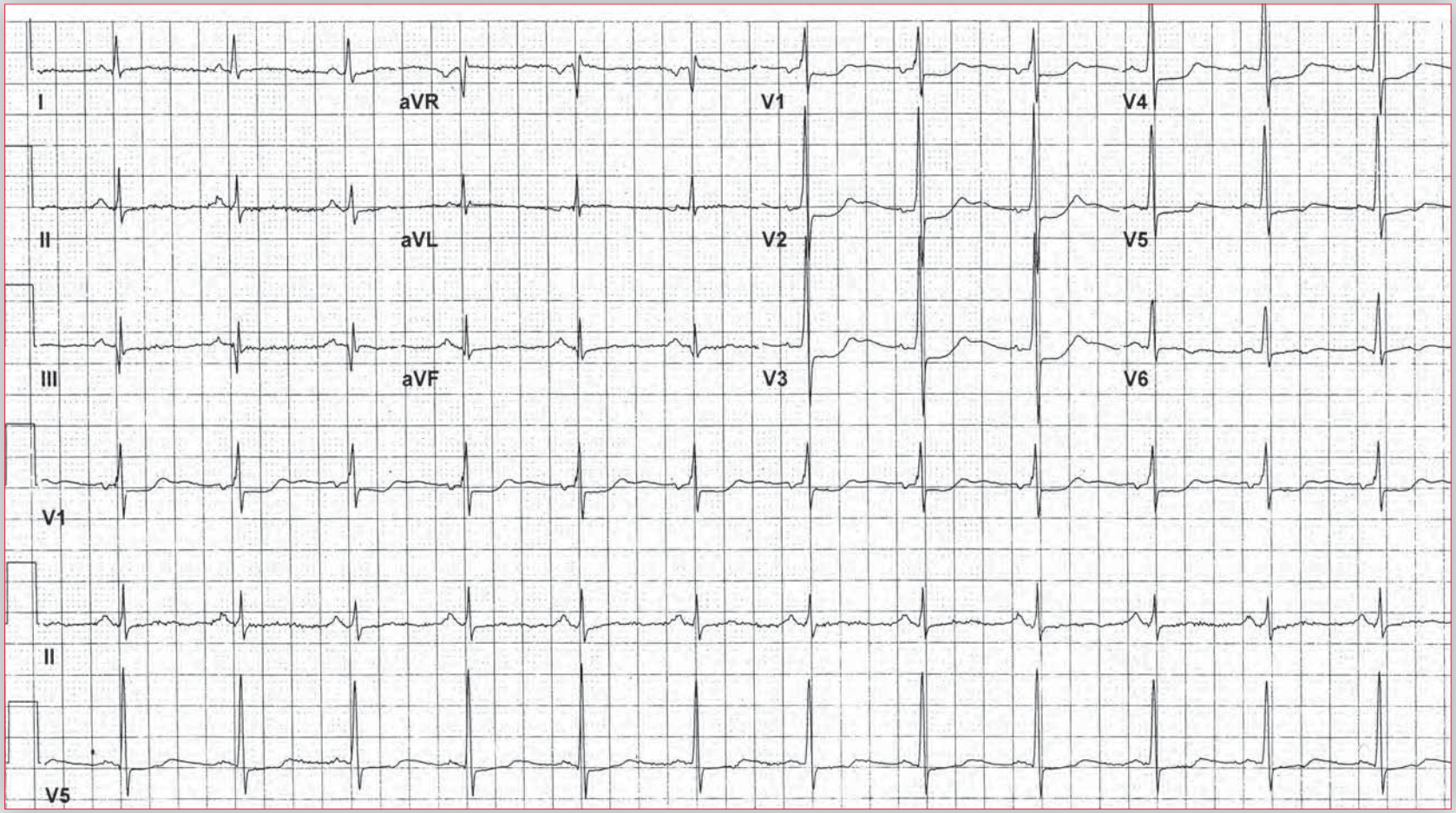

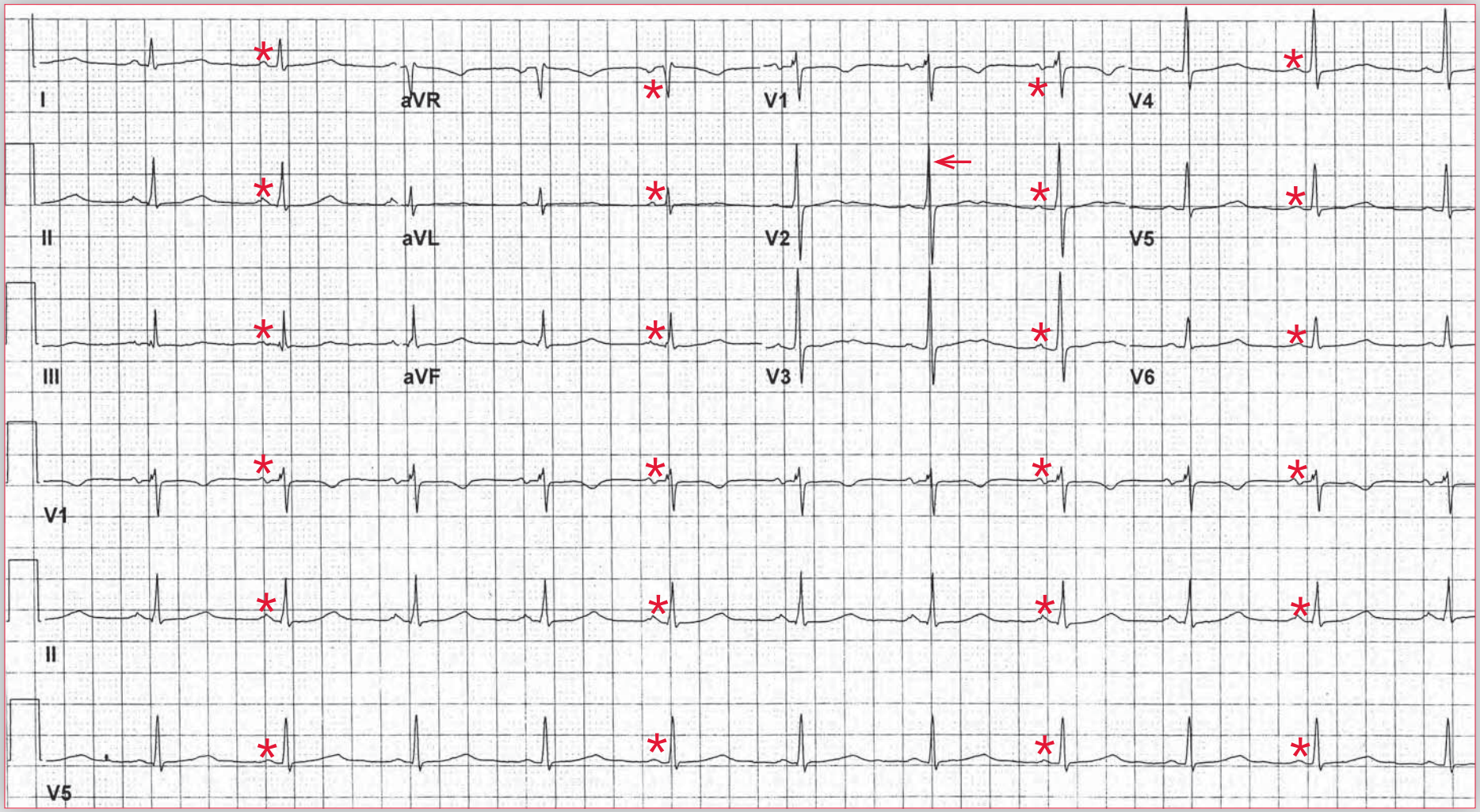

ECG 41A Analysis: Normal sinus rhythm, counterclockwise rotation (early transition), prolonged QT interval, nonspecific T-wave abnormalities

ECG 41A shows a regular rhythm at a rate of 68 bpm. There are P waves (*) before each QRS complex, with a stable PR interval (0.16 sec). The P waves are upright in leads I, II, aVF, and V4-V6 and negative in lead aVR. This is a normal sinus rhythm. The P-wave morphology is normal.

The QRS complex duration is normal (0.08 sec), and there is a normal morphology and axis, between 0° and +90° (positive QRS complex in leads I and aVF). The QT/QTc intervals are slightly prolonged (430/460 msec). The tall R wave in lead V2 (←) is the result of early transition or counterclockwise rotation (*ie*, an axis shift in the horizontal plane). This is determined by imagining the heart as viewed from under the diaphragm. With counterclockwise rotation the left ventricular forces develop early in the chest leads and are seen in the right precordial leads, accounting for the tall R wave in lead V2. There are no acute changes, but diffuse nonspecific T-wave changes (flattening) are seen.

continues

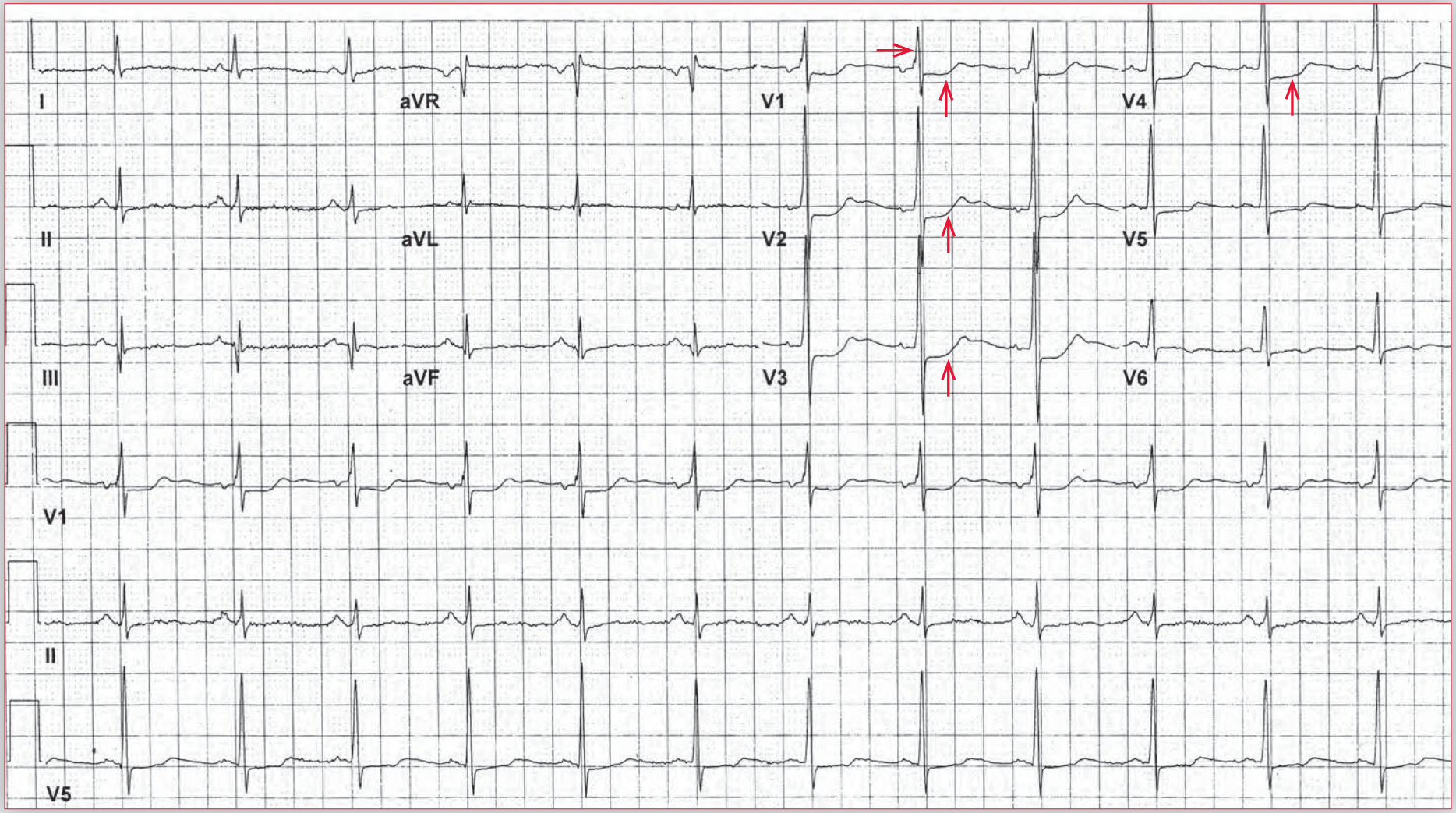

ECG 41B Analysis: Normal sinus rhythm, acute posterior wall myocardial infarction (MI)

ECG 41B was obtained on the day following admission. As noted, cardiac biomarkers were now positive with elevated creatine kinase (CK), CK-MB, and troponin levels. **ECG 41B** is identical to **ECG 41A** except for the presence of a tall R wave in lead V1 (→) and ST-segment depressions below the baseline (TP segment) in leads V1-V4 (↑). This is characteristic of an acute true posterior wall myocardial infarction (MI; without inferior wall involvement). At the time of catheterization there was an acute thrombotic occlusion of the first obtuse marginal branch of the left circumflex artery.

In light of the clinical presentation, a tall R wave in lead V1 (R-wave amplitude >7 mm or R/S > 1) with a duration of 0.04 second or longer, when associated with ST-segment depression in leads V1-V4, is indicative of a posterior wall myocardial MI. The posterior wall MI can be confirmed by obtaining posterior leads, placed below the left scapula (leads V7-V8). The presence of ST-segment elevation in these leads would be seen with a posterior wall MI. As the patient has ST-segment depressions in leads V1-V4, which are reciprocal changes, ST-segment elevation would likely be seen. In addition, the QRS complex would show a Q-wave or QS pattern, indicating the MI. Although a posterior wall MI is typically seen in association with inferior wall MI, there may be a true isolated posterior wall infarction often associated with a lesion of the obtuse marginal branch. Although there are other causes of a tall R wave in lead V1, the presence of ST-segment depression in leads V1-V4 supports the diagnosis of a posterior wall MI. Other causes for a tall R wave in lead V1 that need to be considered include right ventricular hypertrophy, Wolff-Parkinson-White pattern, dextrocardia, lead misplacement, Duchenne muscular dystrophy, and hypertrophic cardiomyopathy. On occasion it may be a normal variant or due to counterclockwise rotation. ■

Notes

A 64-year-old man presents with complaints of epigastric and mid-chest discomfort. The epigastric pain began about 2 weeks earlier and was associated with belching and nausea. He initially attributed the pain to indigestion and did not seek medical attention. The pain eventually subsided but was replaced with a sharp chest pain, made worse by inspiration or supine positioning. His presenting ECG is shown.

What does his ECG show?

What is the likely diagnosis?

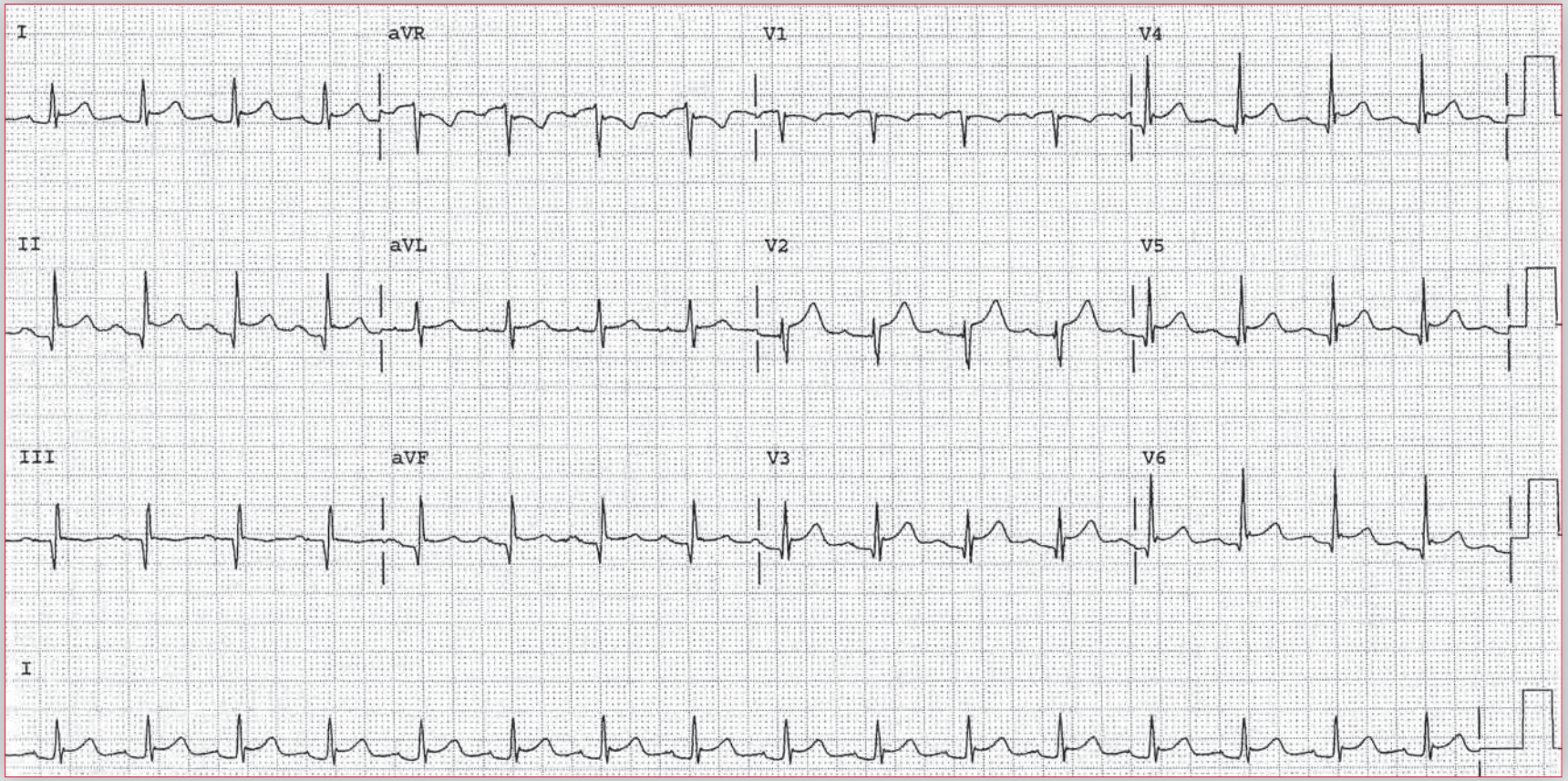

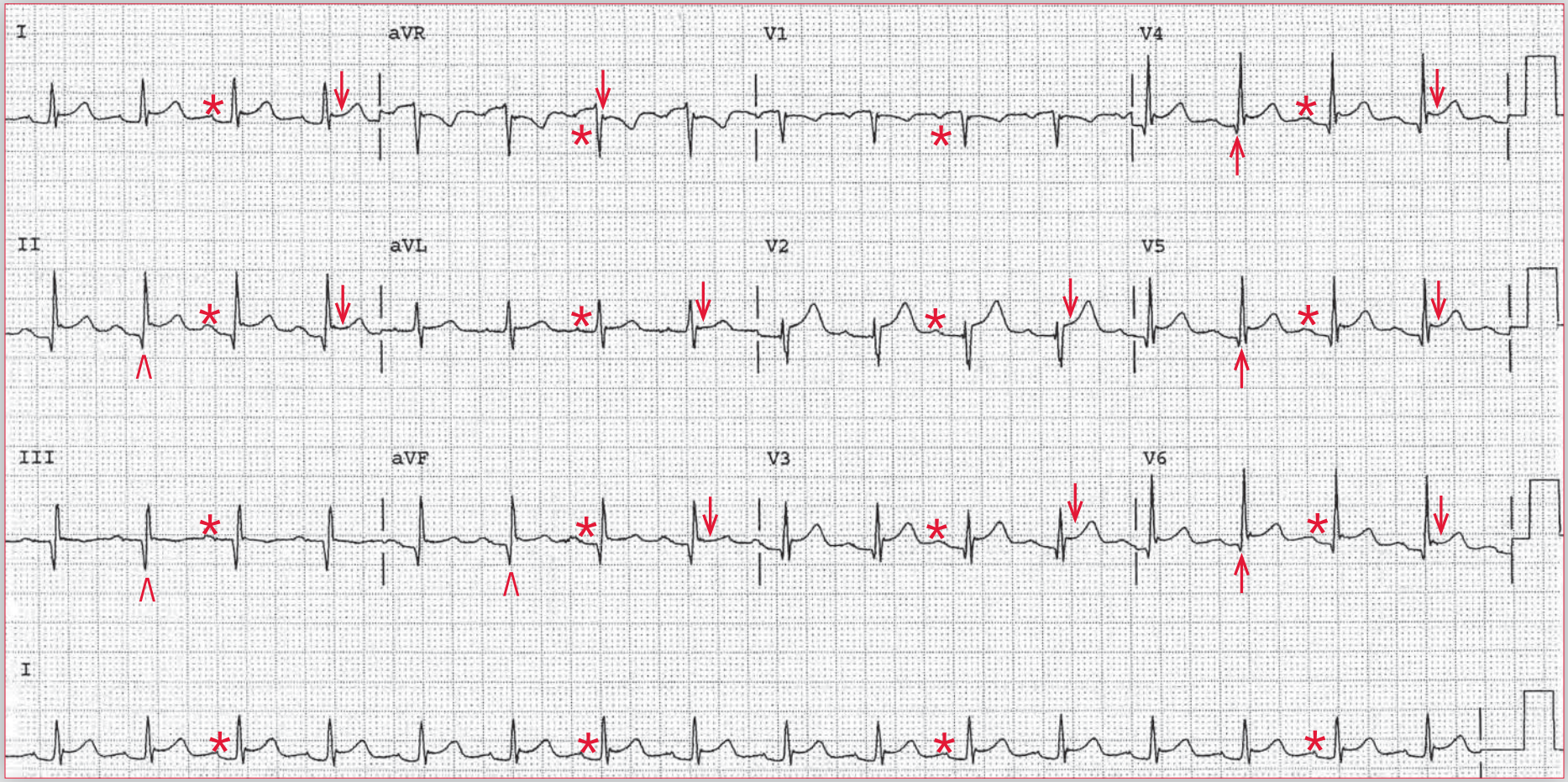

ECG 42 Analysis: Normal sinus rhythm, old inferior wall myocardial infarction (MI), pericarditis

There is a regular rhythm at a rate of 98 bpm. There is a P wave (*) before each QRS complex, and the PR interval is stable (0.20 sec). The P wave is positive in leads I, II, aVF, and V4-V6 and negative in lead aVR. The P-wave morphology is normal. This is a normal sinus rhythm.

The QRS complex duration is normal (0.08 sec), and there is a normal axis, between 0° and +90° (positive QRS complex in leads I and aVF). The QT/QTc intervals are normal (320/410 msec). There are Q waves (^) in leads II, III, and aVF that are diagnostic of an old inferior wall myocardial infarction (MI). The Q waves in leads V4-V6 (↑) are small and narrow and represent septal depolarization.

Diffuse J-point and ST-segment elevation (↓) above the baseline (TP segment) can be seen in leads I, II, aVR (ST-segment depression in this lead is actually ST-segment elevation), aVL, aVF, and V2-V6. Diffuse ST-segment elevation is characteristic of pericarditis. Noted is that the concave morphology of the ST segment is maintained and the T-wave morphology is normal (asymmetric). Also noted is slight PR-segment depression (PR segment compared with the baseline [TP segment]), which is most obvious in leads I and II.

The characteristic ECG findings in patients with pericarditis are as follows:

- Diffuse ST-segment elevation is seen in all or almost all leads. ST segments have normal concave morphology regardless of the height of ST-segment elevation. There are no evolutionary ECG changes (*ie*, the ST segments remain concave, ultimately returning to baseline).
- There is no reciprocal ST-segment depression.
- T waves are normal (*ie*, asymmetric).
- PR interval depression may be seen. However, its absence does not exclude pericarditis.
- T-wave inversion may occur after ST segments return to isoelectric baseline.

Based on his history, this patient likely suffered an inferior MI at the time of his initial symptom onset about 2 weeks before presentation. The description of his chest discomfort is consistent with angina. This is manifest by the inferior Q waves. His subsequent chest pain is different and is consistent with pericarditis, suggesting that he has now developed a post-infarction pericarditis. MI can be associated with pericarditis at various stages of the evolution and healing process. Infarction pericarditis occurs simultaneously with the onset of MI and is caused by acute injury to the myocardium and subsequent myocardial and pericardial inflammation (sympathetic effusion). Pericarditis that occurs after the initial infarction period has resolved (3 days up to several months) is termed postcardiac injury syndrome (also called Dressler's syndrome) and is believed to be caused by an immune mechanism. Myocardial antigens are released with the infarction, resulting in the production of anti-myocardial antibodies. The development of antigen–antibody immunocomplexes results in a serum sickness episode that can produce fever, serositis (pleural and pericardial), acute renal insufficiency, and arthritis and arthralgias. Pericarditis of the same etiology can also be seen after cardiac surgery and is termed a postcardiotomy syndrome. ■

Notes

A 19-year-old man with no prior medical history presents with 2 days of intermittent chest discomfort and fever. He had been seen in the medical walk-in clinic 1 week earlier for an upper respiratory tract infection and was treated with a short course of antibiotics.

What does his ECG show?

What is the likely diagnosis?

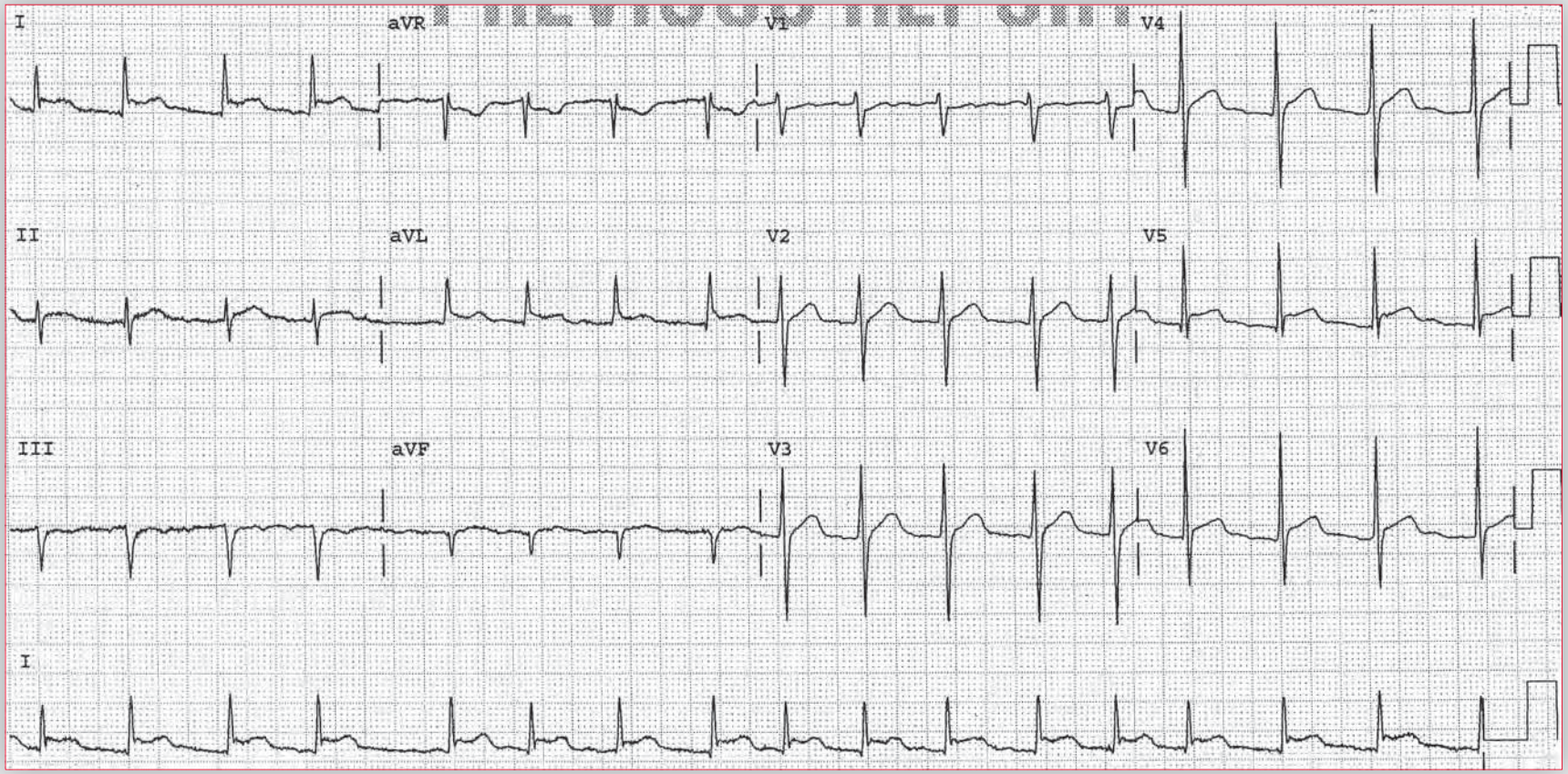

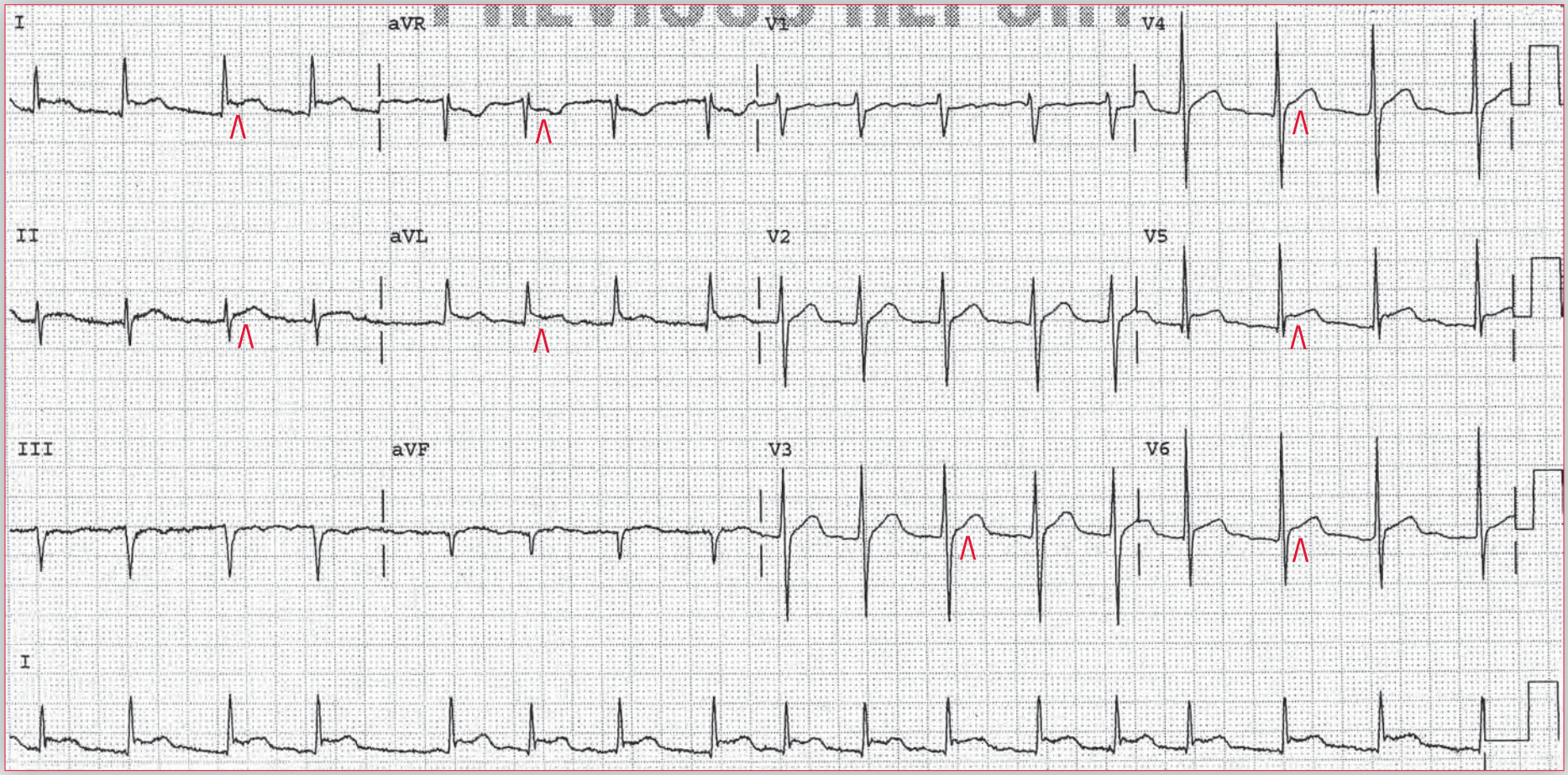

ECG 43 Analysis: Atrial fibrillation, pericarditis

There is an irregularly irregular rhythm at an average rate of 102 bpm. There are no P waves before or after any QRS complexes. This is atrial fibrillation.

The QRS complex duration is normal (0.08 sec), and there is a physiologic left axis deviation, between 0° and –30° (positive QRS complex in leads I and II and negative QRS complex in lead aVF). The QT/QTc intervals are normal (320/420 msec). The ST segments are elevated (^) above the baseline (TP segment) in leads I, II, aVR (ST-segment depression in this lead is actually ST-segment elevation), aVL, and V3-V6. Therefore, this is pericarditis. The concave morphology of the ST-segment is maintained, and the T-wave morphology is normal (asymmetric).

This patient likely has a viral pericarditis. The most common viruses implicated in viral pericarditis are the echoviruses, coxsackieviruses A and B, adenoviruses, and HIV. Atrial fibrillation is commonly associated with pericarditis and often resolves after resolution of the pericarditis. This patient was treated with a 2-week course of ibuprofen and achieved full resolution of his symptoms. Initial therapy for symptomatic acute pericarditis involves nonsteroidal anti-inflammatory drugs (NSAIDs, such as ibuprofen or aspirin) or colchicine. Persistent severe symptoms despite NSAIDs and colchicine can be treated with a brief course of steroid therapy. An echocardiogram should be obtained to evaluate for the presence of a pericardial effusion. Although uncommon, a large effusion with evidence of tamponade would require pericardiocentesis. ■

Notes

A 26-year-old athlete attends a pre-participation medical examination. No abnormalities are found on physical examination, and he has no current symptoms of cardiovascular disease. An ECG is obtained.

What does his ECG show?

What is the likely diagnosis?

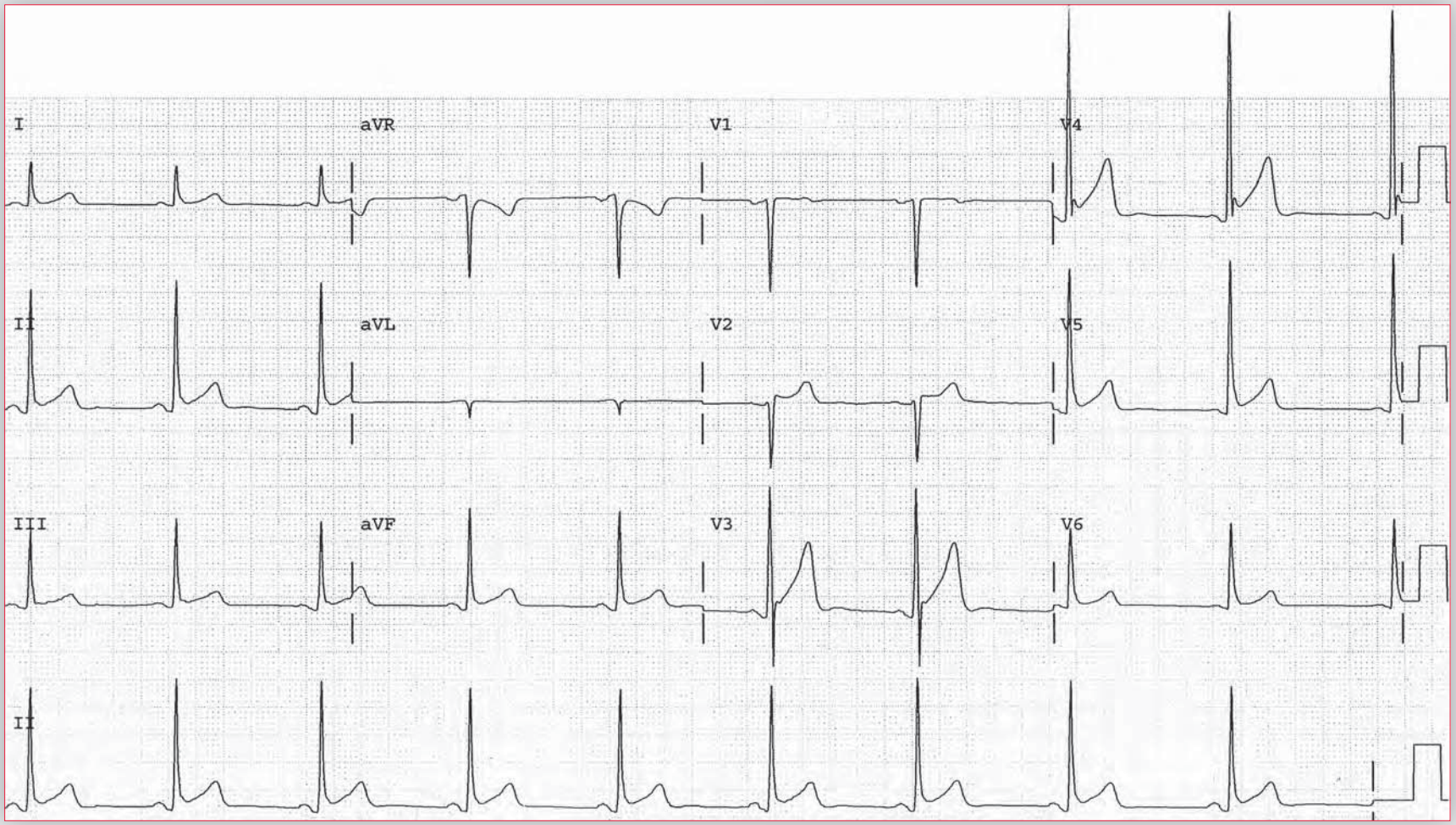

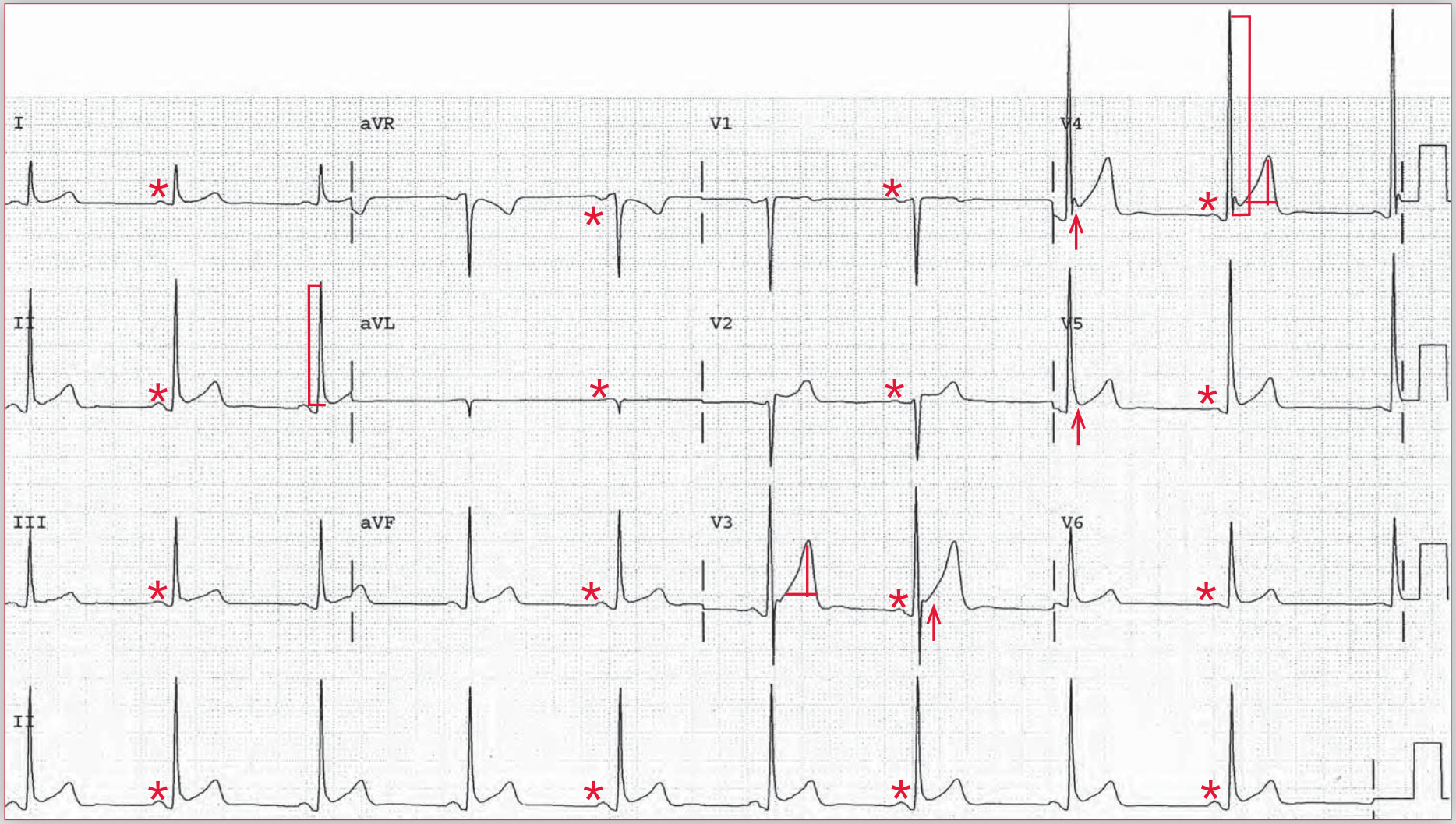

ECG 44 Analysis: Sinus bradycardia, tall QRS voltage, early repolarization

There is a regular rhythm at a rate of 56 bpm. There are P waves (*) before each QRS complex, and the PR interval is stable (0.16 sec). The P waves are positive in leads I, II, aVF, and V4-V6, and they have a normal morphology. This is sinus bradycardia.

The QRS complex duration (0.08 sec) and morphology are normal. The axis is normal, between 0° and +90° (positive QRS complex in leads I and aVF). The QT/QTc intervals are normal (400/390 msec). The QRS amplitude (voltage) is increased in lead V4 (42 mm) ( ]) as well as in lead II (23 mm) ([ ). Although the voltage present may meet criteria for left ventricular hypertrophy (*ie*, R-wave amplitude in any limb lead ≥ 20 mm and S-wave depth or R-wave amplitude in any precordial lead ≥ 25 mm), the tall QRS amplitude is most likely a normal variant, consistent with a young age and a very fit and athletic individual. Although the T waves are prominent in leads V3-V4, they are asymmetric and hence normal. They are likely prominent as the result of the tall QRS voltage. There is also J-point and ST-segment elevation (↑) above the baseline (TP segment), noted primarily in leads V3-V5. This is termed early repolarization and it is a normal finding, often seen with left ventricular hypertrophy or in young subjects with or without prominent R-wave amplitude. ■

Notes

A 48-year-old body builder presents for a routine examination with his primary care physician. His blood pressure is noted to be 146/88 mm Hg and is symmetric in both arms. An ECG is obtained.

What does his ECG show?

What is the likely diagnosis?

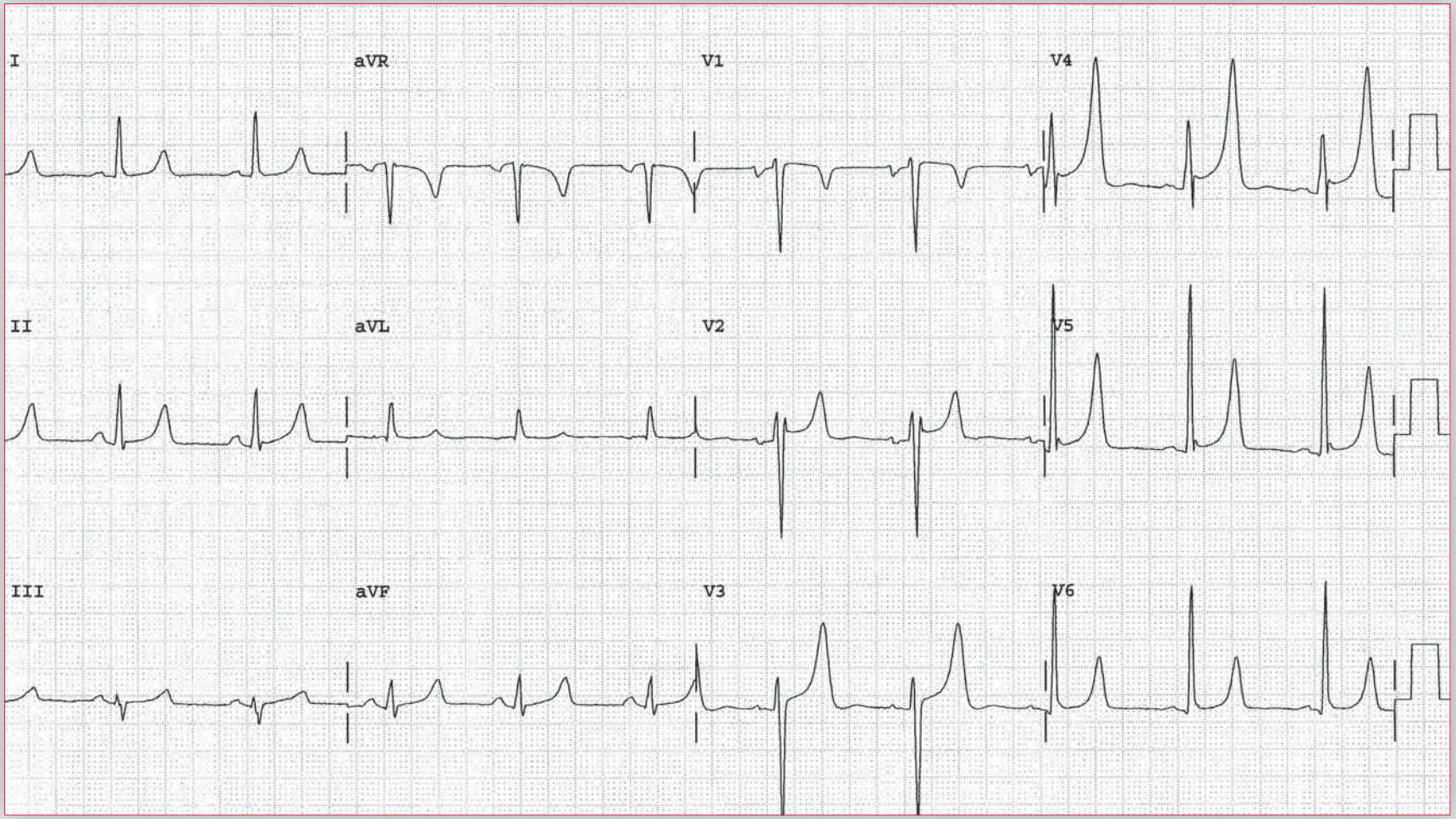

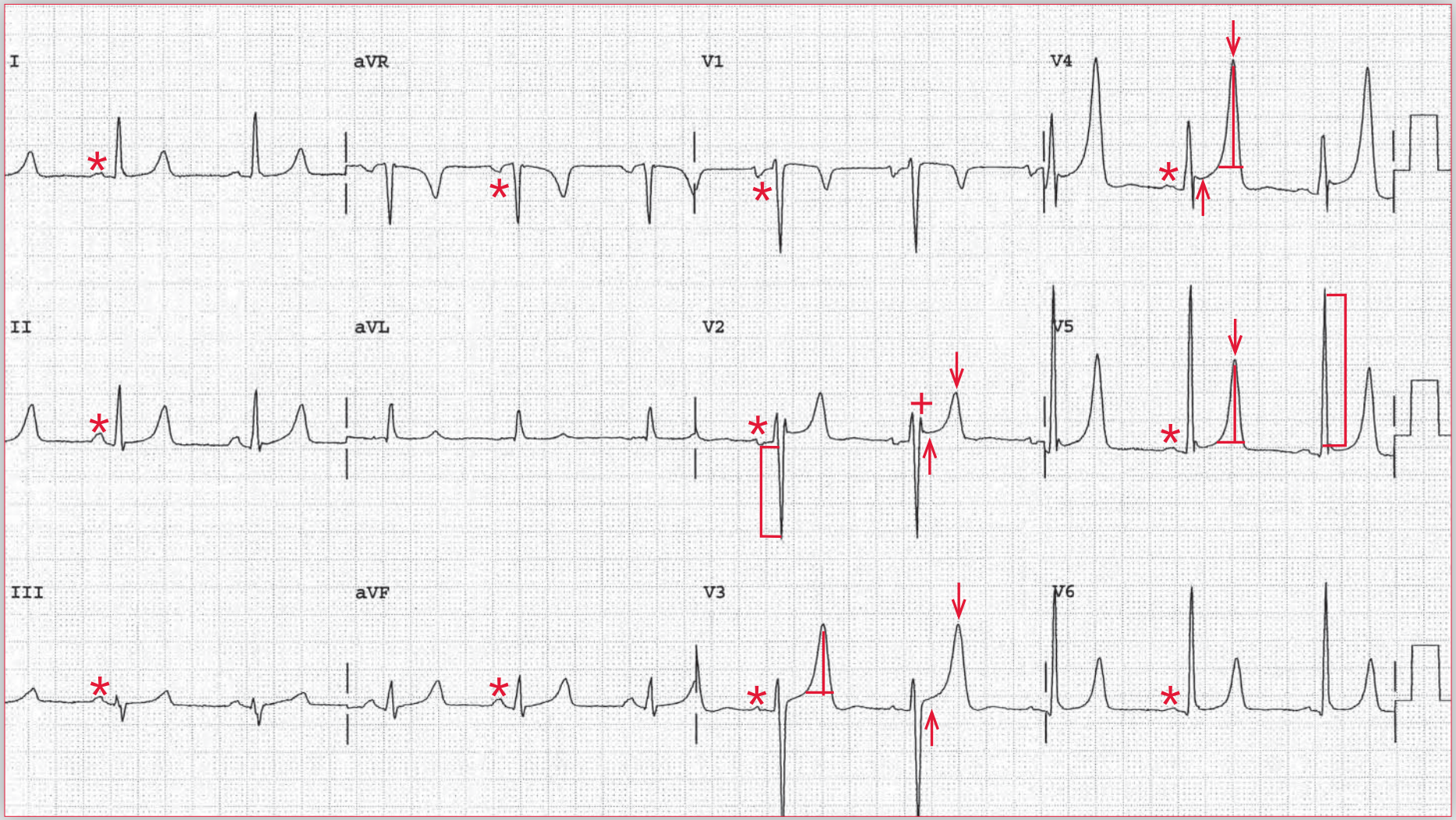

ECG 45 Analysis: Normal sinus rhythm, possible left ventricular hypertrophy (LVH), early repolarization, prominent but normal T waves

There is a regular rhythm at a rate of 60 bpm. There is a P wave (*) before each QRS complex, with a stable PR interval (0.16 sec). The P waves are positive in leads I, II, aVF, and V4-V6 and negative in lead aVR. They have a normal morphology. This is normal sinus rhythm.

The QRS complex duration is normal (0.08 sec), and the axis is normal, between 0° and +90° (positive QRS complex in leads I and aVF). The QT/QTc intervals are normal (400/400 msec). The QRS complex morphology is normal, although there is an R′ in lead V2 (+), which is a normal variant, suggesting a minimal right ventricular conduction delay. The R-wave amplitude (voltage) in lead V5 is increased (30 mm) ( ]), and the S-wave depth (voltage) in lead V2 is 15 mm ([ ) (S-wave depth in lead V2 + R-wave amplitude in lead V5 = 45 mm), which meets a voltage criterion for left ventricular hypertrophy (LVH) (S-wave depth in lead V1 or V2 + R-wave amplitude in lead V5 or V6 ≥ 35 mm). However, this patient is young and healthy and hence the prominent QRS complex amplitude may be a normal finding. J-point and ST-segment elevation (↑) are noted in leads V2-V4, which is termed early repolarization. This is often seen with tall QRS complex amplitude or voltage.

The T waves are tall and peaked, especially in leads V2-V5 (↓). However, they are asymmetric and hence normal. They likely appear tall and peaked as a result of the prominent QRS complex amplitude.

Normal T waves are asymmetric regardless of amplitude. They have a slower upstroke and faster downstroke. T waves that are tall, peaked and, most importantly, symmetric are hyperacute and are seen with hyperkalemia (systemic) or acute myocardial infarction (localized hyperkalemia).

Physiologic LVH, if indeed present, can develop in well-conditioned athletes, especially in those performing isometric exercise, such as weightlifting. LVH often resolves during a period of inactivity. Although LVH is a physiologic response to a high level of exercise, it can be associated with rhythm disturbances. Unlike pathologic LVH seen with hypertension, fibrosis of the myocardium, which occurs with LVH due to hypertension, generally does not develop with physiologic LVH. Hence diastolic dysfunction is less likely to occur. ■

Notes

A 56-year-old man with hypertension presents to a walk-in clinic with complaints of diarrhea and headaches. He reports that he developed diarrhea about 10 days earlier and has had malaise and headaches on a daily basis; oral intake has been poor. He has been taking high doses of ibuprofen to ease the pain but with little effect. He takes lisinopril for hypertension and is on a low-dose aspirin regimen. His primary care physician draws blood for laboratory testing in his office and notes elevated blood urea nitrogen (BUN) and creatinine levels.

What does his ECG show?

What is the likely diagnosis?

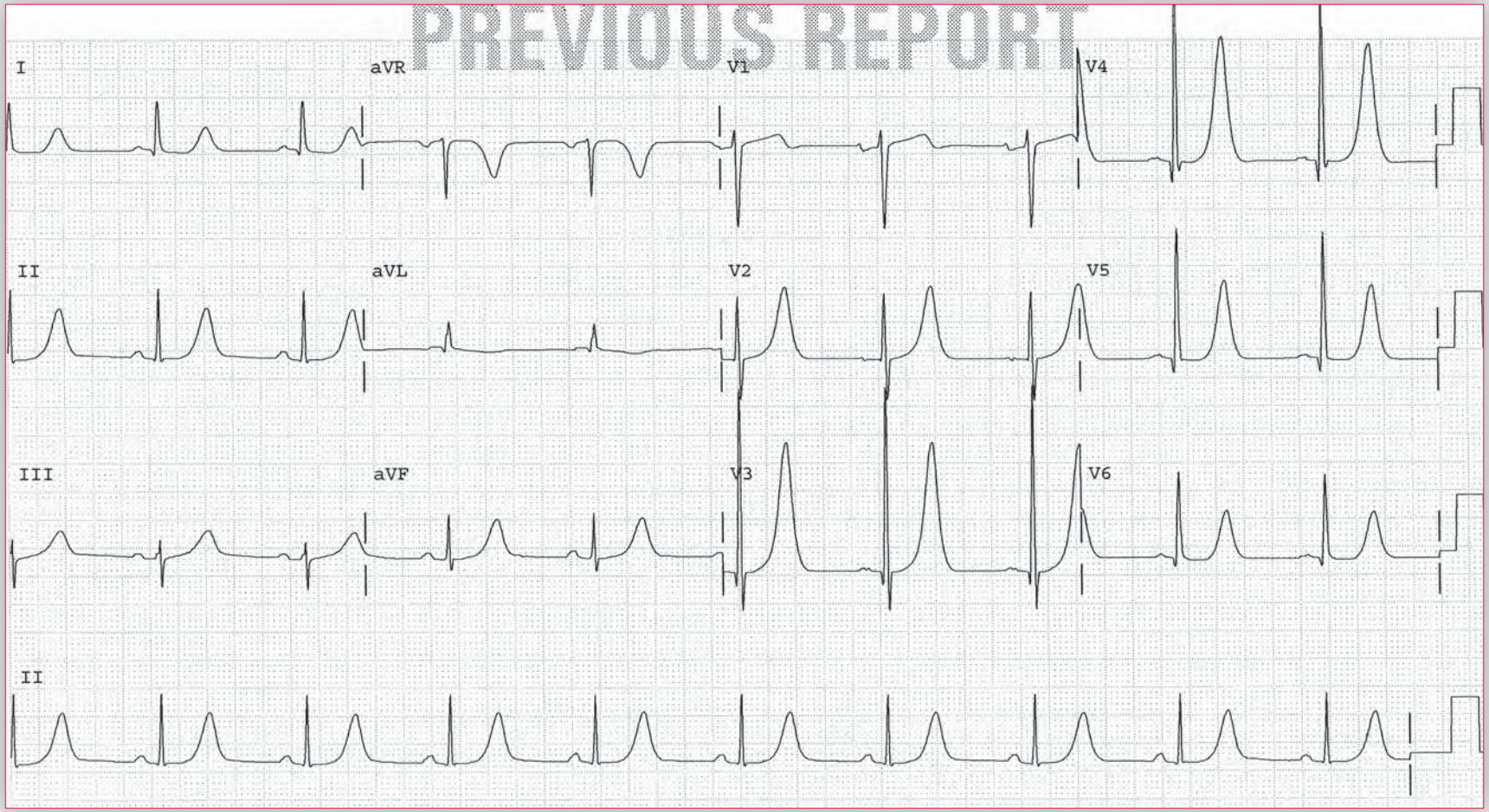

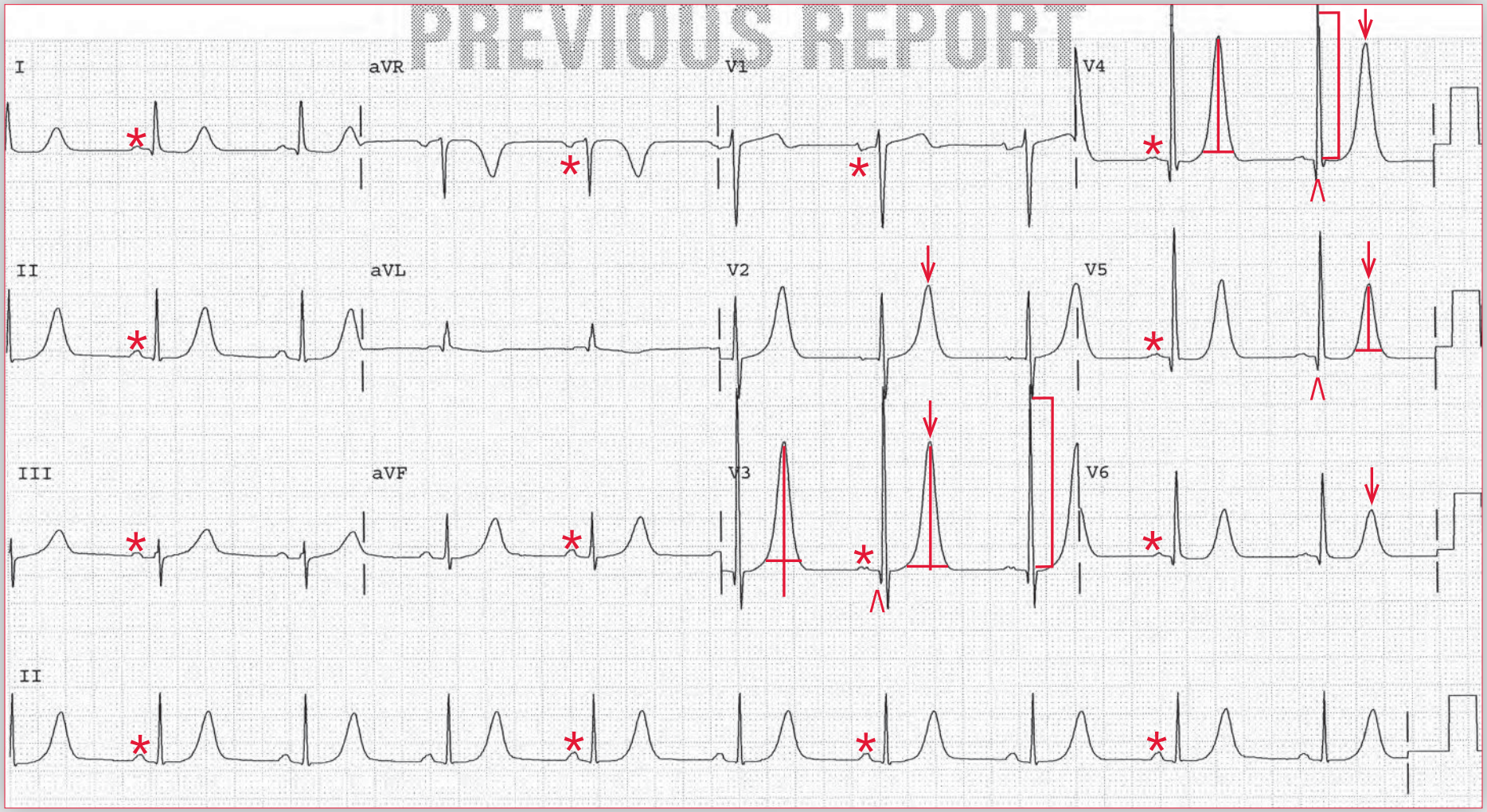

ECG 46 Analysis: Sinus bradycardia, left ventricular hypertrophy, hyperacute T waves (hyperkalemia), prolonged QT interval

There is a regular rhythm at a rate of 58 bpm. There is a P wave (*) before each QRS complex, with a stable PR interval (0.16 sec). The P waves are positive in leads I, II, aVF, and V4-V6 and negative in lead aVR. They have a normal morphology. This is sinus bradycardia.

The QRS complex duration is normal (0.08 sec), and the axis is normal, between 0° and +90° (positive QRS complex in leads I and aVF). The QRS complex morphology is normal. The QT/QTc intervals are prolonged (480/470 msec). The R-wave amplitude (voltage) in leads V3-V4 is increased (33 mm) ( ]), which meets a criterion for left ventricular hypertrophy (*ie*, S-wave depth or R-wave amplitude in any precordial lead ≥ 25 mm), although the tall voltage could be a normal finding in a patient who is thin and does not have any lung disease. There are narrow and small Q waves (^) (particularly in relation to the amplitude of the R wave) in leads V3-V6. These are septal Q waves.

The T waves (↓) are tall, peaked, and symmetric (*ie*, upstroke and downstroke are similar, and the T wave appears to be tented). Even though there is tall QRS complex amplitude, which is a possible etiology for the tall T waves, the symmetry of the T waves is unusual and hence these T waves are hyperacute, associated with hyperkalemia.

Normal T waves are asymmetric regardless of amplitude. They have a slower upstroke and faster downstroke. T waves that are tall, peaked and, most importantly, symmetric are hyperacute and seen with hyperkalemia (systemic or localized as in acute myocardial infarction).

This patient likely has hyperkalemia on the basis of acute renal failure. He is volume depleted from days of diarrhea and poor oral intake. Additionally, he is taking an angiotensin-converting enzyme inhibitor and a nonsteroidal anti-inflammatory medication. When taken in combination, these medications cause a marked reduction in the glomerular filtration rate and can exacerbate an acute renal insult. The hyperacute T waves do not correlate with the level of hyperkalemia. Although conduction abnormalities (which indicate more serious hyperkalemia) are not present, therapy is indicated. Generally sodium polystyrene sulfonate is all that is necessary, but if the potassium level is very high, glucose and insulin, calcium gluconate or chloride, and sodium bicarbonate (especially if the patient is acidotic) would be indicated. If anuric renal failure worsens, acute dialysis may be necessary. ■

Notes

A 48-year-old executive presents for his company-sponsored annual physical examination. He is in good health and has no current complaints. He has mild dyslipidemia, which has been managed with dietary and lifestyle changes.

What does his ECG show?

What is the likely diagnosis?

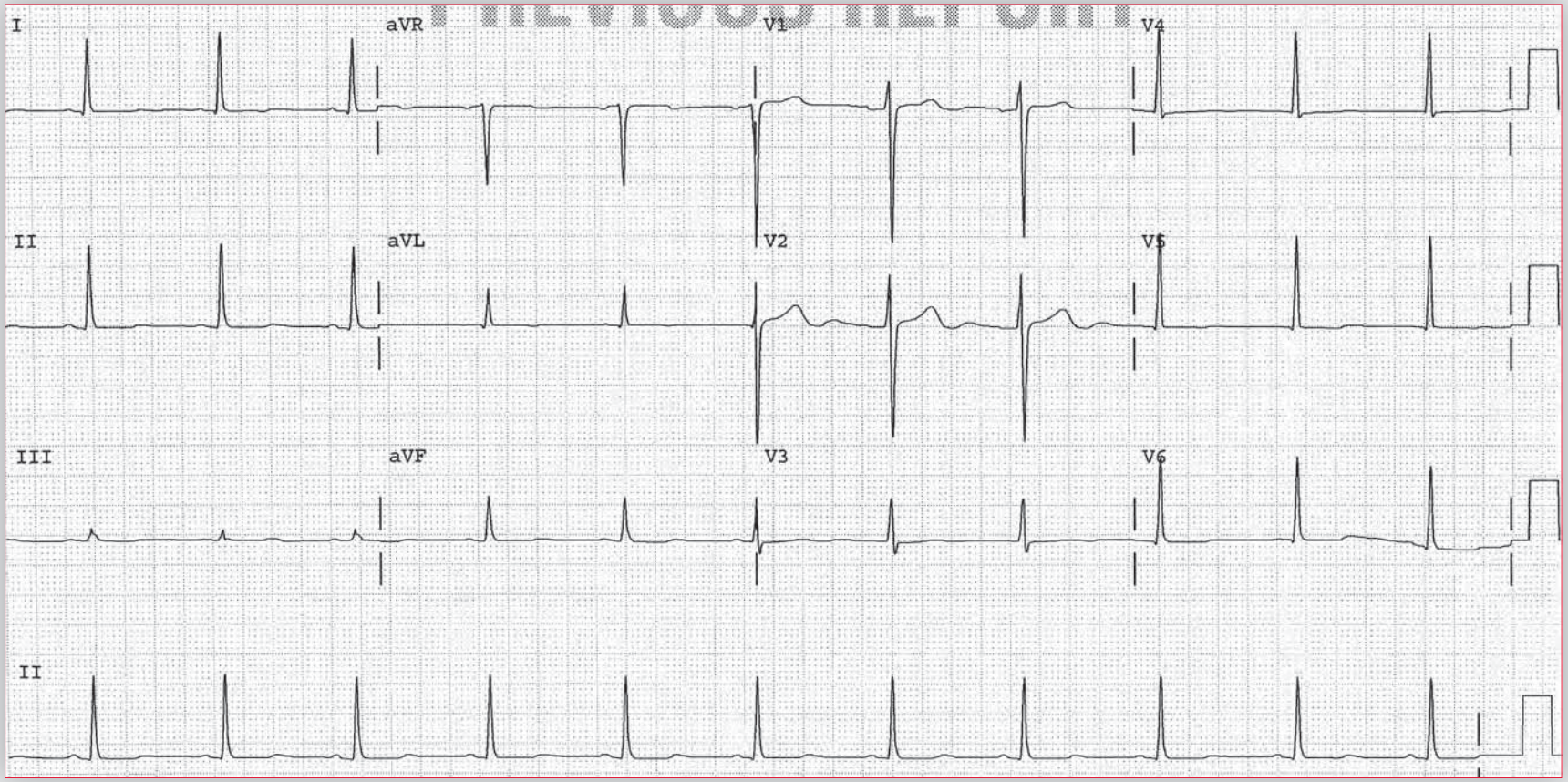

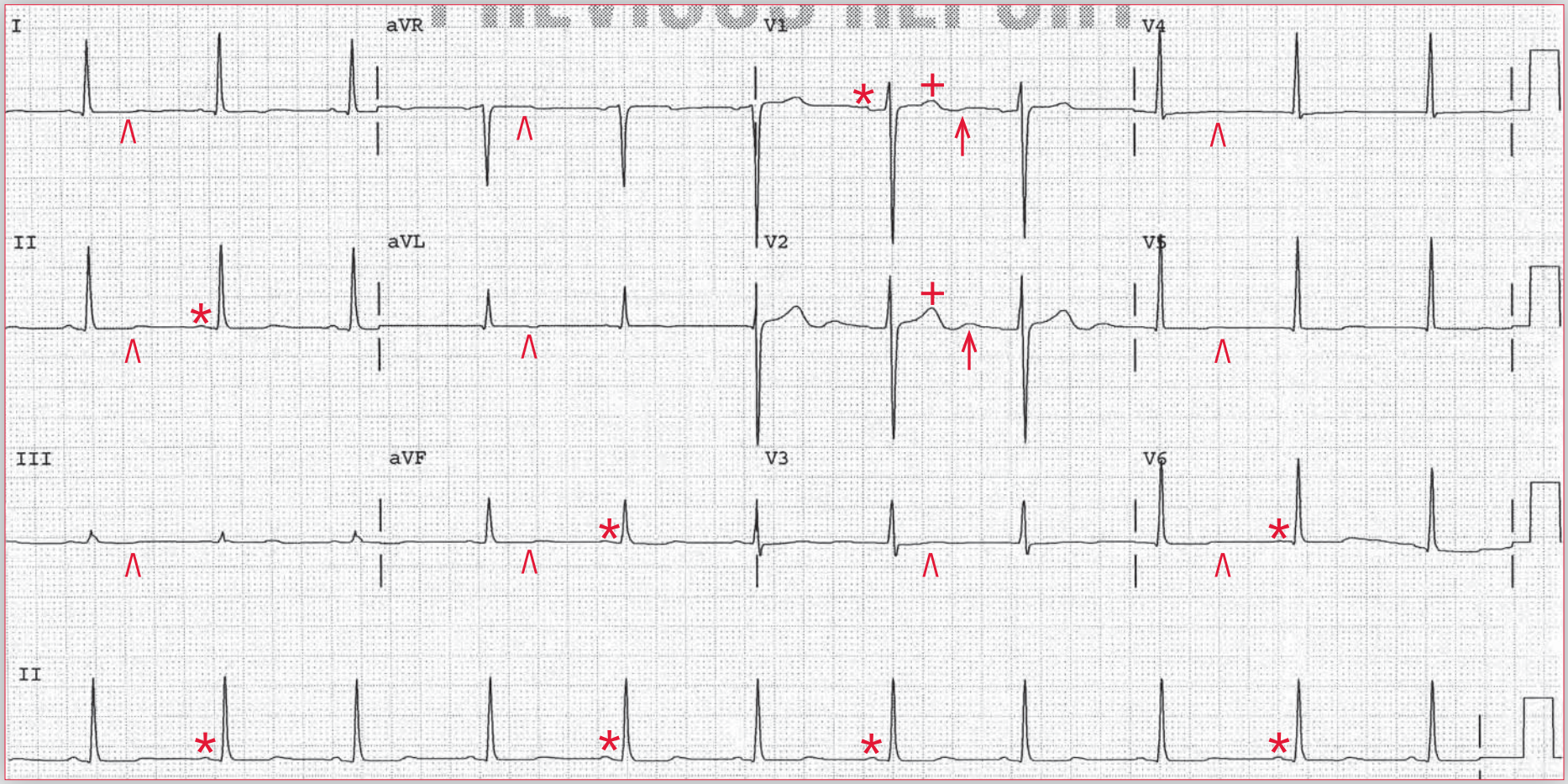

ECG 47 Analysis: Normal sinus rhythm, nonspecific T-wave abnormalities

There is a regular rhythm at a rate of 66 bpm. There is a P wave (*) before each QRS complex, with a stable PR interval (0.16 sec). The P waves are of low amplitude but appear to be positive in leads I, II, aVF, and V4-V6 and negative in lead aVR. This is a normal sinus rhythm.

The QRS complex duration is normal (0.08 sec), and the axis is normal, between 0° and +90° (positive QRS complex in leads I and aVF). The QRS complex morphology is normal. The QT/QTc intervals are normal (400/420 msec).

The T waves (^) in most of the leads are flat and barely obvious. A normal T wave (+) can be seen in leads V1-V2. The flattened T waves represent a nonspecific T-wave abnormality.

Nonspecific T-wave abnormalities include flat, biphasic, or inverted T waves. T-wave abnormalities may be seen in various situations, including ischemia (inverted T waves that are often symmetric and usually associated with ST-segment changes), left ventricular hypertrophy (due to repolarization abnormalities), pericarditis/myocarditis, metabolic and pH abnormalities, old myocardial infarction, or central nervous system abnormalities; or they may be nonspecific. T-wave abnormalities may be seen in healthy subjects as a normal variant. In the absence of any clinical history, such T-wave abnormalities are considered nonspecific.

In addition, a U wave (↑) (the positive deflection following the T wave) can be seen in leads V1-V2. A U wave may be normally seen in right precordial leads. These are considered to result from repolarization of the His-Purkinje system. ■

Notes

A 38-year-old woman presents to the emergency department with fatigue and dyspnea on exertion. About 3 weeks prior to developing these symptoms, she recalls having a febrile illness. She now notes swelling of her ankles and is only able to walk about 50 m on level ground before becoming short of breath.

What does her ECG show?

What is the likely diagnosis?

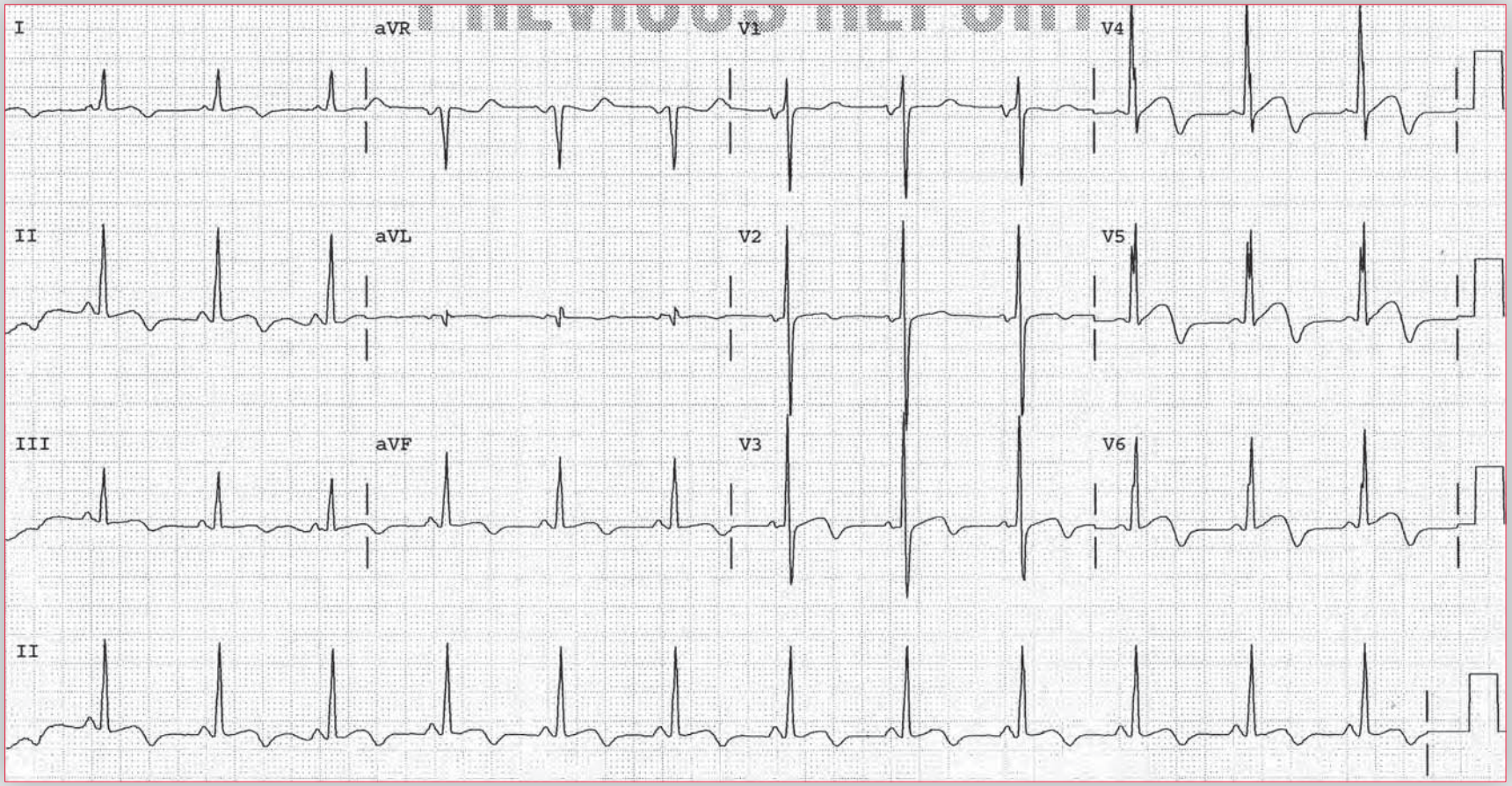

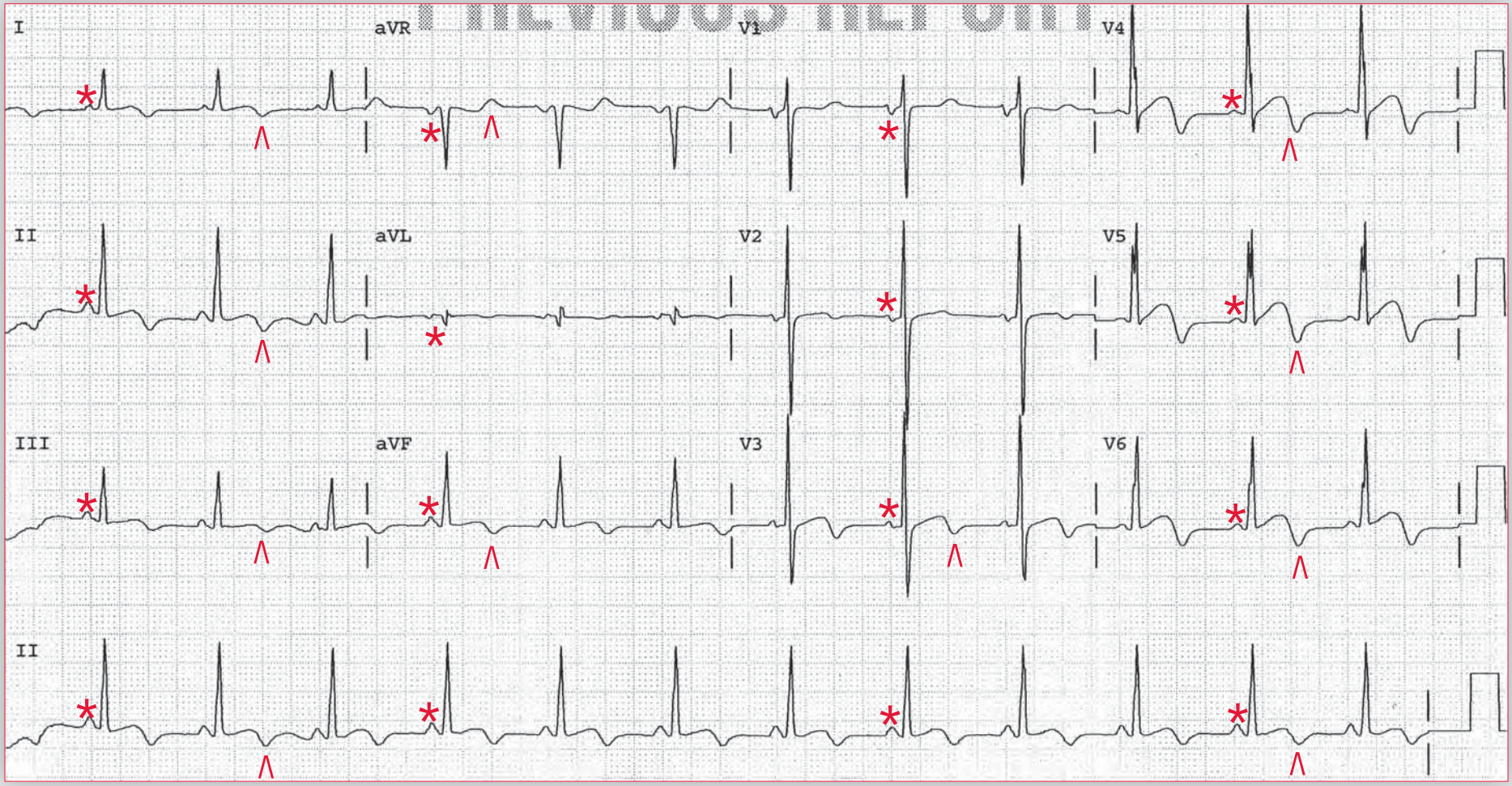

ECG 48 Analysis: Normal sinus rhythm, biphasic (nonspecific) T waves

There is a regular rhythm at a rate of 76 bpm. There is a P wave (*) before each QRS complex, with a stable PR interval (0.16 sec). The P waves are positive in leads I, II, aVF, and V4-V6 and negative in lead aVR. This is a normal sinus rhythm.

The QRS complex duration is normal (0.08 sec), and the axis is normal, between 0° and +90° (positive QRS complex in leads I and aVF). The QRS complex morphology is normal. The QT/QTc intervals are normal (380/430 msec).

The T waves (^) are abnormal and have a biphasic morphology in most of the leads; the T wave in lead aVR is positive, although the normal T wave in this lead is negative. These T-wave abnormalities are nonspecific and may be seen in various conditions, including ischemia, myocarditis/pericarditis, metabolic or pH abnormalities, old myocardial infarction, dilated or infiltrative cardiomyopathy, or left ventricular hypertrophy. Such T-wave abnormalities may also be seen in healthy subjects as a normal variant. T-wave abnormalities must be considered along with a clinical history.

This patient may have viral myocarditis with development of an acute cardiomyopathy as she has clinical evidence of heart failure preceded by a likely viral prodrome. This would account for the T-wave abnormalities. An echocardiogram should be performed to assess left ventricular and right ventricular function. In the setting of a left ventricular ejection fraction less than 0.40, the patient should be initiated on angiotensin-converting enzyme inhibitor and β-blocker therapy. Therapy is directed at relief of symptoms and is also supportive for any hemodynamic abnormalities. In most cases the cardiomyopathy resolves over time. ■

Core Case 49

A 59-year-old man presents with several episodes of retrosternal chest pain occurring with minimal activity. Upon arrival in the emergency department, his pain has resolved. An ECG (49A) is obtained. Initial markers of cardiac

ECG 49A

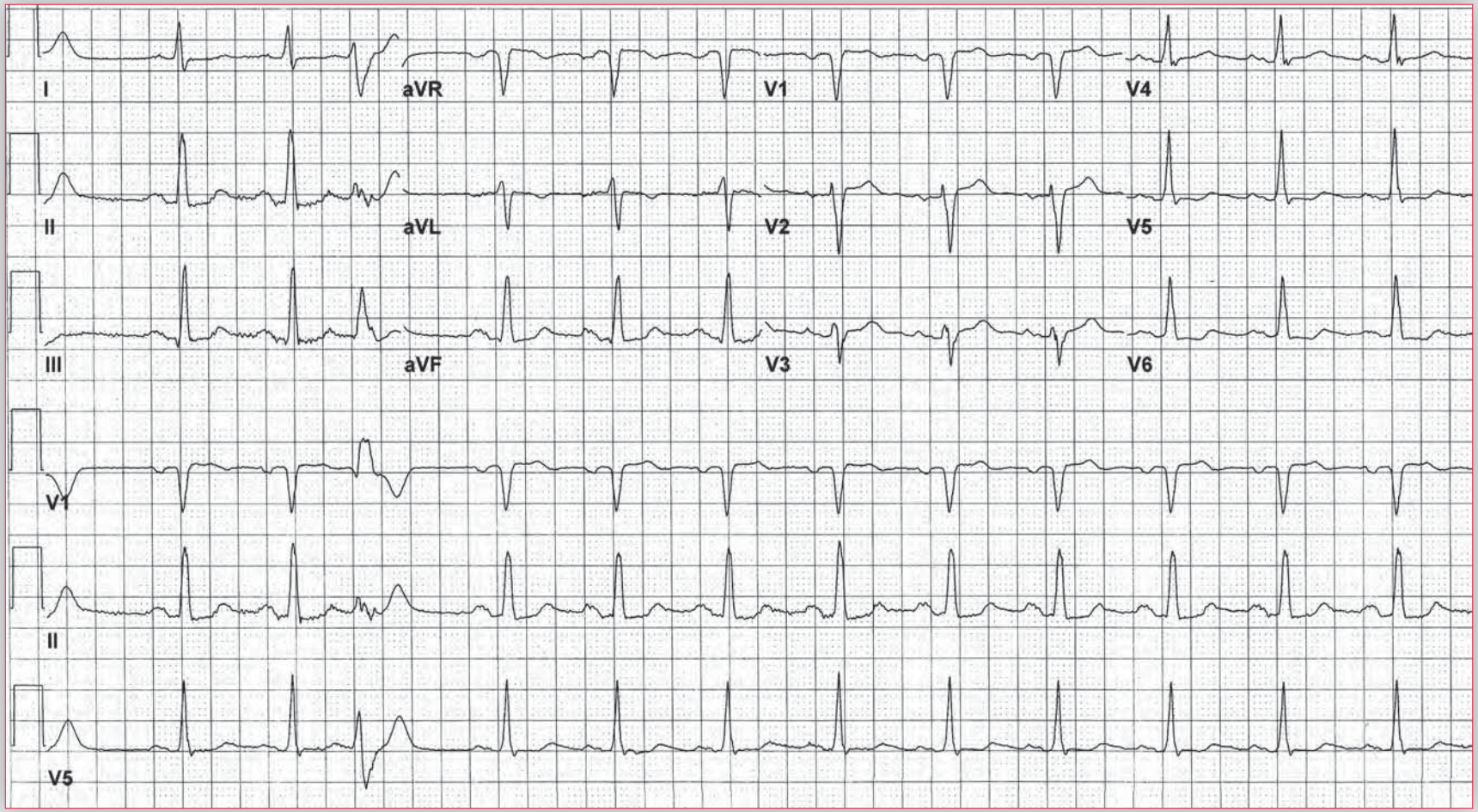

ischemia (creatine kinase [CK], CK-MB, and troponin I) are within normal limits. He is observed overnight, during which he has another episode of chest pain. A second ECG (49B) is obtained about 30 minutes after his chest pain resolved.

What do these ECGs show?
What is the likely diagnosis?
What further testing is indicated?

ECG 49B

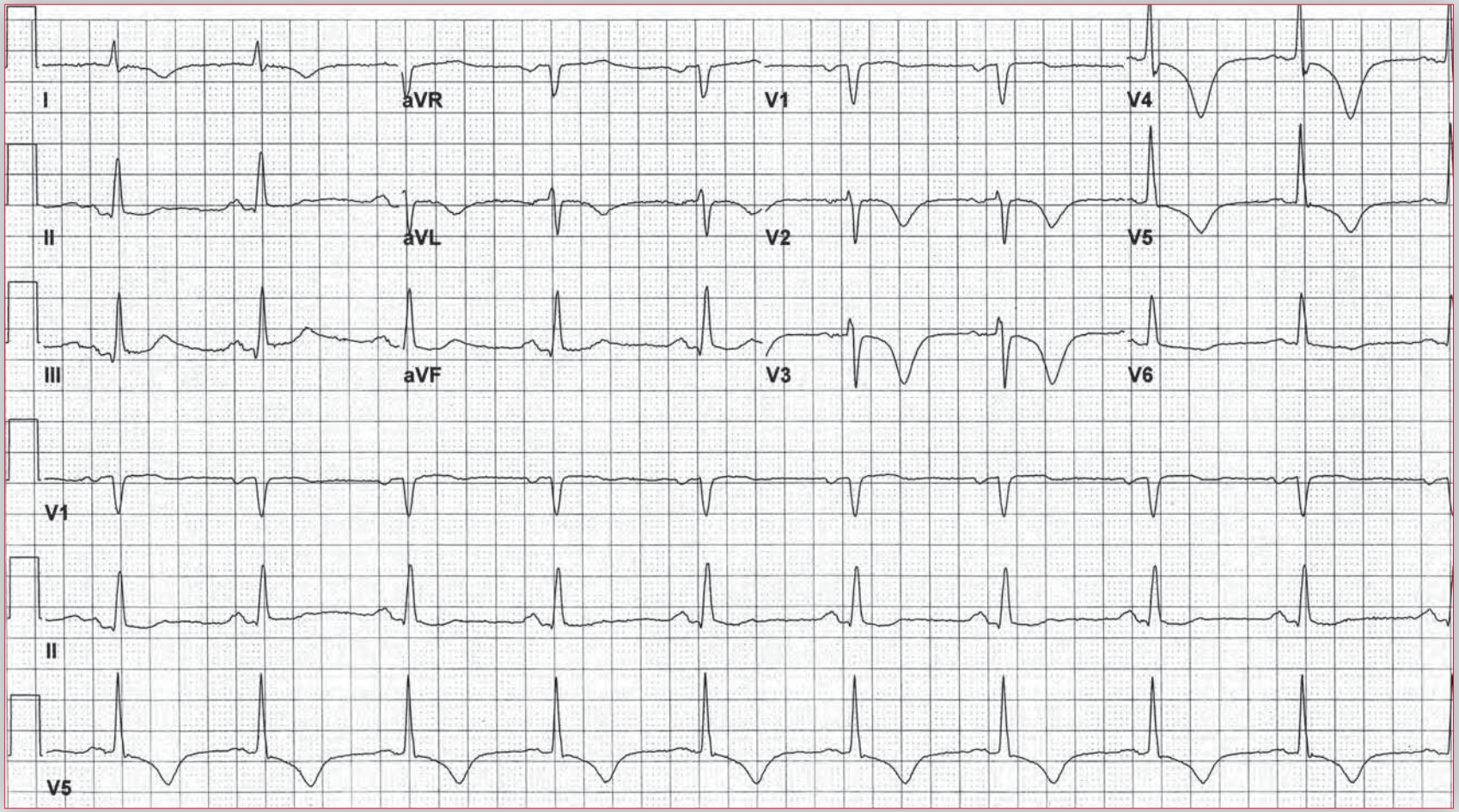

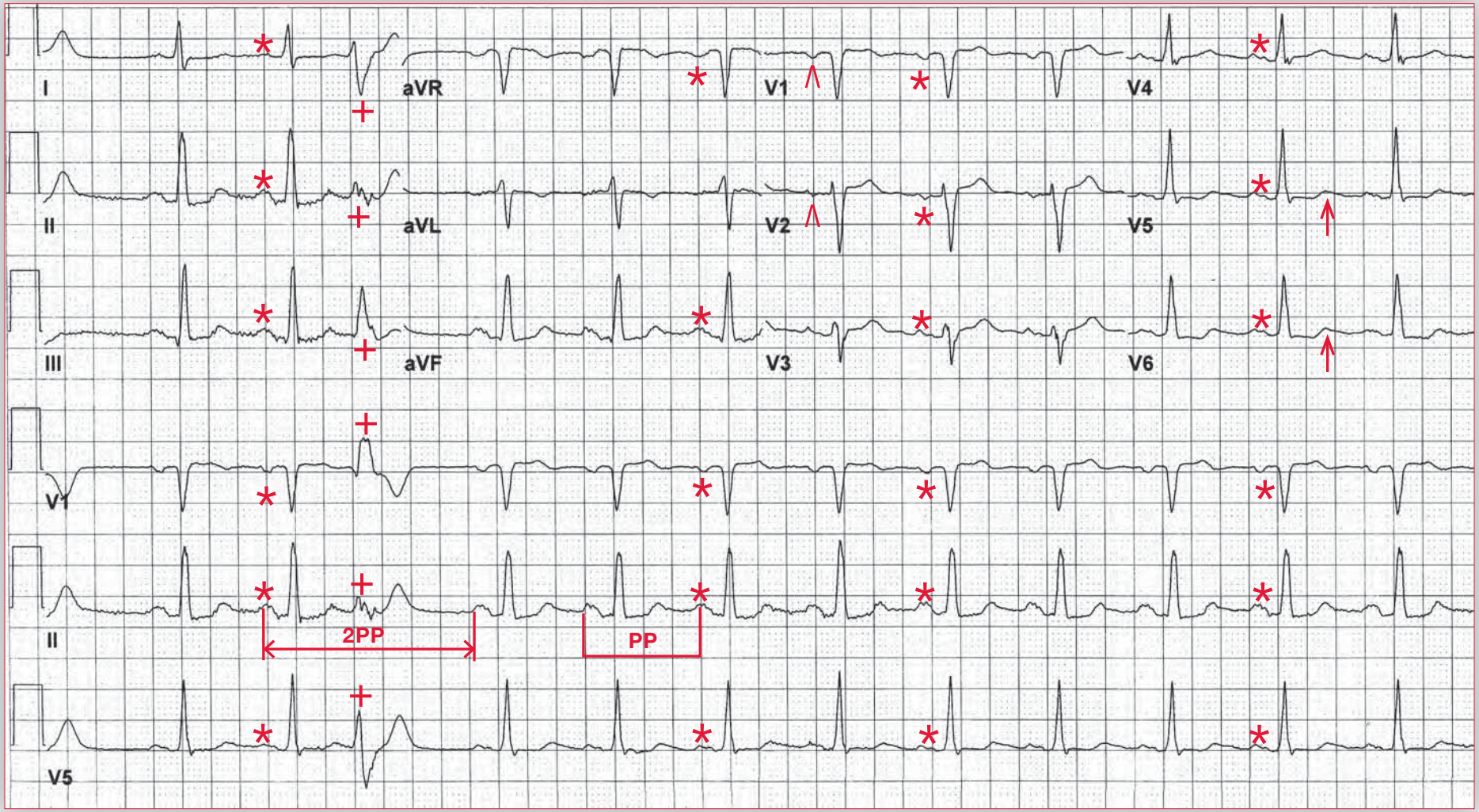

ECG 49A Analysis: Normal sinus rhythm, premature ventricular complex, left atrial hypertrophy, intraventricular conduction delay, nonspecific ST-segment abnormalities

ECG 49A shows a regular rhythm at a rate of 80 bpm. There is a P wave (*) before each QRS complex, with a stable PR interval (0.20 sec). The P waves are positive in leads I, II, aVF, and V4-V6 and negative in lead aVR. This is a normal sinus rhythm. The P wave is negative in lead V1 and biphasic in lead V2 (^). The P waves in leads II, III, aVF, and V4-V6 are broad with slight notching (*). These P-wave abnormalities are characteristic of left atrial hypertrophy.

The third QRS complex (+) is early, wide, and abnormal and does not have any preceding P waves. This is a premature ventricular complex and is followed by a full compensatory pause; that is, the PP interval around the premature complex (↔) is equal to two sinus PP intervals (⊔). This is due to the fact that there has been an on-time sinus impulse (the P wave is simultaneous with the premature ventricular complex and hence not seen) that is blocked within the AV node as a result of retrograde conduction from the premature ventricular contraction, which causes the AV node to be refractory and hence there is no antegrade conduction. The next on-time sinus impulse does conduct through the node.

The QRS complex duration is prolonged (0.12 sec), and there is no pattern characteristic of a bundle branch block. Hence this is an intraventricular conduction delay. The QRS axis is normal, between 0° and +90° (positive QRS complex in leads I and aVF). The QT/QTc intervals are normal (360/420 msec and 320/370 msec when corrected for prolonged QRS complex duration). Noted are nonspecific ST-segment abnormalities (↑), with flattening of the ST segment in leads V5-V6.

continues

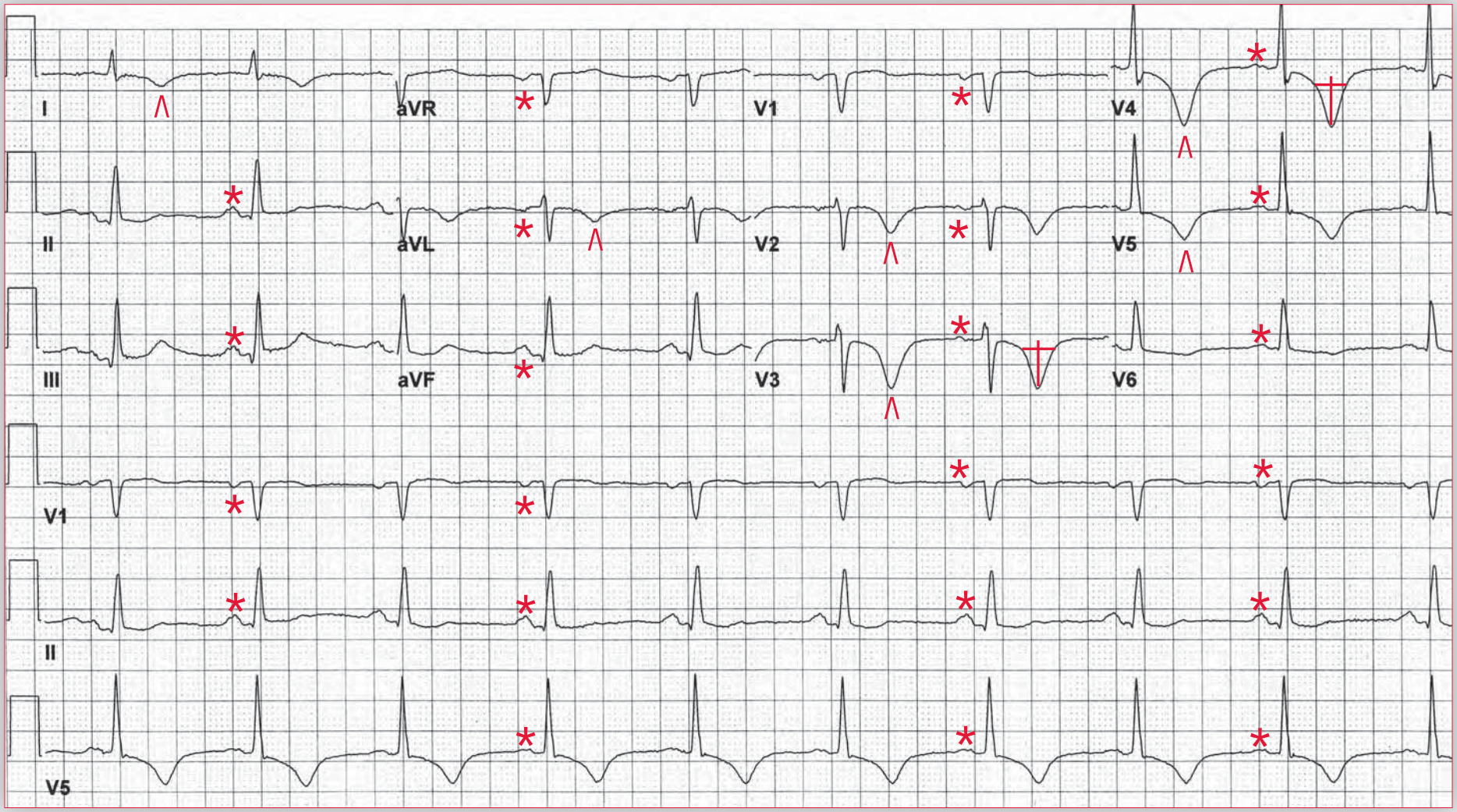

ECG 49B Analysis: Ischemic T-wave abnormalities (Wellens' T waves), prolonged QT interval

ECG 49B was taken shortly after the second episode of prolonged substernal chest discomfort. There were no elevations of the cardiac enzymes. The rhythm is regular at a rate of 60 bpm. The P waves (*), PR interval, and QRS complexes are identical to those in **ECG 49A**. The QT/QTc intervals are prolonged (560/560 msec), even when the prolonged QRS complex duration is considered (520/520 msec). In addition, there are new T-wave inversions (^) in leads I, aVL, and V2-V5. The T waves are deeply and symmetrically inverted, and the QT/QTc interval is prolonged. These T-wave changes have been referred to as Wellens' T waves (pattern) and have been associated with a significant lesion in the proximal left anterior descending artery (LAD).

This patient should undergo urgent coronary angiography rather than noninvasive stress testing. The pretest probability of significant LAD disease is high, and there is a risk for precipitating a myocardial infarction with stress testing as it is likely that there is a very tight stenosis and the vessel is subtotally occluded. Of note, the QT prolongation is a further clue that there may be ongoing myocardial ischemia. ■

Notes

A 28-year-old intravenous drug user is admitted with fever and altered mental status. On admission he is tachycardic at 110 bpm and has a blood pressure of 148/30 mm Hg. Physical exam reveals a soft diastolic murmur at the upper sternal border (base of the heart).

What does his ECG show?

What is the likely diagnosis?

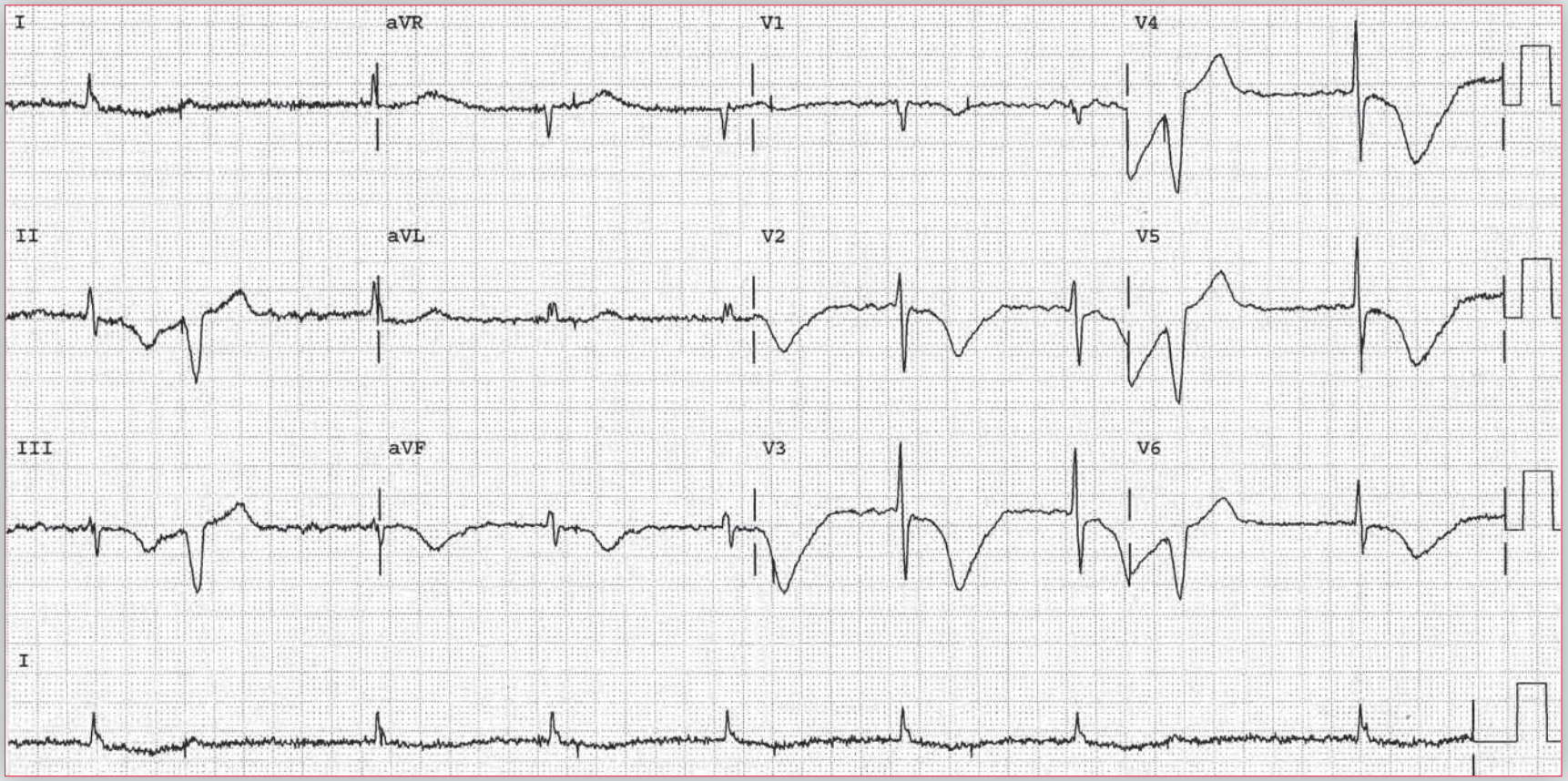

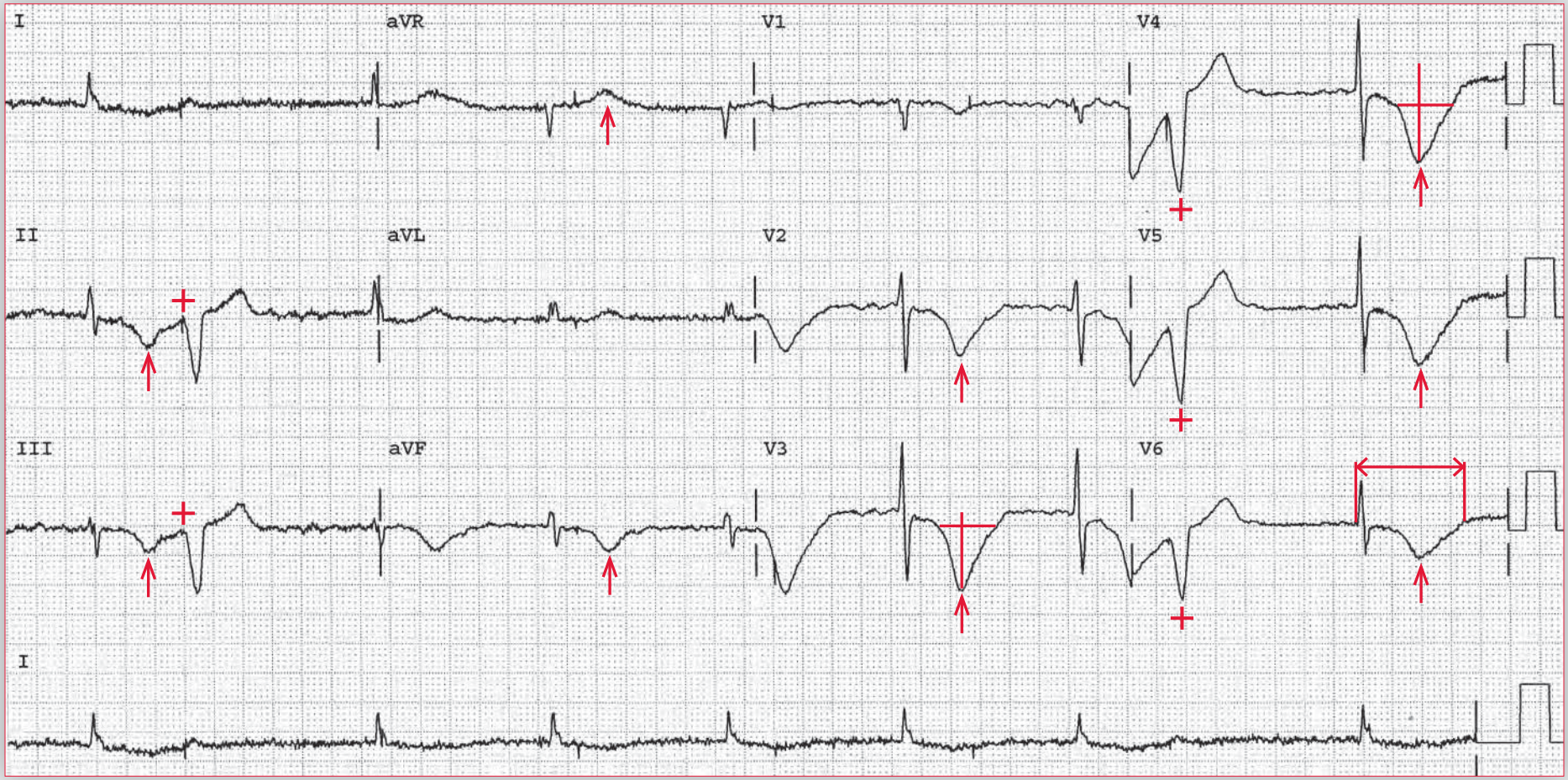

ECG 50 Analysis: Junctional rhythm, premature ventricular complexes, cerebral T waves, prolonged QT interval

There is a regular rhythm at a rate of 50 bpm. There are no obvious P waves before or after the QRS complexes, although baseline artifact makes this uncertain. However, it is likely that this is a junctional rhythm. The second and eighth QRS complexes (+) are early, wide, and abnormal; they are premature ventricular complexes.

The QRS complex duration is normal (0.08 sec), and the axis is physiologically leftward, between 0° and –30° (positive QRS complex in leads I and II and negative QRS complex in lead aVF). There are diffuse, deep T-wave inversions (↑) (the positive T wave in lead aVR is actually inverted) that are asymmetric, with an initial portion of the T wave (descent) that is faster than the terminal portion (ascent). This is in contrast to the normal T wave, which has a slower initial portion or upstroke (ascent) and a faster terminal portion or downstroke (descent). In addition, there is significant prolongation of the QT/QTc intervals (↔) (720/660 sec). There is no ST-segment depression. The finding of deeply inverted and asymmetric T waves along with marked prolongation of the QT interval suggests that these are cerebral T waves, a result of some central nervous system process such as a subarachnoid hemorrhage, cerebral hemorrhage, tumor, head injury, or infection.

This patient has evidence of aortic insufficiency (wide pulse pressure, tachycardia, diastolic murmur) attributable to acute bacterial endocarditis. The clinical presentation of altered mental status suggests that he possibly has developed a brain abscess secondary to embolism of a bacterial vegetation from the aortic valve to the brain. The ECG findings are typical of an acute central nervous system insult, which is most likely cardioembolic in this context. Therapy for endocarditis should be emergently instituted and acute drainage of a brain abscess, if present, performed. Replacement of the aortic valve usually is performed once blood cultures are negative. If the patient remained stable, an aortic valve replacement would generally be performed after several weeks of antibiotic therapy. However, if there were worsening of the aortic regurgitation, development of AV conduction abnormalities (suggesting an abscess of the septum), or recurrent cerebral emboli, valve surgery would be performed more urgently. ■

Notes

Practice ECGs

Practice Case 51

A 54-year-old man collapses while working out at a gym. He was observed riding a stationary bicycle when he slowed down and collapsed, falling off the bike. A bystander could not feel a pulse and initiated CPR immediately. An employee connected an automated external defibrillator (AED), which advised a shock. After a single shock the patient became responsive and regained a pulse. Emergency medical services arrived shortly thereafter and obtained a 12-lead ECG.

What does his ECG show?

What is the likely diagnosis?

What likely caused his collapse?

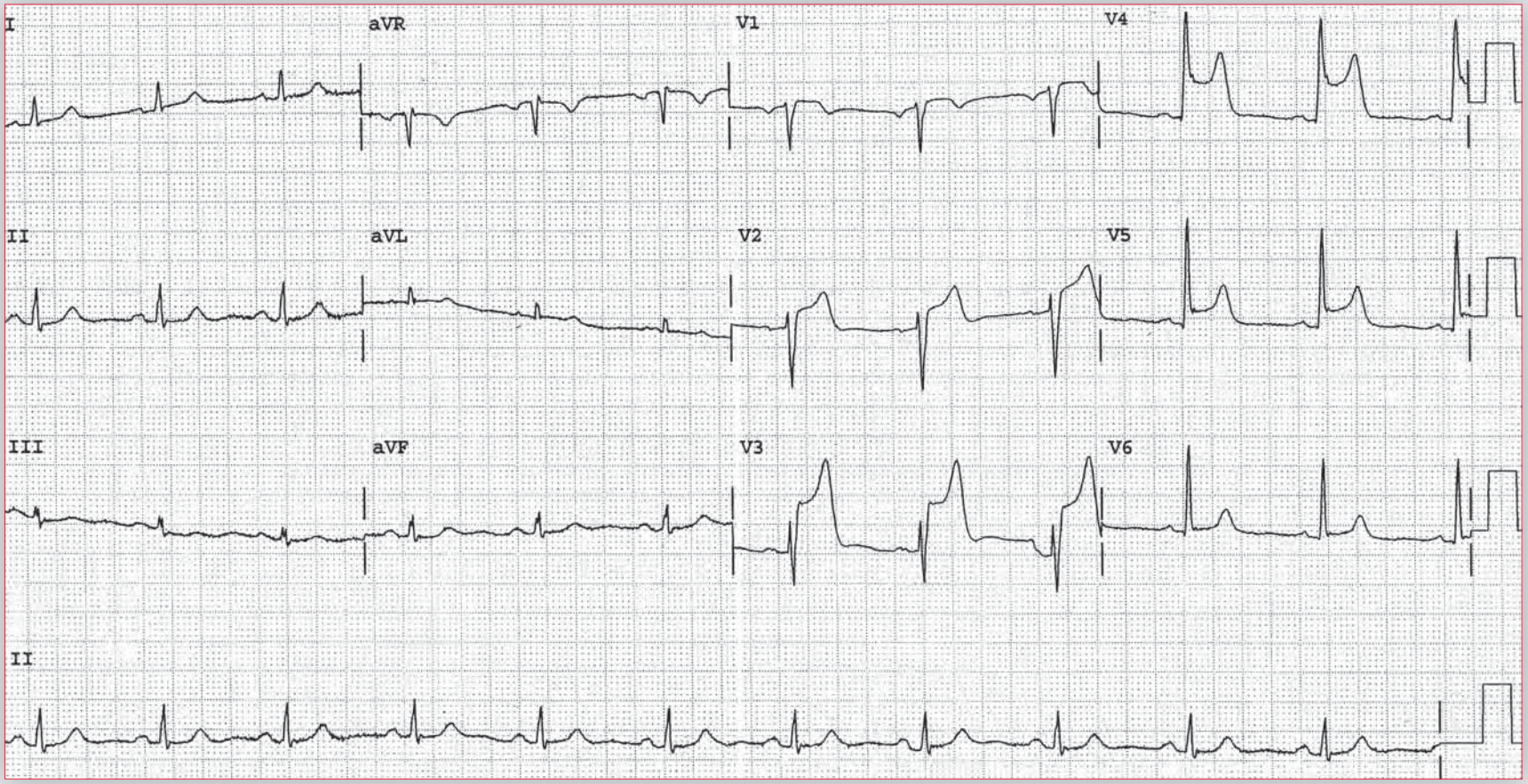

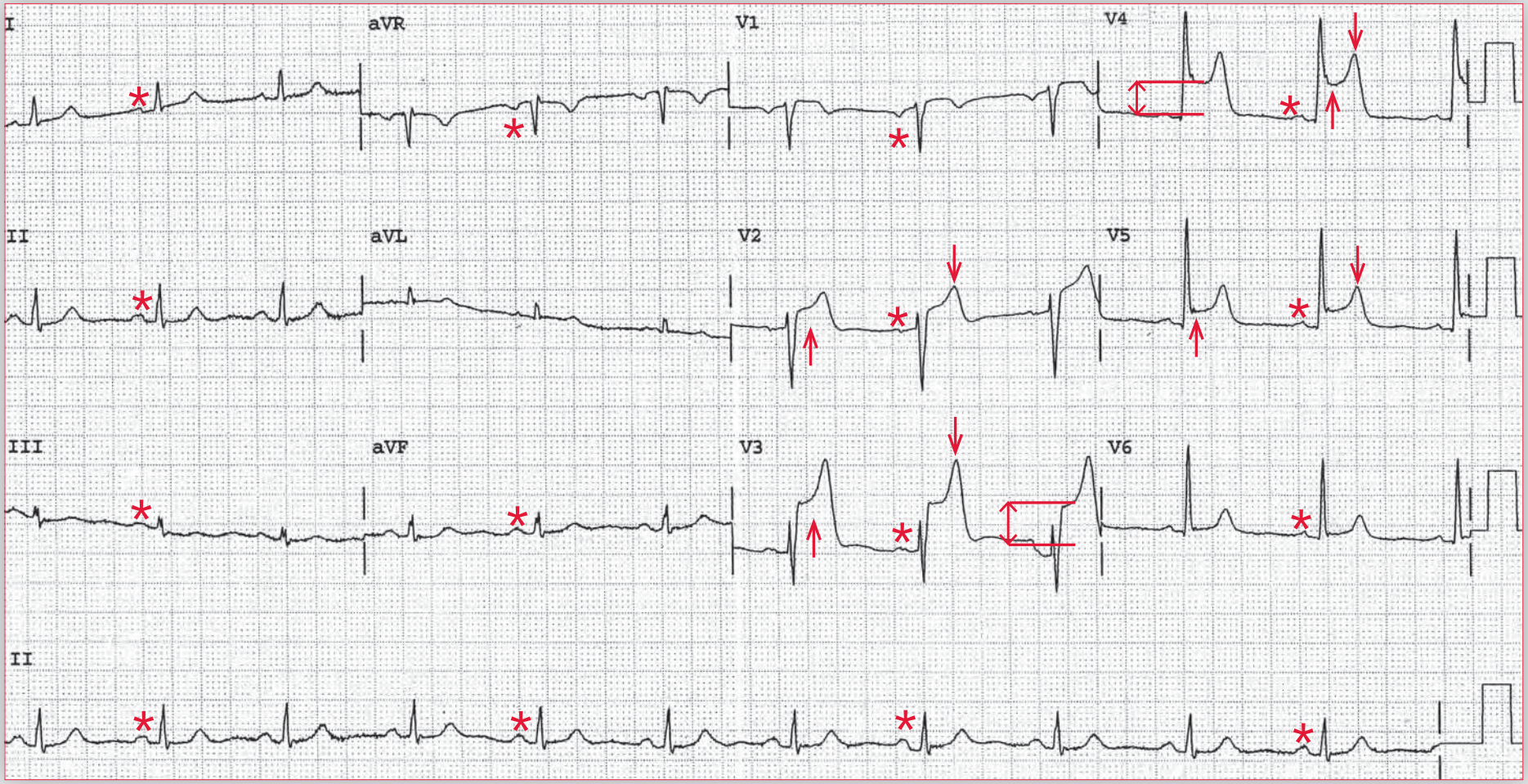

ECG 51 Analysis: Normal sinus rhythm, left atrial hypertrophy, acute anterior wall ST-segment elevation myocardial infarction (STEMI)

There is a regular rhythm at a rate of 68 bpm. There is a P wave (*) before each QRS complex, with a stable PR interval (0.16 sec). The P wave is upright in leads I, II, aVF, and V4-V6 and negative in lead aVR. The P wave in lead V1 is negative, suggesting left atrial hypertrophy. This is a normal sinus rhythm.

The QRS complex duration (0.08 sec) and morphology are normal. The axis is normal, between 0° and +90° (positive QRS complex in leads I and aVF). The QT/QTc intervals are normal (360/380 msec). The T waves (↓) are peaked and symmetric in leads V3-V5, and there is significant ST-segment elevation (↑) of up to 9 mm (↕) in leads V2-V5. The ST segments still have a concave morphology. This is an acute anterior wall ST-segment elevation myocardial infarction (STEMI) involving primarily the left ventricular apex.

An acute MI is identified by the presence of localized ST-segment elevation, hyperacute T waves (tall, peaked, and symmetric), and reciprocal ST-segment depressions (due to the same ST-segment changes viewed from another angle or direction). The location of the ST-segment elevations identifies the region of the myocardium involved.

This patient suffered a cardiac arrest, likely attributable to an acute anterior STEMI complicated by ventricular tachycardia or ventricular fibrillation. Normal sinus rhythm was restored with a single shock delivered by an automated external defibrillator (AED). AEDs are designed to be operated by first responders at a cardiac arrest. They contain sophisticated software that analyzes the rhythm and advises a shock if ventricular fibrillation or rapid ventricular tachycardia is detected. These devices are useful in reducing the time between the onset of an unstable tachyarrhythmia and restoration of a perfusing rhythm, particularly if there is a delay in access to emergency medical services.

Once brought to the hospital, the patient is a candidate for urgent catheterization and primary angioplasty and stenting. The use of a thrombolytic is relatively contraindicated in a patient who has undergone CPR, particularly when CPR has been traumatic or lasted longer than 10 minutes. ■

Notes

Practice Case 52

A 48-year-old man presents to the emergency department with 24 hours of intermittent but severe retrosternal chest discomfort. He was slow to seek medical attention because he believed that the discomfort would abate. Upon arrival at the hospital, he is taken urgently for coronary angiography. He states that he had a previous myocardial infarction (MI) but is unable to provide details.

What does his ECG show?

What do you expect the angiogram to show?

What is the likely diagnosis?

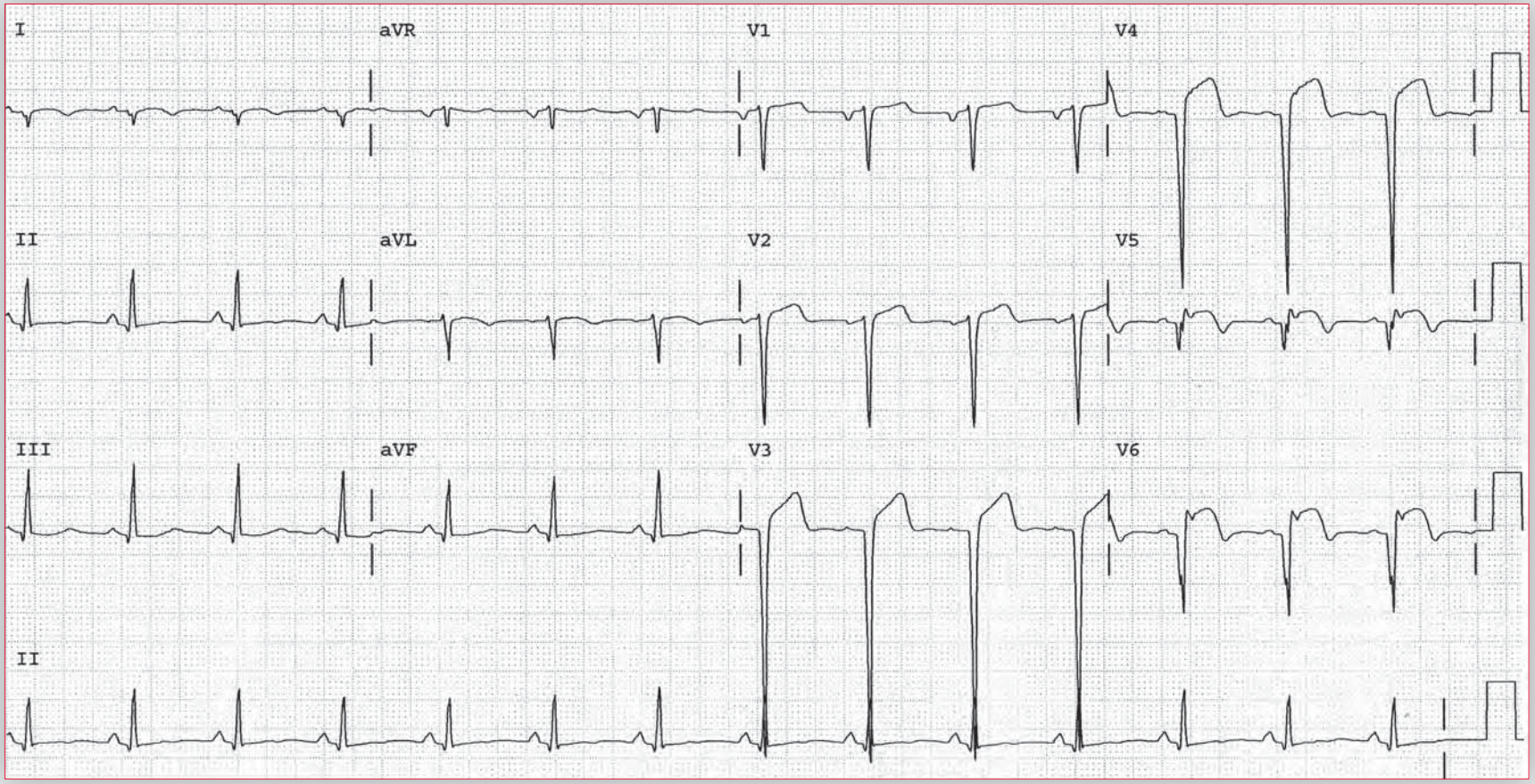

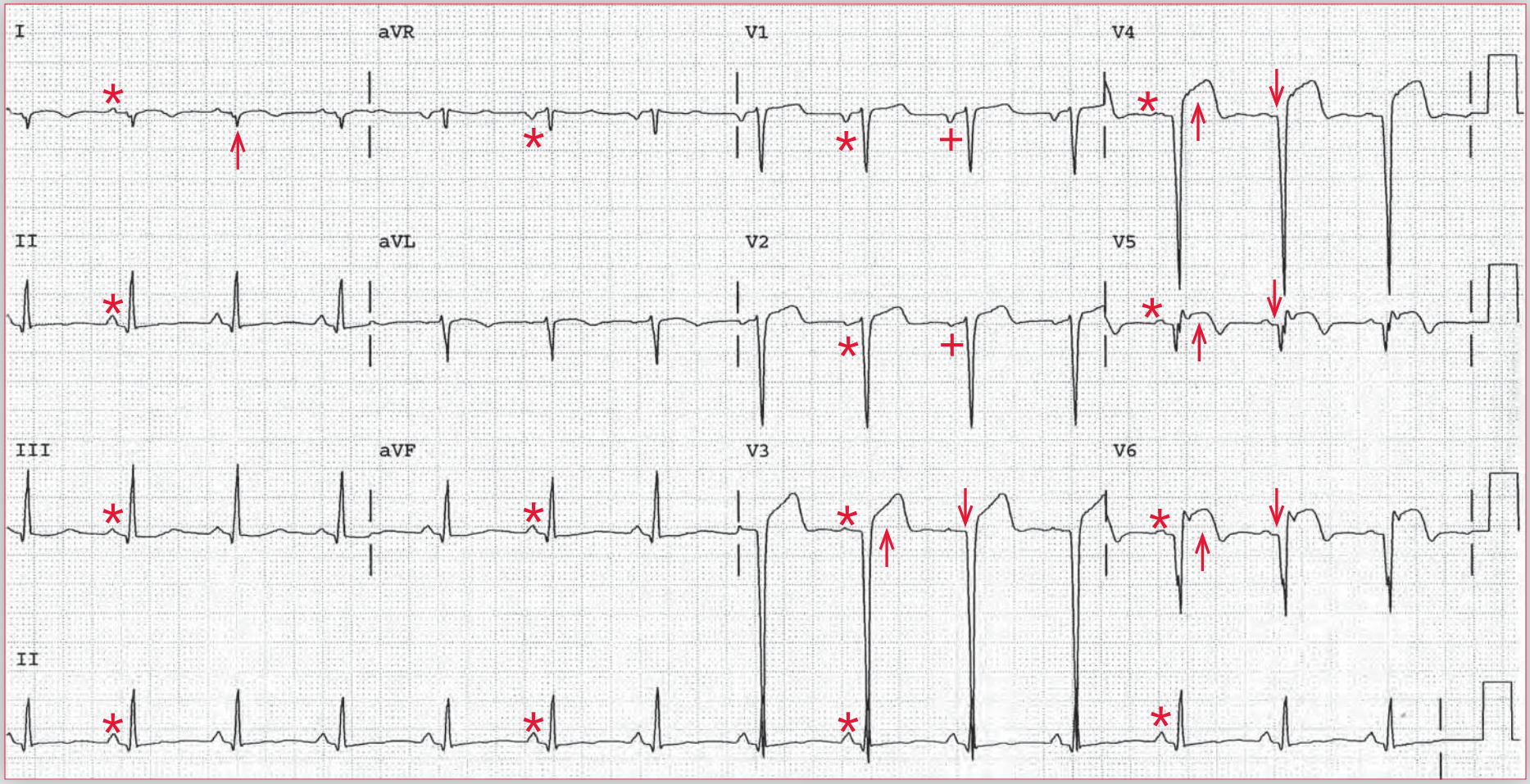

ECG 52 Analysis: Normal sinus rhythm, left atrial hypertrophy, old lateral wall MI, acute anterior wall ST-segment elevation myocardial infarction (STEMI), right axis deviation due to an old lateral wall MI

There is a regular rhythm at a rate of 82 bpm. There is a P wave (*) before each QRS complex with a stable PR interval (0.16 sec). The P wave is upright in leads I, II, aVF, and V4-V6 and negative in lead aVR. Hence this is a normal sinus rhythm. The P wave is negative (+) in leads V1-V2, suggesting left atrial hypertrophy.

The QRS complex duration is normal (0.08 sec). The QT/QTc intervals are normal (320/370 msec). There is a Q wave in lead I (↑), diagnostic for a lateral wall myocardial infarction (MI). As a result of the Q wave in lead I (negative QRS complex) and the positive QRS complex in lead aVF, the axis is rightward. However, the right axis deviation is not caused by a conduction abnormality resulting from a left posterior fascicular block (QRS morphology in lead I is rS) but rather is due to the lateral infarction.

In addition, there are Q waves (QS complex) in leads V3-V6 (↓), diagnostic for an extensive anterior wall MI. ST-segment elevations are noted above the baseline (TP segment) in leads V3-V6 (↑). If the patient had a recent infarction, the ST-segment changes would be due to the acute ST-segment elevation myocardial infarction (STEMI) that is evolving. If the clinical history were that of a previous MI occurring weeks or years prior to obtaining the ECG, these persistent ST-segment changes would represent an aneurysm in the area of the previous infarction.

Given the history, this patient is likely to have had an acute thrombotic occlusion of his proximal left anterior descending artery (LAD) approximately 24 hours prior to presentation, when his symptoms first began. Since he is so late in presenting to the hospital, he has developed deep Q waves across the precordium and hence an intervention would not likely be helpful in reducing the extent of the infarction. However, given the presence of ongoing discomfort indicating ongoing coronary ischemia (post-MI angina), the ST-segment elevations would indicate that the ECG changes of an acute MI were evolving. Since the acute MI is of the anterior wall and there are ongoing symptoms (suggesting some residual viable myocardium), a percutaneous coronary intervention of the LAD would be indicated primarily for symptom relief. There would not likely be any survival benefit at this point in time. ■

Notes

Practice Case 53

A 35-year-old woman from India is in the United States visiting her family. She develops dyspnea and pedal edema after eating a large salty meal at a family celebration. She is taken to the emergency department where she is found on exam to have a blood pressure of 106/68 mm Hg and heart sounds that are regular with an early diastolic opening snap followed by a low-pitch grade II/IV diastolic rumble at the apex. She has diffuse rales and trace pedal edema.

What does her ECG show?

What is the likely diagnosis?

What therapy is indicated?

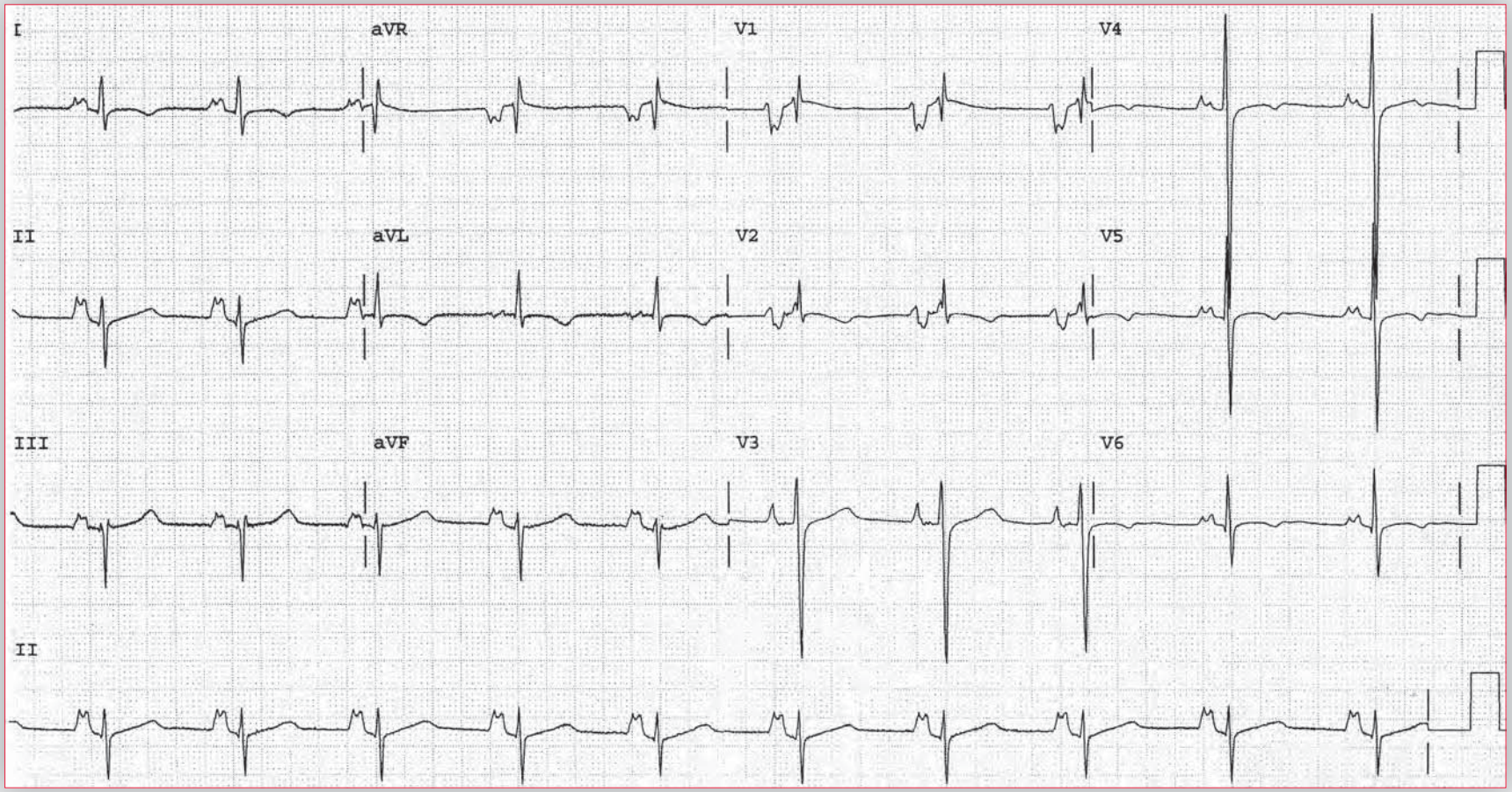

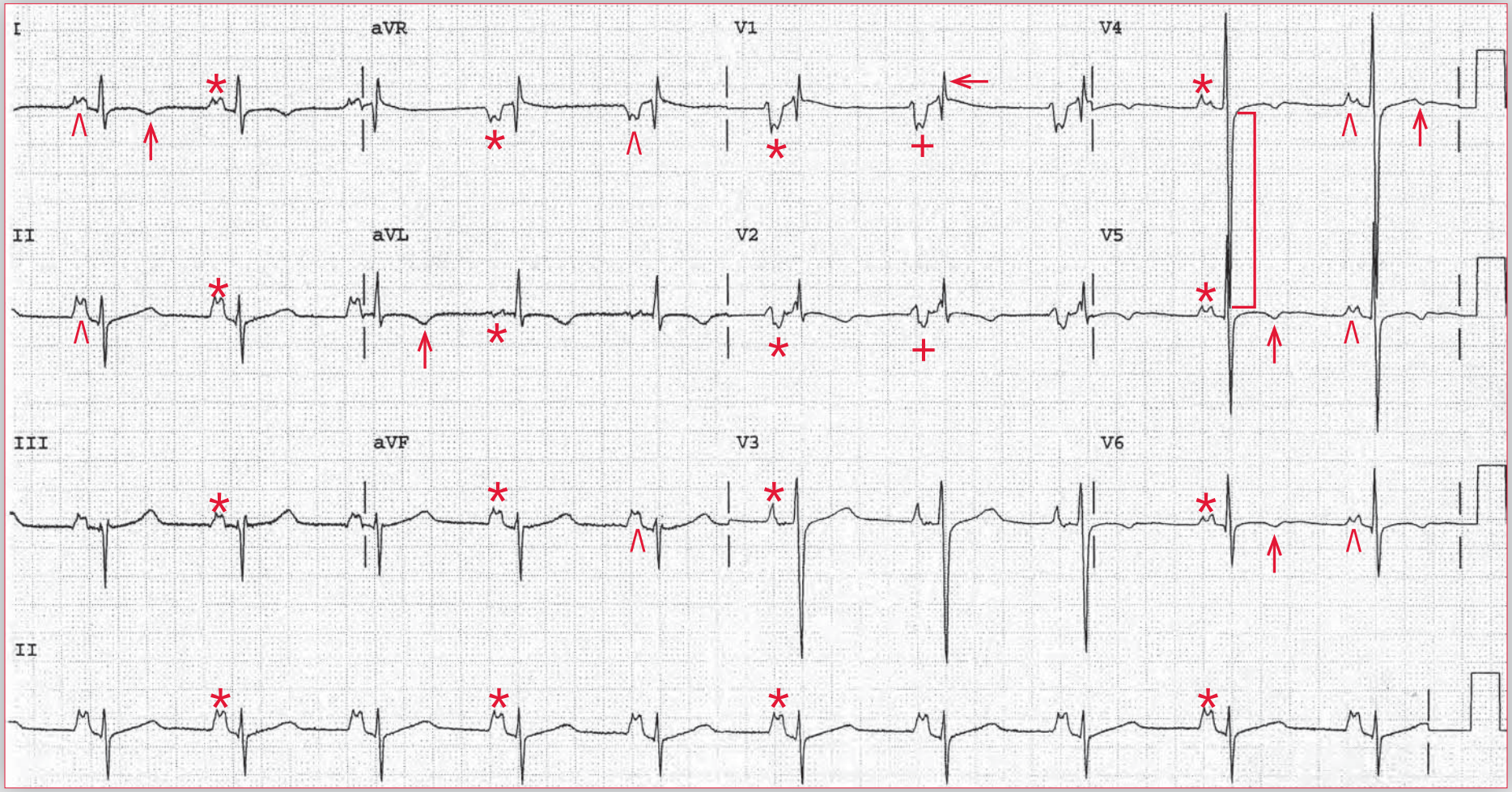

ECG 53 Analysis: Normal sinus rhythm, first-degree AV block, left atrial hypertrophy (abnormality), left anterior fascicular block, possible left ventricular hypertrophy, nonspecific ST-T wave changes

There is a regular rhythm at a rate of 60 bpm. There is a P wave (*) before each QRS complex, with a stable PR interval (0.22). The P wave is positive in leads I, II, aVF, and V4-V6 and negative in lead aVR. Hence this is a normal sinus rhythm. The P wave has a markedly increased amplitude (0.4 mV) and is very broad (0.16 sec). There is striking notching of the P wave seen in leads I, II, aVR, aVF, and V4-V6) (^), and there is a marked negative component seen in leads V1-V2 (+). Hence this is P mitrale, which is indicative of left atrial hypertrophy or a left atrial abnormality.

The QRS complex duration is normal (0.08 sec), and there is an extreme left axis deviation, between –30° and –90° (QRS complex is positive in lead I and negative in leads II and aVF), indicating a left anterior fascicular block. The QT/QTc intervals are normal (400/400 msec). The QRS complex has a normal morphology, although there is an RSR′ morphology in lead V1 (←), indicative of conduction delay to the right ventricle; this is often a normal variant. However, it is possible that this R′ represents right ventricular hypertrophy. The S wave in lead V4 is 34 mm ( ]), suggesting possible left ventricular hypertrophy. However, there are no other features of hypertrophy present and, given the young age of the patient, this could be a normal finding. There are nonspecific ST-T wave changes in leads I, aVL, and V4-V6 (↑).

The physical examination reveals an opening snap occurring in diastole after S2; this is due to the opening of a nonpliable mitral valve leaflet. Along with a diastolic rumble, this is pathognomonic for mitral stenosis. The most likely etiology for the patient's mitral stenosis is rheumatic heart disease, which is common in India. The clinical history suggests that with volume overload, there is a further increase in left atrial and hence pulmonary venous pressure, resulting in evidence of pulmonary congestion.

As a result of the stenotic mitral valve, there is development of left atrial hypertrophy so as to increase the pressure generated by the left atrium in an attempt to force blood through the smaller mitral valve orifice and fill the left ventricle in diastole. The presence of significant left atrial hypertrophy increases the risk for atrial fibrillation and, in association with mitral stenosis, is a major risk factor for stroke.

In general, the left ventricle is not affected in mitral stenosis, so the presence of prominent voltage may be a normal finding in a young patient, although it might also reflect left ventricular hypertrophy due to another condition, such as hypertension, mitral regurgitation, or aortic valve involvement.

When mitral stenosis progresses and becomes more severe, there is an increase in pulmonary artery pressure and right-sided pressure. The ECG can progress in parallel with hemodynamic changes and develop right ventricular hypertrophy (tall R wave in lead V1) and a right axis deviation; on occasion there is also right atrial hypertrophy (biatrial hypertrophy). Therapy for mitral stenosis depends on the anatomy of the mitral valve. In some cases surgical or balloon valvulotomy is effective. If the valve is very calcified or if there is significant mitral regurgitation, mitral valve replacement is necessary. ■

Notes

Practice Case 54

A 38-year-old man who recently immigrated to the United States from Pakistan was found to have a positive tuberculin skin test. He was started on isoniazid (INH) by his primary care provider and took it for 6 weeks. He then developed mild chest discomfort and returned to his primary care provider's office, where an ECG was obtained.

What does his ECG show?

What is the likely diagnosis?

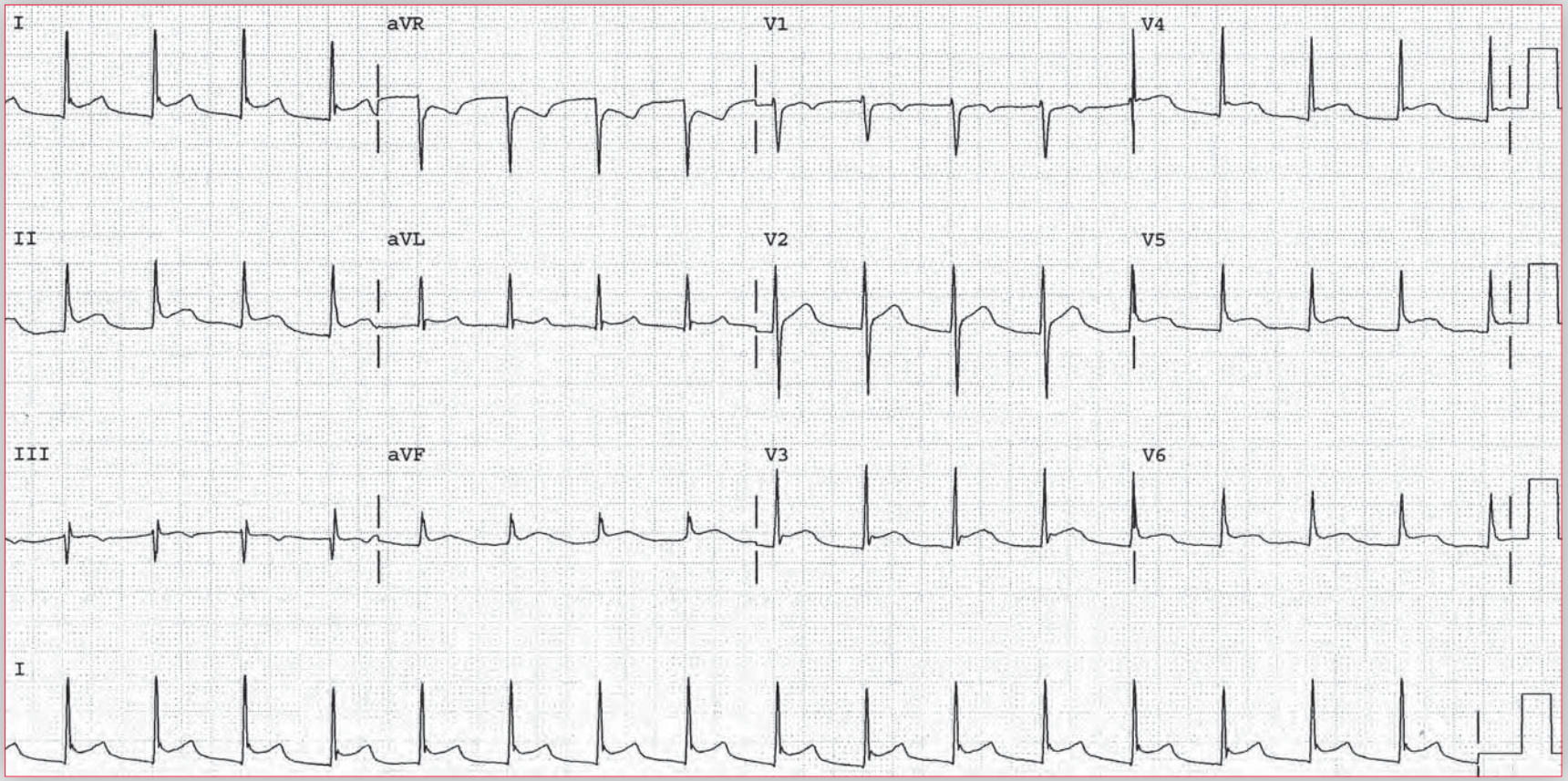

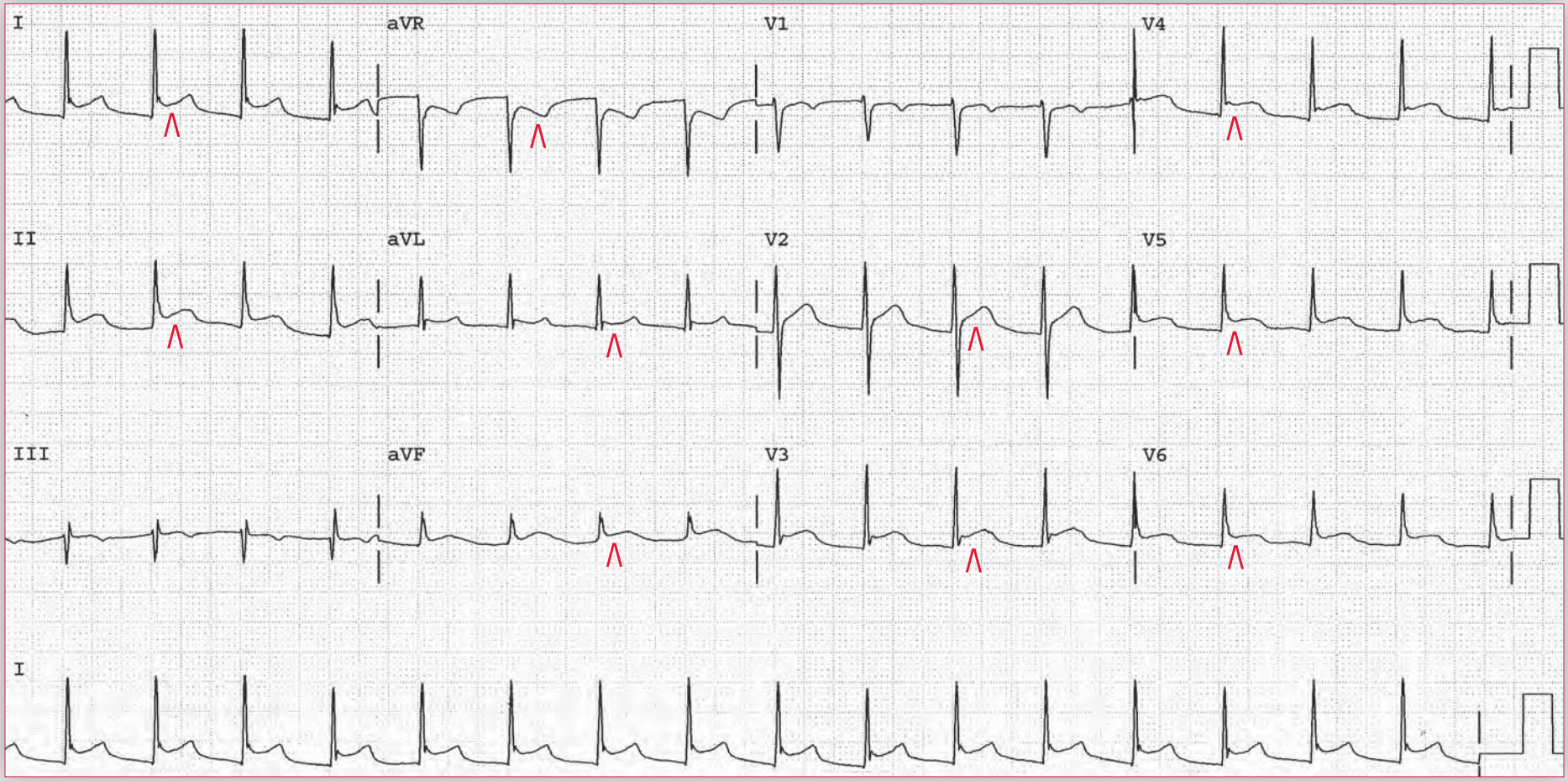

ECG 54 Analysis: Junctional tachycardia, pericarditis

There is a regular rhythm at a rate of 100 bpm. There are no P waves seen before or after any QRS complex. The QRS complex duration is normal (0.08 sec), and there is a normal axis, between 0° and +90° (positive QRS complex in leads I and aVF). This is a junctional tachycardia. The QT/QTc intervals are normal (320/410 msec).

The J points and ST segments (^) are elevated above the baseline (TP segment) in leads I, II, aVR (ST-segment depression in this lead is actually ST-segment elevation), aVL, aVF, and V2-V6. This is, therefore, pericarditis. The concave morphology of the ST segment is maintained, and the T-wave morphology is normal (asymmetric).

This patient may have drug-induced pericarditis caused by isoniazid (INH; which can cause a lupus-like syndrome). This should be treated with withdrawal of the INH therapy and initiation of NSAID therapy. If the patient's symptoms do not resolve with these interventions, the clinician should consider the possibility of active tuberculous pericarditis. An echocardiogram should be ordered to evaluate for a pericardial effusion. If an effusion is present, pericardiocentesis should be performed as a diagnostic technique; the presence of tamponade requires pericardiocentesis as a therapeutic intervention. ■

Notes

Practice Case 55

A 68-year-old man is seen in a preoperative clinic for risk optimization before undergoing elective abdominal aortic aneurysm repair. He has hypertension and a 40 pack-year smoking history. He denies any chest pain but lives a sedentary lifestyle. He has trouble climbing a single flight of stairs due to shortness of breath. Prior to being found to have an abdominal aortic aneurysm on his first visit with a primary care provider, he had not sought any medical care. Until recently, he took no medications but has been started on a daily aspirin and lisinopril.

What does his ECG show?

What is the likely diagnosis?

What further workup is indicated?

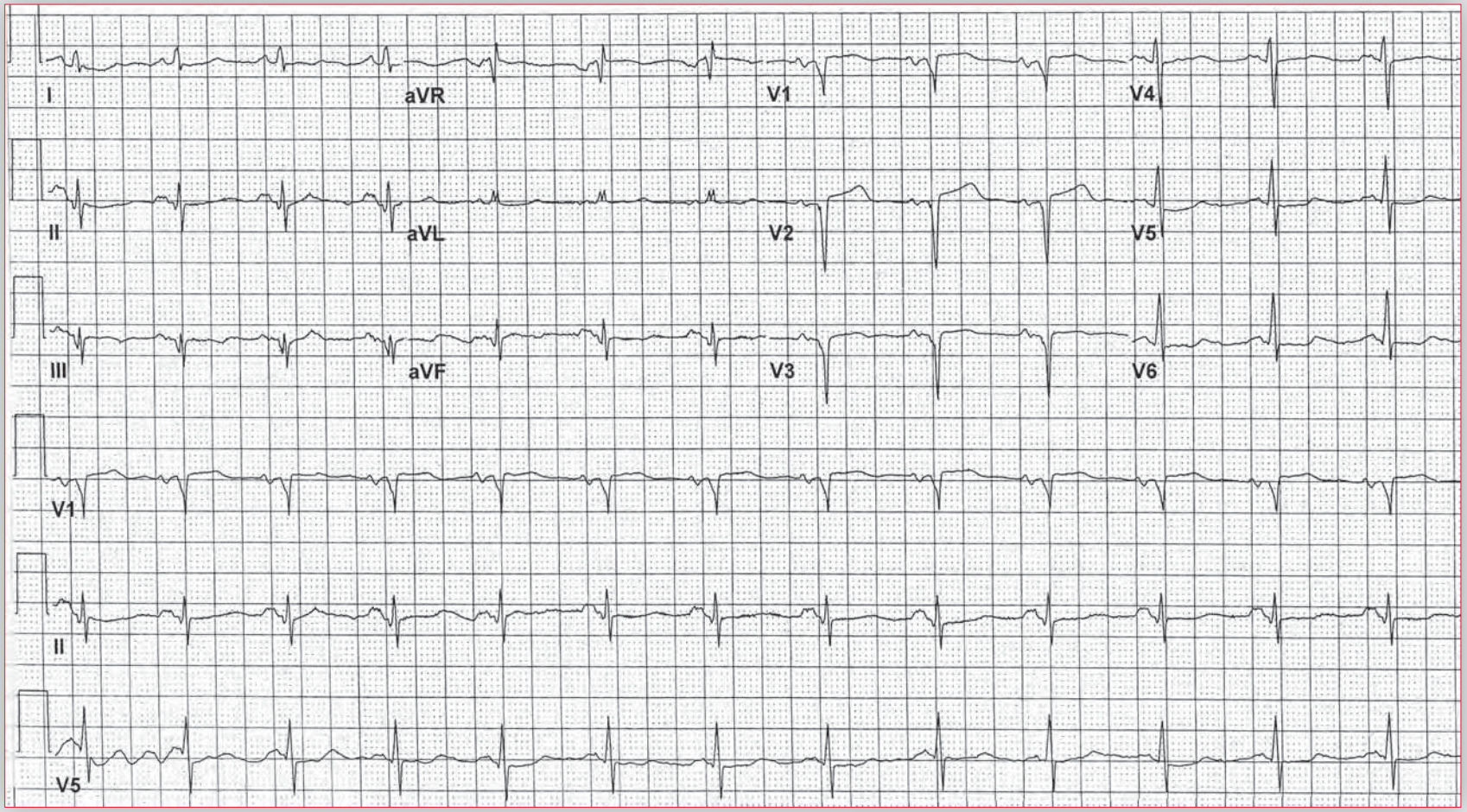

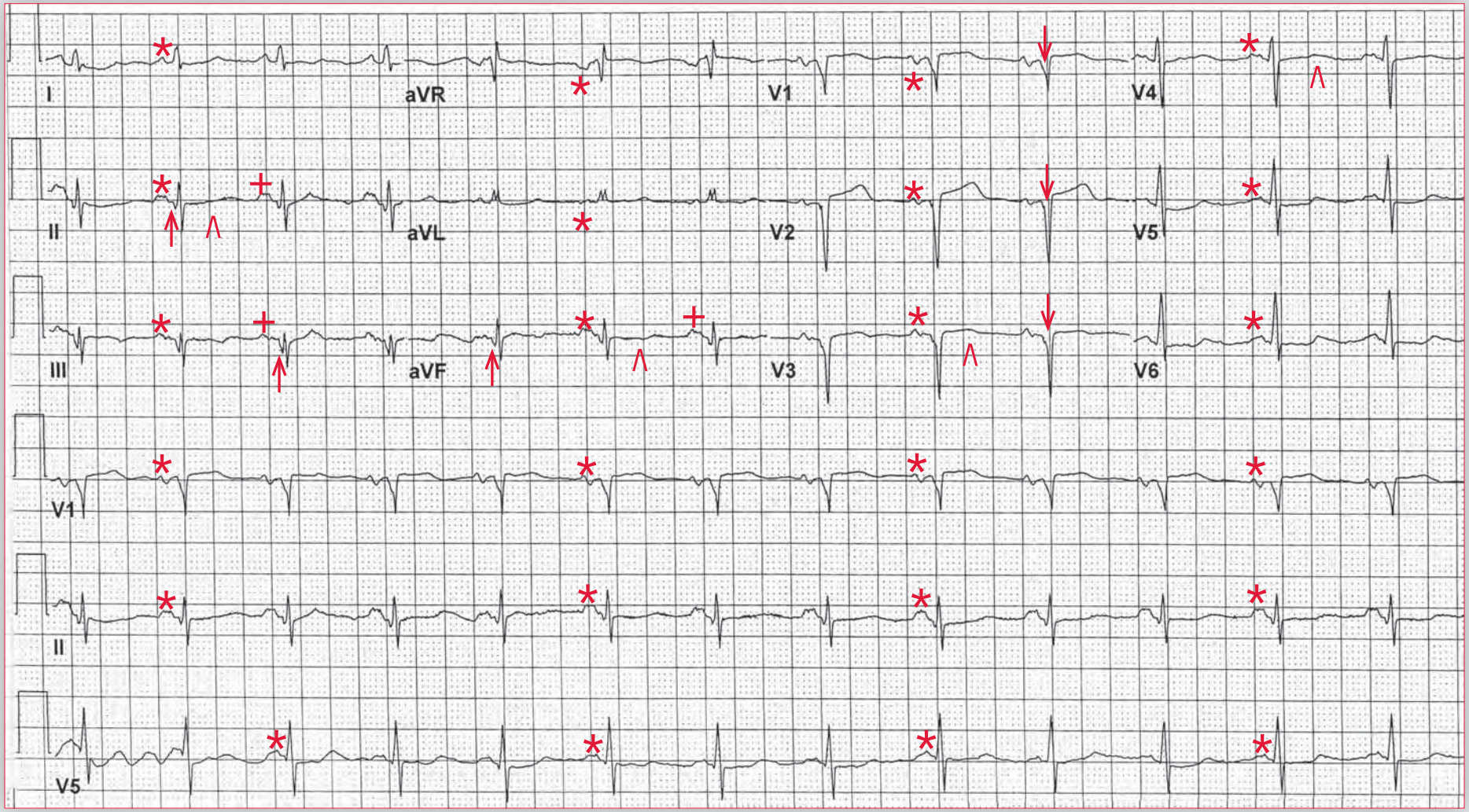

ECG 55 Analysis: Normal sinus rhythm, left atrial hypertrophy (abnormality), nonspecific ST-T wave changes, old anteroseptal myocardial infarction (MI), old inferior wall MI

There is a regular rhythm at a rate of 80 bpm. There is a P wave (*) before each QRS complex, and the PR interval is stable (0.14 sec). The P wave is positive in leads I, II, aVF, and V4-V6 and negative in lead aVR. This is a normal sinus rhythm. The P wave (+) is broad and slightly notched in leads II, III, and aVF, suggesting that left atrial hypertrophy may be present.

The QRS complex duration is normal (0.08 sec). The axis is normal, approximately 0°, with a positive QRS complex in lead I and a biphasic QRS complex in lead aVF. The QT/QTc intervals are normal (360/420 msec). There are Q waves (↑) in leads II, III, and aVF, which are diagnostic for an old inferior wall myocardial infarction (MI). In addition, there are Q waves (↓) in leads V1-V3, which are characteristic of an anteroseptal MI. Lastly, there are diffuse nonspecific ST-T wave changes (^).

A chronic or old MI is identified by the presence of abnormal Q waves, defined as any Q wave in leads V1-V3 or a Q wave 0.03 to 0.04 second or longer in lead I, II, aVF, or V4-V6 (in two or more contiguous leads) and at least 1 mm in depth. However, Q waves may be normal and are ignored in lead III (unless they are also in leads II and aVF), in lead V1 (unless also in lead V2), and in lead aVL (unless Q-wave height ≥ 50% R-wave height). The QS complexes in leads V1-V2 may also be a normal variant.

Although a Q wave in leads V1-V2 can be a normal variant, in this case there are large Q waves in leads V1-V3; therefore, this is indicative of an old anteroseptal MI. This patient has poor functional capacity and likely significant coronary artery disease. However, the presence of ischemia may not be reliably established given his poor functional status. He should undergo further risk stratification before his elective high-risk vascular surgery. This generally involves some form of exercise testing. It is unlikely that he can perform any substantial exercise on a treadmill given his poor functional status. In this situation a dobutamine stress echocardiogram or a pharmacologic stress test would be preferred. The presence of substantial areas of ischemia might prompt a cardiac catheterization, which should be performed for clinical indications prior to vascular surgery. It has been shown (CARP trial) that in such patients the outcome from medical therapy (especially β-blockers), percutaneous coronary intervention, or bypass surgery is the same. This finding calls into question the need for preoperative risk stratification rather than just beginning an intensive anti-ischemic medical program. ■

Notes

Practice Case 56

An 88-year-old woman is admitted to the intensive care unit with hematemesis and dizziness. On endoscopy, she is found to have a bleeding gastric ulcer that is clipped. Her hematocrit is 19 and she is transfused with 4 units of red blood cells.

What does her ECG show?

What is the likely diagnosis?

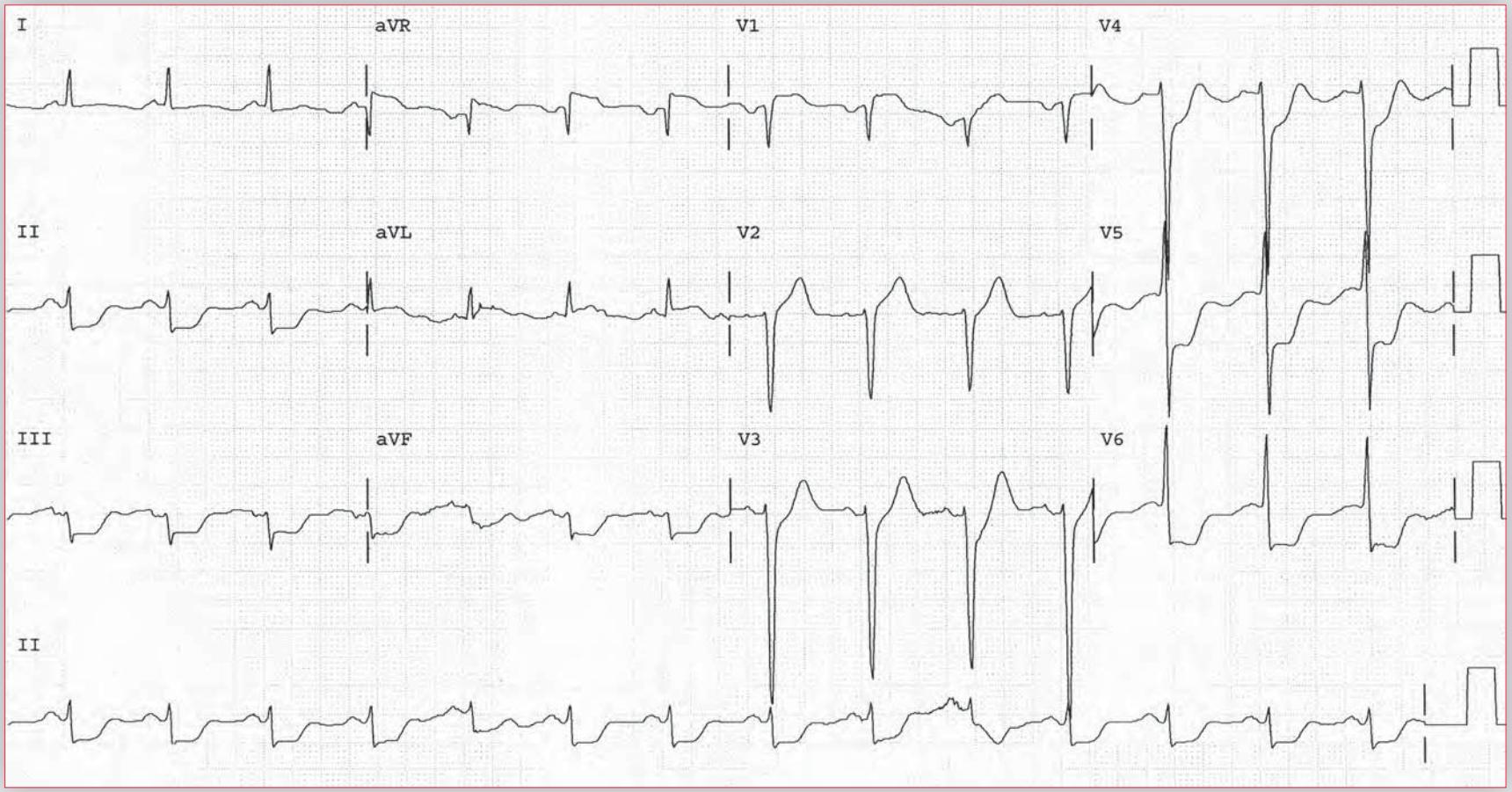

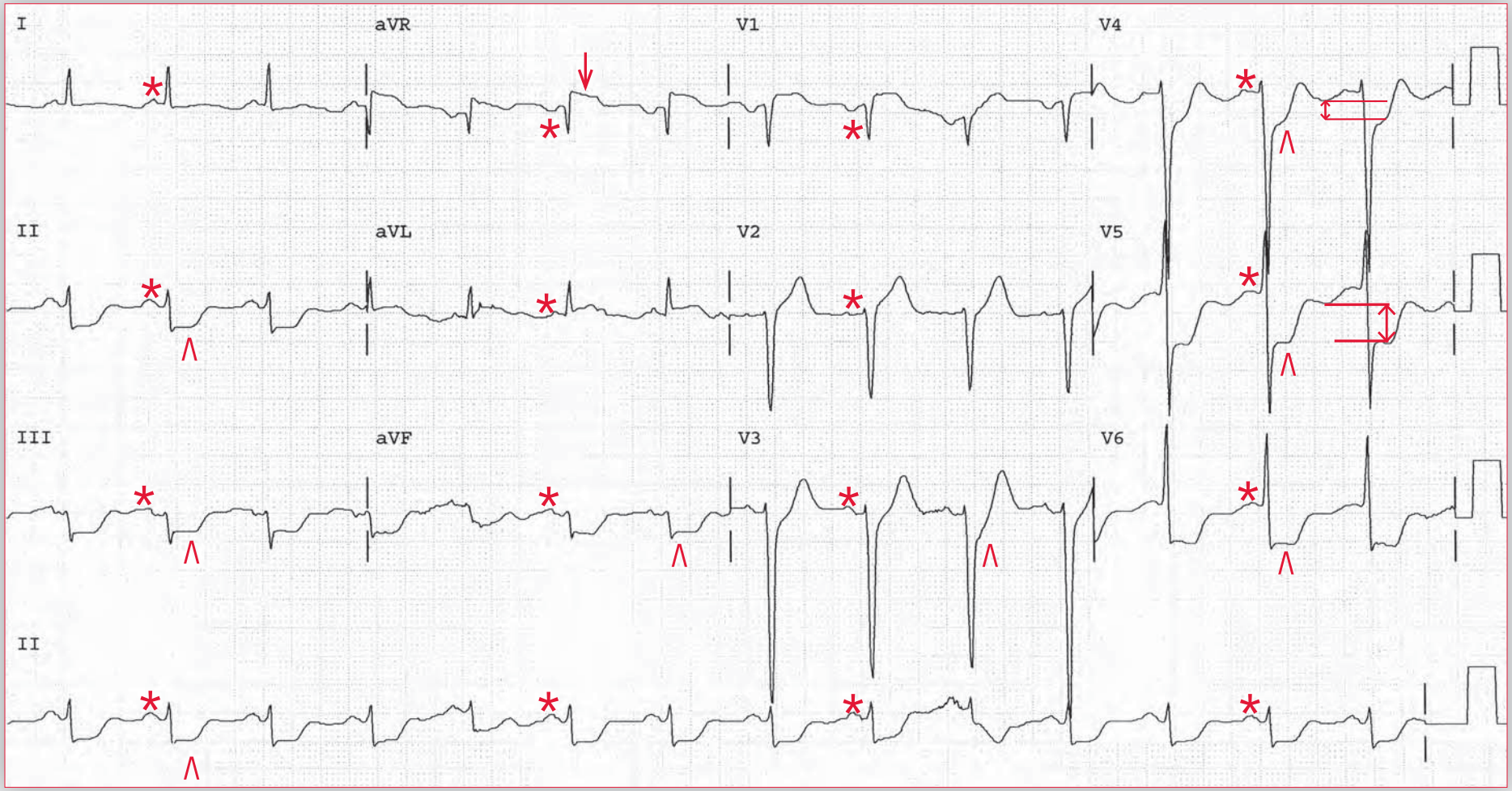

ECG 56 Analysis: Normal sinus rhythm, upsloping and horizontal ST-segment depression

There is a regular rhythm at a rate of 86 bpm. There is a P wave (*) prior to each QRS complex, and the PR interval is stable (0.16 sec). The P wave is positive in leads I, II, aVF, and V4-V6 and negative in lead aVR. This is a normal sinus rhythm.

The QRS complex duration is normal (0.08 sec), and the axis is leftward, between 0° and –30° (positive QRS complex in leads I and II and negative QRS complex in lead aVF). The QT/QTc intervals are normal (360/420 msec). There is normal R-wave progression from leads V1 to V6. J-point and ST-segment depression (^) are seen in the inferior leads (II, III, and aVF) and the anterolateral leads (V3-V6). The ST-segment depression (about 3 mm [↕]) is upsloping in leads V3-V4, while it is horizontal in leads II, III, aVF, and V5-V6 and is up to 7 mm (↕). The ST-segment elevation in lead aVR (↓) is actually ST-segment depression.

This patient has diffuse ST-segment depression, likely indicating global ischemia. Since she has not had any cardiac symptoms before or during this event, the ischemia is undoubtedly exacerbated by marked anemia (demand ischemia). It is likely that this patient has significant fixed coronary disease that has become clinically evident under the hemodynamic stress of her acute blood loss. The primary treatment for ischemia in this setting is blood transfusion and volume resuscitation followed by definitive endoscopic or surgical therapy for the bleeding ulcer. ■

Notes

Practice Case 57

A 48-year-old woman with Hodgkin's disease undergoes chest and mediastinal radiation. After her fourth radiotherapy treatment she develops chest pain and a sharp sensation while inhaling.

What does her ECG show?

What is the likely diagnosis?

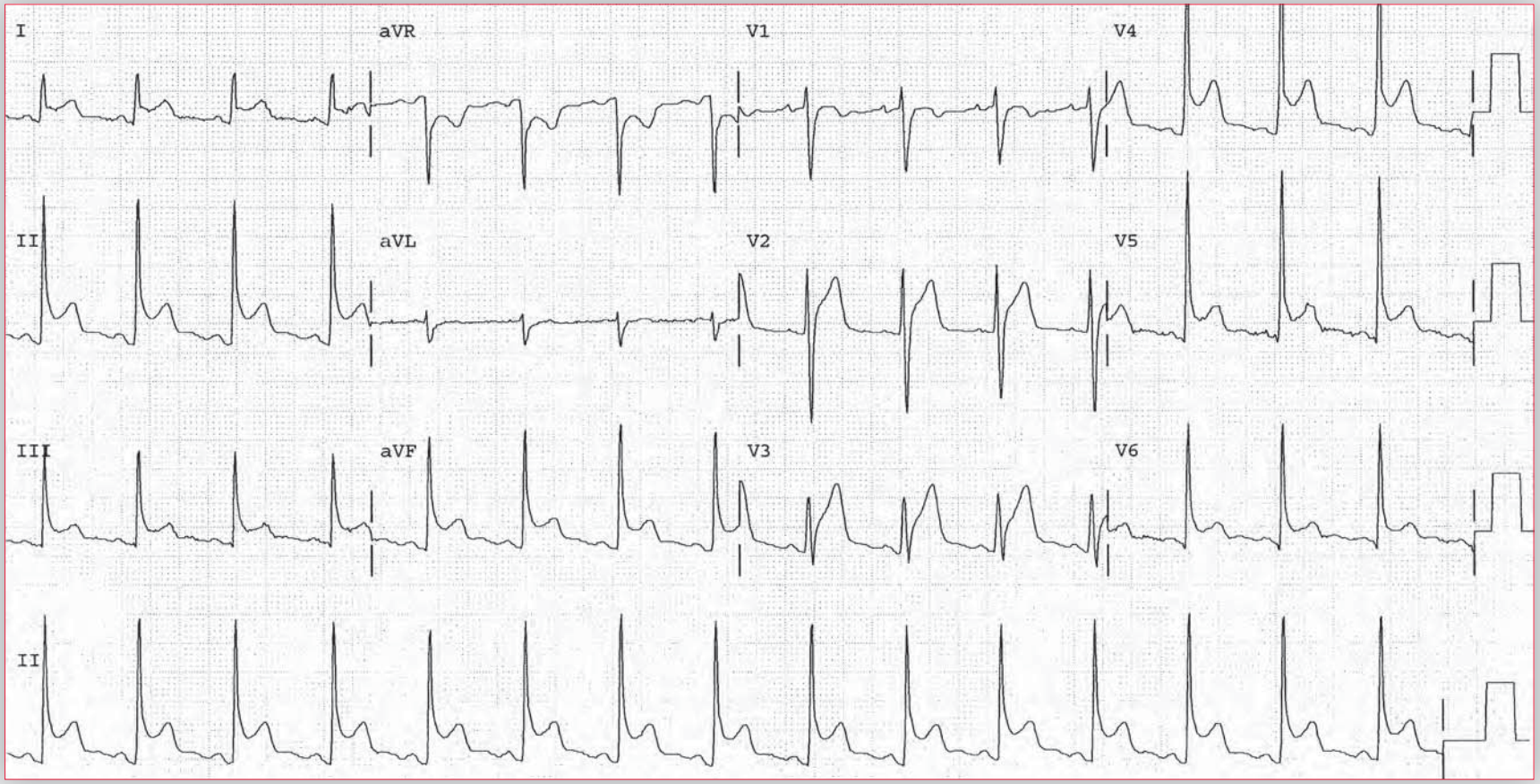

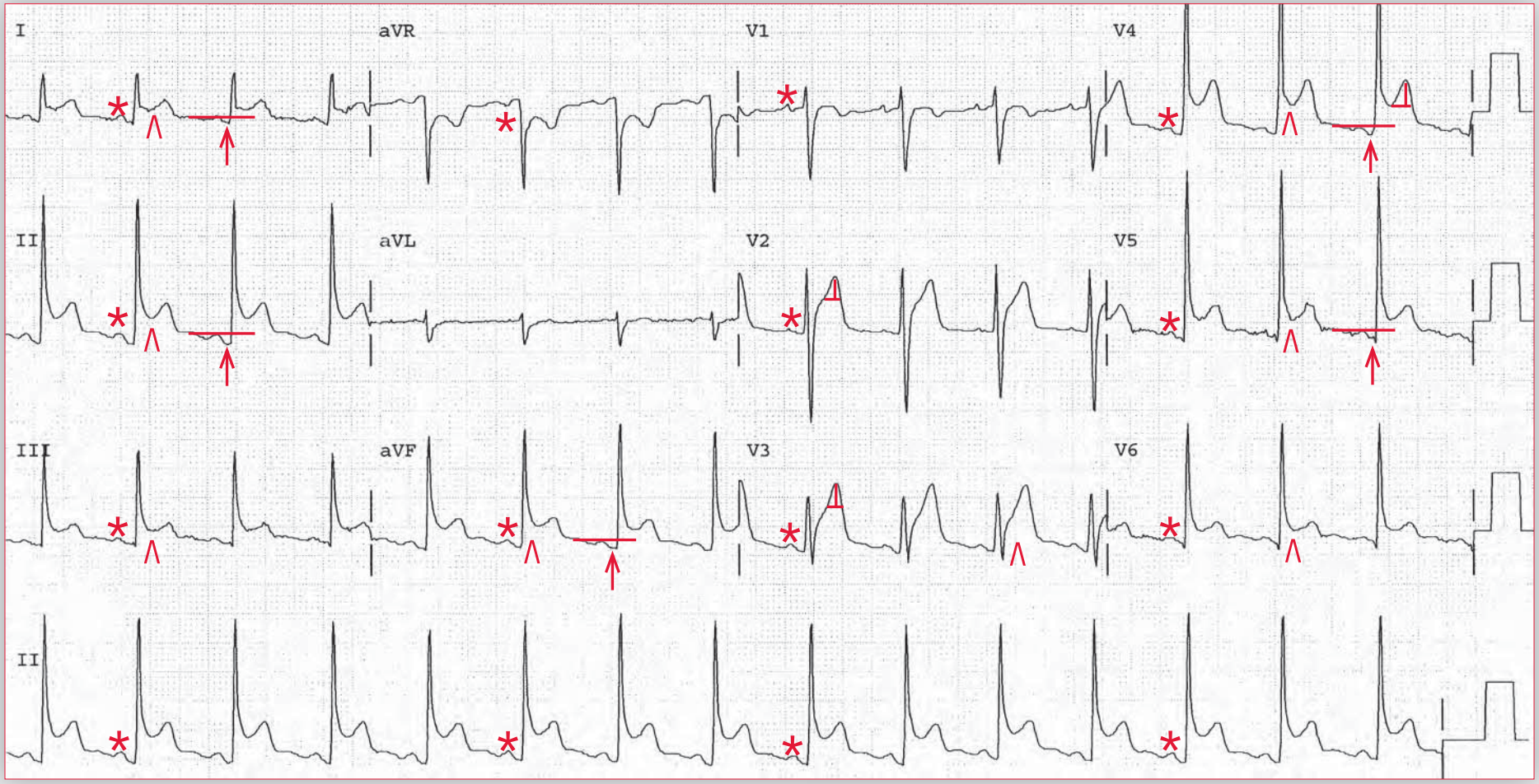

ECG 57 Analysis: Normal sinus rhythm, pericarditis

There is a regular rhythm at a rate of 90 bpm. There is a P wave (*) before each QRS complex, with a stable PR interval (0.16 sec). The P wave is positive in leads I, II, aVF, and V4-V6 and negative in lead aVR. This is a normal sinus rhythm. The P-wave morphology is normal.

The QRS complex duration is normal (0.10 sec), and there is a normal axis, between 0° and +90° (positive QRS complex in leads I and aVF). The QRS morphology is normal. The QT/QTc intervals are normal (320/390 msec).

There is widespread J-point and ST-segment elevation (^) above the baseline (TP segment), apparent in leads I, II, III, aVR (ST-segment depression in this leads is actually ST-segment elevation), aVF, and V2-V6. The ST segment has a normal concave morphology. Also noted is PR-segment depression (↑), most obvious in leads I, II, aVF, and V4-V5. In lead aVR the PR-segment elevation is actually PR depression. The baseline is the TP segment, and the PR segment can be seen below this plane. Although the T waves are prominent, especially in leads V2-V4, they are asymmetric (slow upstroke, faster downstroke) and hence normal. The ECG, therefore, shows pericarditis.

This patient probably has radiation-induced pericarditis. Pericardial involvement from Hodgkin's disease is possible but less likely. Radiation-induced pericarditis is less common now than in the past as a result of better shielding techniques. It tends to occur during ongoing radiotherapy. It may develop years after the radiation therapy and can result in chronic and/or constrictive pericarditis. On occasion the pericardium may become calcified. Other long-term complications may also occur from chest radiation. These include coronary atherosclerosis, valvular heart disease (most commonly aortic regurgitation, aortic stenosis, or mitral regurgitation), conduction system disease and, rarely, radiation-induced restrictive cardiomyopathy. ■

Notes

Practice Case 58

A 74-year-old woman who suffered a myocardial infarction (MI) 2 months ago suddenly experiences word-finding difficulties and transient right-sided weakness. She waits about 3 hours before presenting to the hospital. Shortly after arriving in the emergency department, her symptoms begin to resolve. The treating neurologist suspects she has suffered a transient ischemic attack in the left middle cerebral artery distribution. There is no evidence of ischemic stroke on brain computed tomography. An ECG is performed on admission.

What does it show?

What is the likely diagnosis?

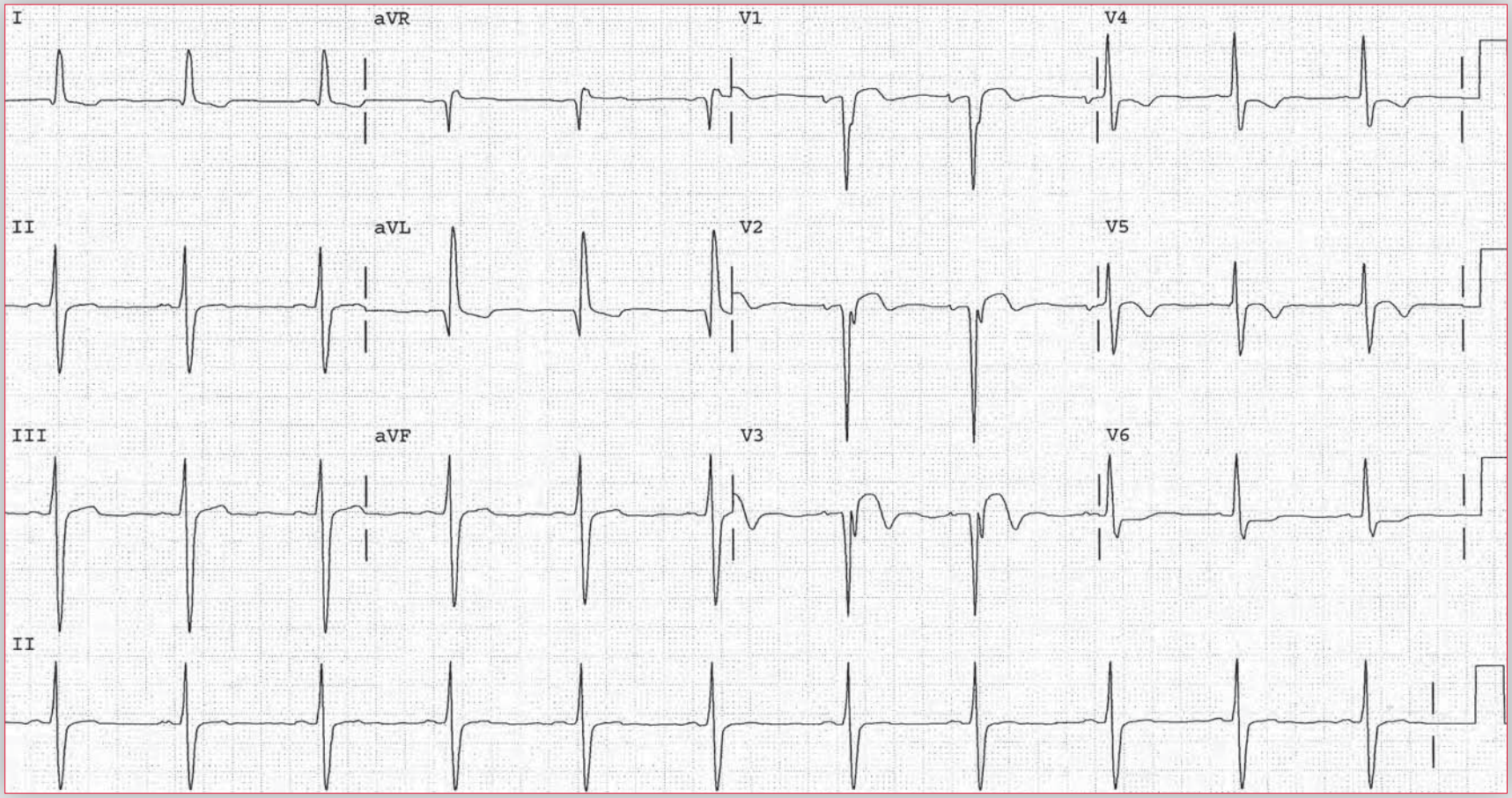

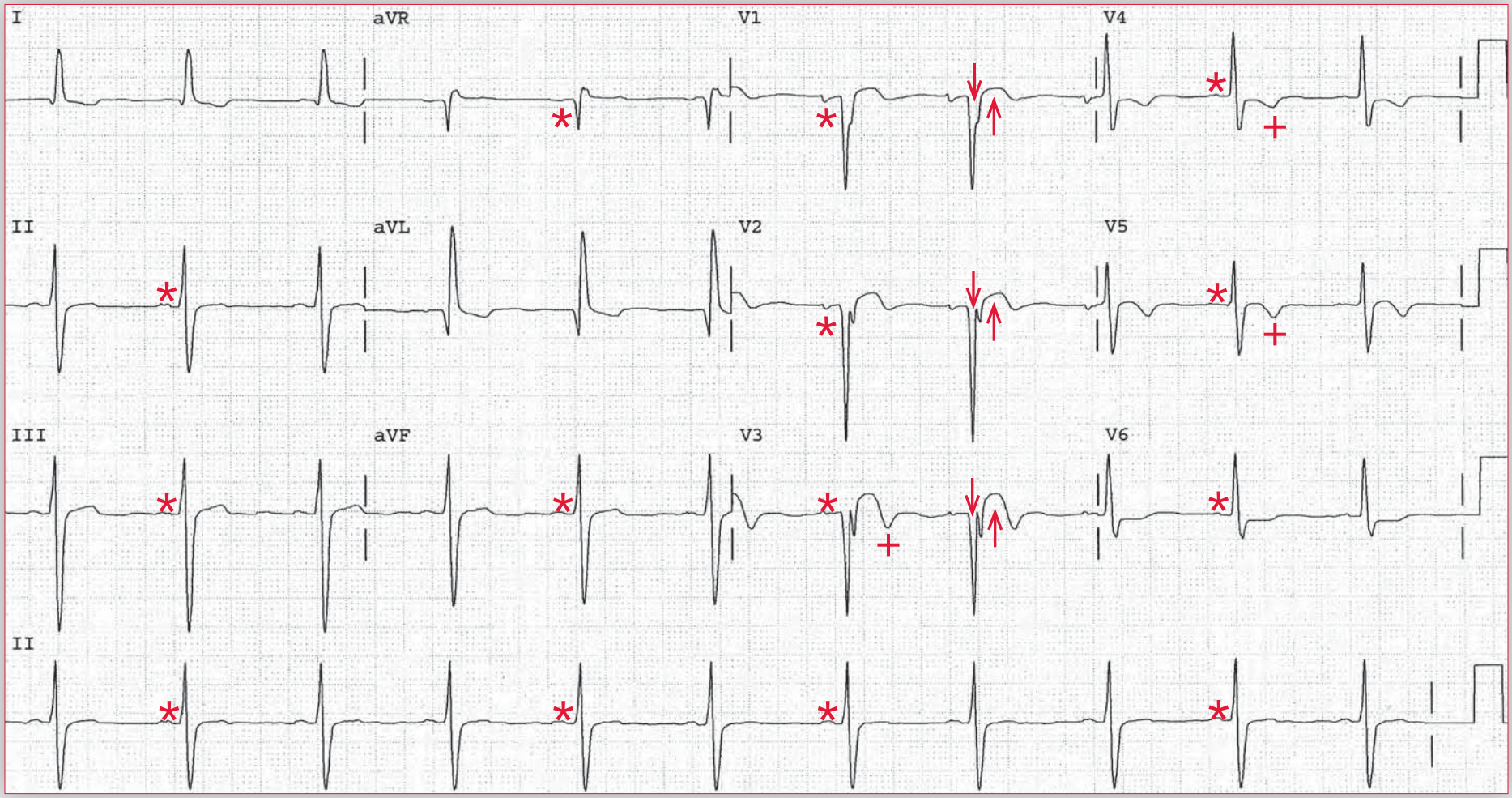

ECG 58 Analysis: Normal sinus rhythm, intraventricular conduction delay, old anterior wall myocardial infarction, ST-segment elevation (left ventricular aneurysm)

There is a regular rhythm at a rate of 66 bpm. There are P waves (*) before each QRS complex, with a stable PR interval (0.16 sec). The QRS duration is prolonged (0.12 sec) without any specific pattern; hence this is an intraventricular conduction delay. The axis is leftward, at –30° (positive QRS complex in lead I, negative QRS complex in lead aVF, isoelectric QRS complex in lead II). The QT/QTc intervals are normal (360/380 msec and 320/360 msec when corrected for the prolonged QRS complex duration).

In leads V1-V3, there is a QS complex (↓), the ST segments (↑) are elevated, and the T waves are inverted (+). In the clinical context of a prior myocardial infarction and no current chest pain, the ST-segment elevation likely represents a chronic anterior wall myocardial infarction associated with a left ventricular aneurysm. She may have a mural thrombus associated with the aneurysm that has caused a cardioembolic stroke. This diagnosis can be confirmed by echocardiography, which will show an area of myocardial thinning and akinesis. A thrombus may be visualized along the luminal surface of the ventricle. Therapy with systemic anticoagulation should be initiated to prevent further thrombus formation in the aneurysm and to reduce the risk for further cardioembolic phenomena. ■

Notes

Practice Case 59

A 62-year-old man with diabetes presents for a visit with his new primary care physician. Given his longstanding diabetes, the man is concerned about his risk for cardiovascular disease. He reports no recent illness and has good functional capacity. He does not recall any episodes of prolonged chest discomfort or dyspnea.

What does his ECG show?

What is the likely diagnosis?

What further testing is warranted?

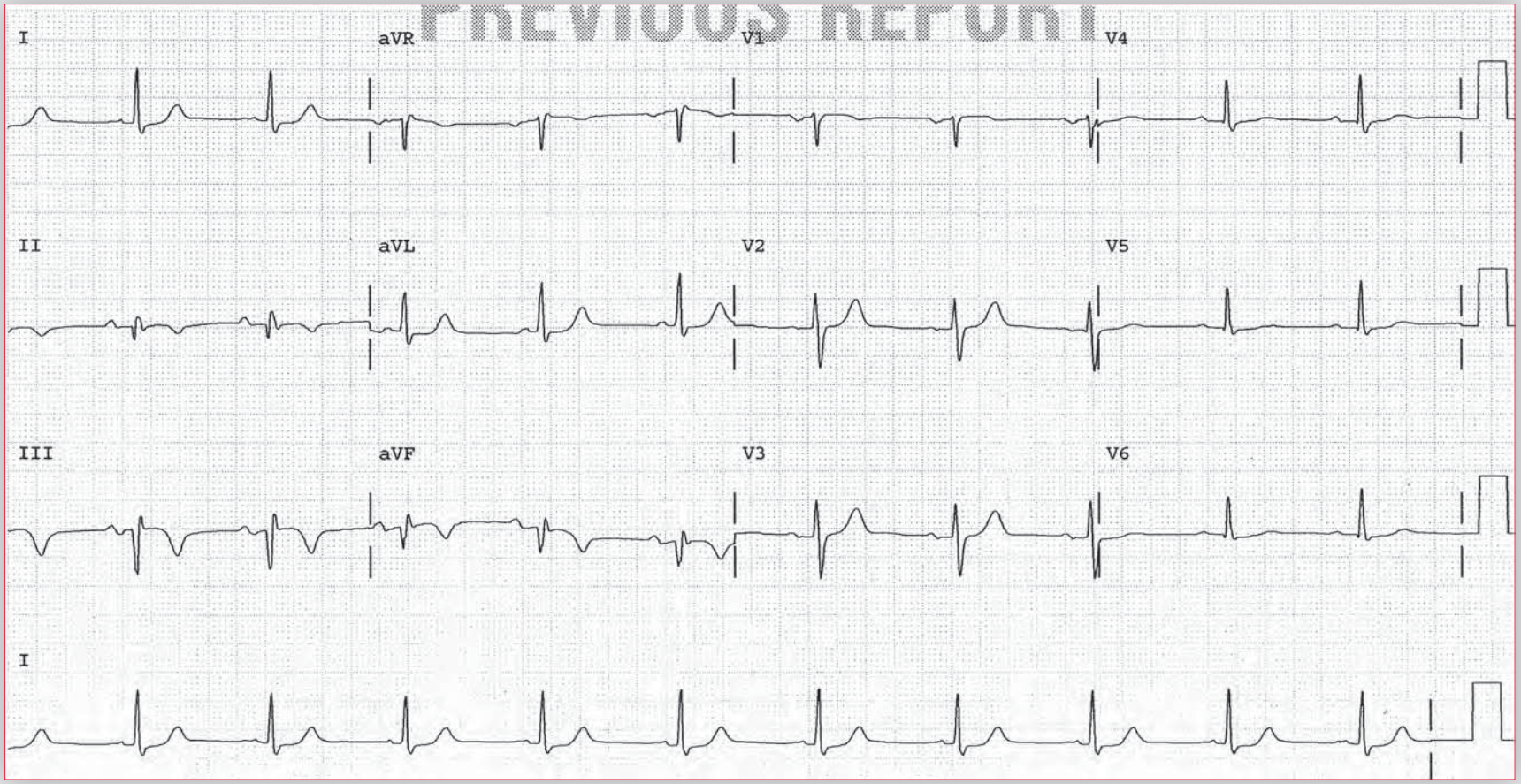

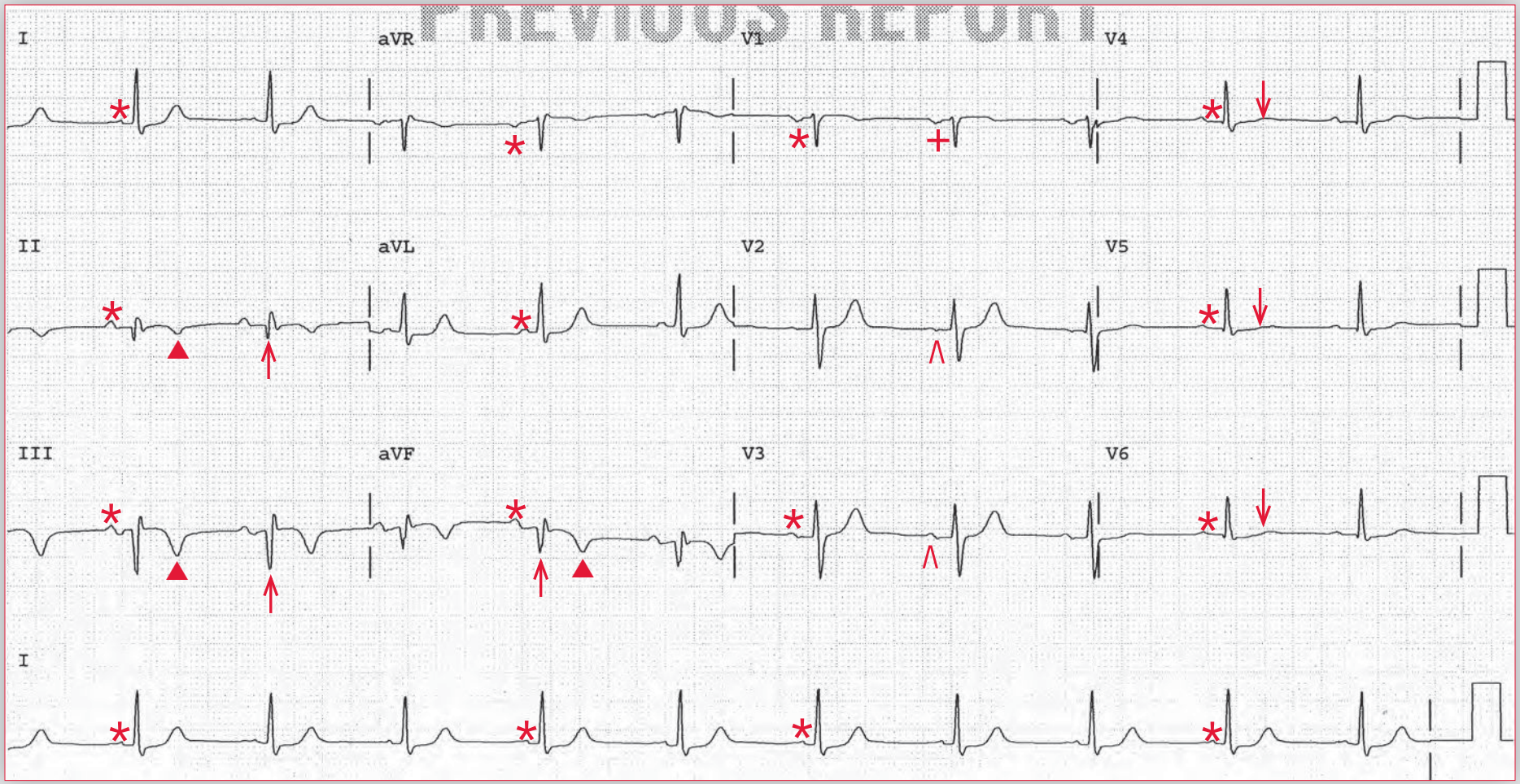

ECG 59 Analysis: Normal sinus rhythm, left atrial hypertrophy, old inferior wall myocardial infarction (MI), nonspecific T-wave abnormalities

There is a regular rhythm at a rate of 64 bpm. There is a P wave (*) before each QRS complex, and the PR interval is stable (0.20 sec). There is a P wave prior to each QRS complex, and the P wave is positive in leads I, II, aVF, and V4-V6 and negative in lead aVR. This is a normal sinus rhythm. The P wave is negative (+) in lead V1 and biphasic in leads V2-V3 (^), suggesting left atrial hypertrophy.

The QRS complex duration is normal (0.10 sec). There are significant Q waves (↑) in leads II, III, and aVF as well as T-wave inversions (▲), diagnostic for an old inferior wall myocardial infarction (MI). As a result of the inferior Q waves, the axis appears to be leftward (positive QRS complex in lead I and negative QRS complex in lead aVF); however, this is the result of the inferior wall MI. There are also nonspecific T-wave changes (flattening) (↓) in leads V4-V6. The QT/QTc intervals are normal (360/370 msec).

Silent MIs are common and are seen in up to one-third of those who have an MI pattern on the ECG. They are especially common in diabetic patients, who often have discomfortless ischemia and infarctions. Since he suffered an MI without developing chest discomfort, this man is at risk for further episodes of "silent" or discomfortless myocardial ischemia. He should undergo further risk stratification with an exercise test with imaging (either echocardiography or nuclear imaging) to assess for further territory at risk. Should he have evidence of significant myocardial ischemia, he may elect to undergo coronary revascularization. ■

Notes

Practice Case 60

A medical student is learning to perform electrocardiography and obtains an ECG on her 23-year-old classmate.

What does the ECG show?
What is the likely diagnosis?
What further treatment is warranted?

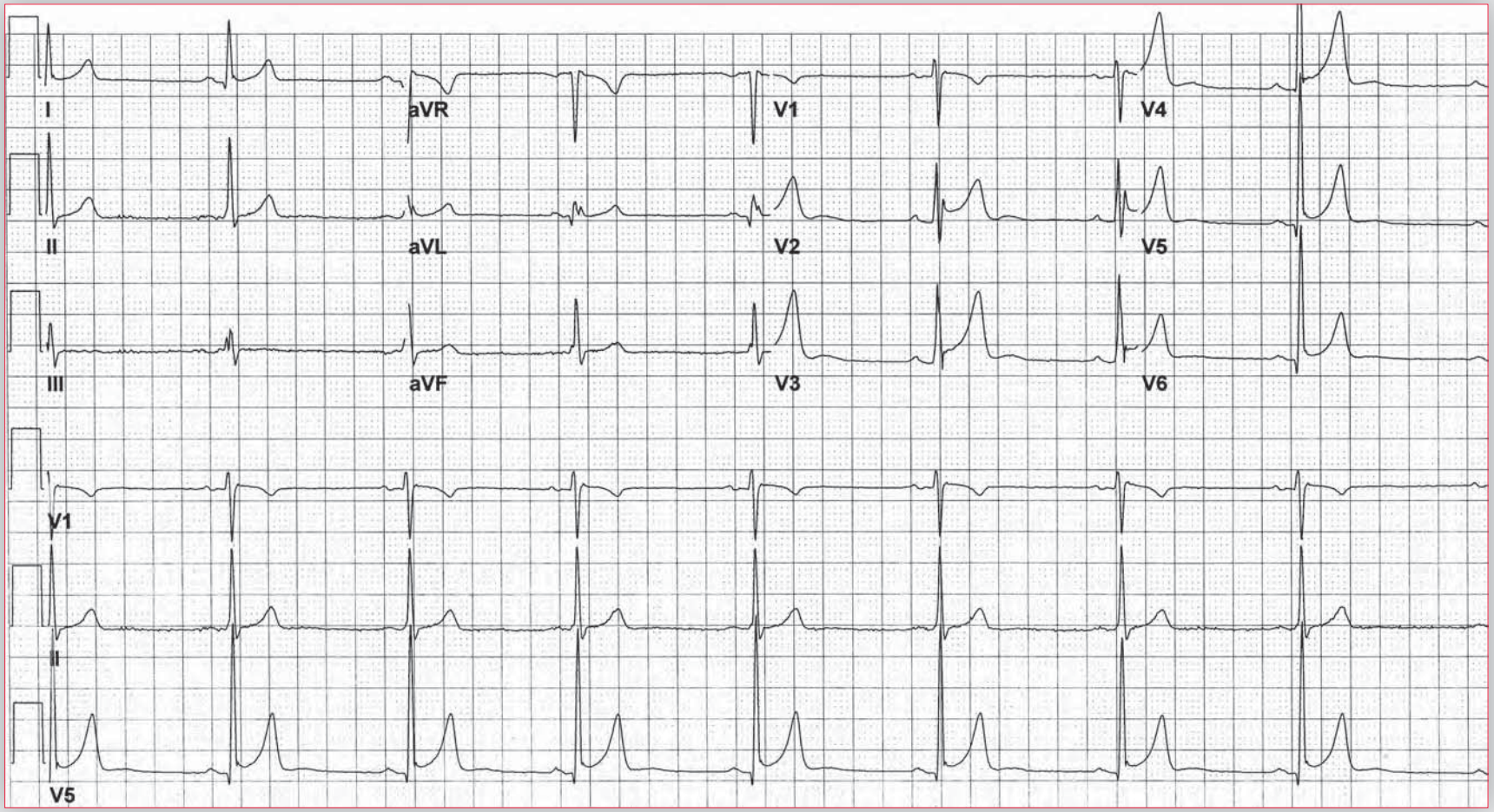

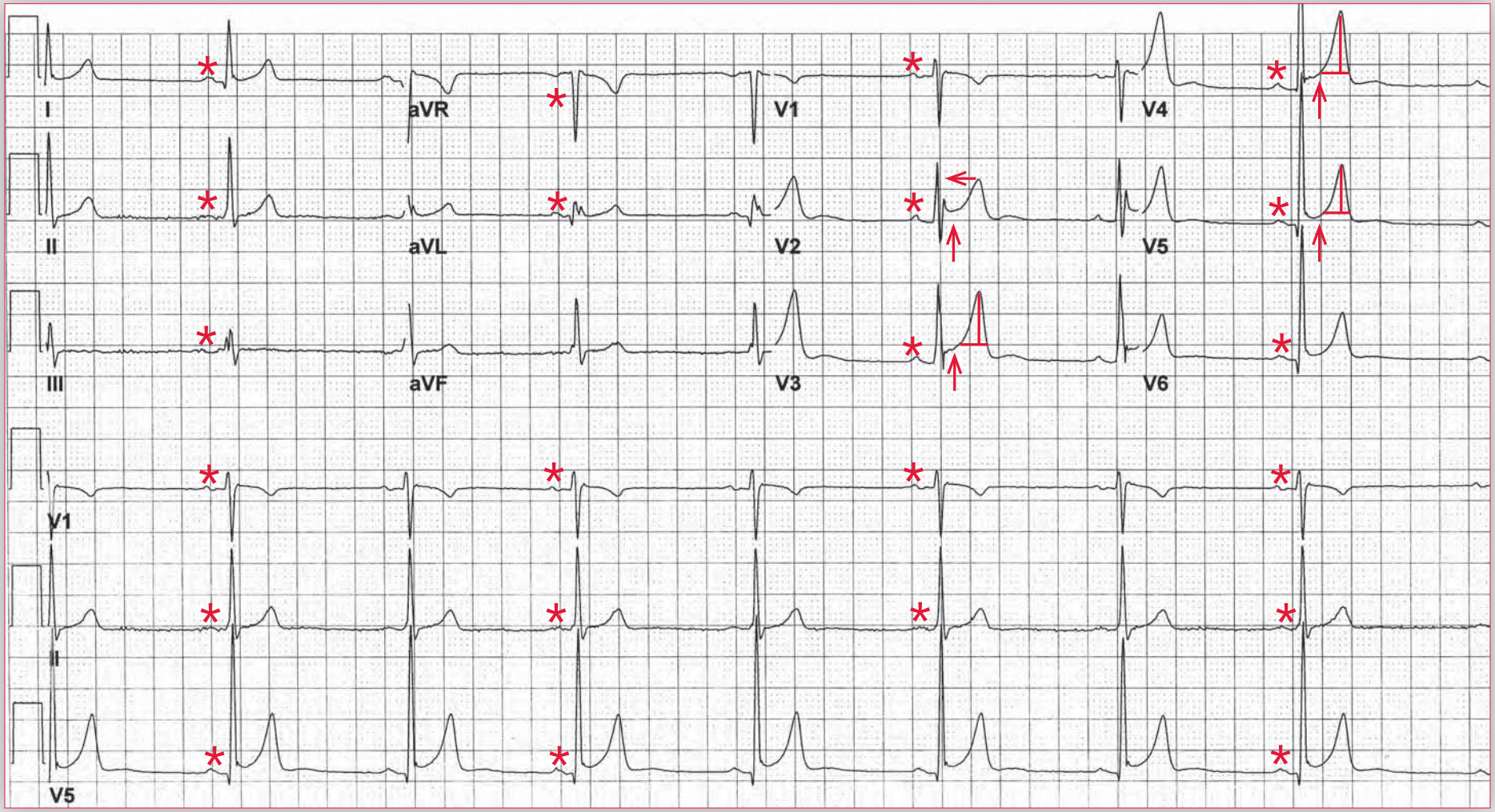

ECG 60 Analysis: Sinus bradycardia, counterclockwise rotation (early transition), early repolarization

The rhythm is regular at a rate of 50 bpm. There is a P wave (*) before each QRS complex, with a stable PR interval (0.18 sec). The P waves are positive in leads I, II, aVF, and V4-V6, and they have a normal morphology. This is sinus bradycardia.

The QRS complex duration is normal (0.08 sec), and there is a normal morphology. The axis is normal, between 0° and +90° (positive QRS complex in leads I and aVF). The QT/QTc intervals are normal (400/370 msec). Although the R wave in leads V4-V5 is prominent, the amplitude does not meet any of the criteria for left ventricular hypertrophy. There is a tall R wave in lead V2 (←), a result of early transition or counterclockwise rotation of the electrical axis in the horizontal plane. This is determined by imagining the heart as viewed from under the diaphragm. When there is counterclockwise rotation, electrical forces from the left ventricle occur early in the precordial leads, accounting for the tall R wave in lead V2. Although the T waves are prominent in leads V3-V4, they are asymmetric and have a normal morphology.

J-point and ST-segment elevation (↑) are noted in leads V2-V5. This is termed early repolarization, which is a normal finding often seen in association with left ventricular hypertrophy; it is also seen in young patients with or without prominent R-wave amplitude.

Sinus bradycardia is a normal finding in young, physically fit individuals. Although the appearance of early repolarization can be alarming (suggesting an early myocardial infarction), it is a normal variant and is present in about 5% of the population. The pattern most often occurs in the precordial leads (as is seen in this case) but can affect any lead. The normal T waves also exclude an acute myocardial infarction. No further diagnostic studies or therapy is warranted. ■

Notes

Practice Case 61

A 64-year-old man with a previous myocardial infarction (MI) but no current symptoms is in the operating room undergoing an abdominal aortic aneurysm repair. The lengthy surgery appears to progress without incident; however, after returning to the recovery room he becomes progressively hypoxic despite increasing fraction of inspired oxygen (FiO_2) and has short runs of a wide-complex tachycardia determined to be ventricular tachycardia. A 12-lead ECG is obtained.

What does his ECG show?

What is the likely diagnosis?

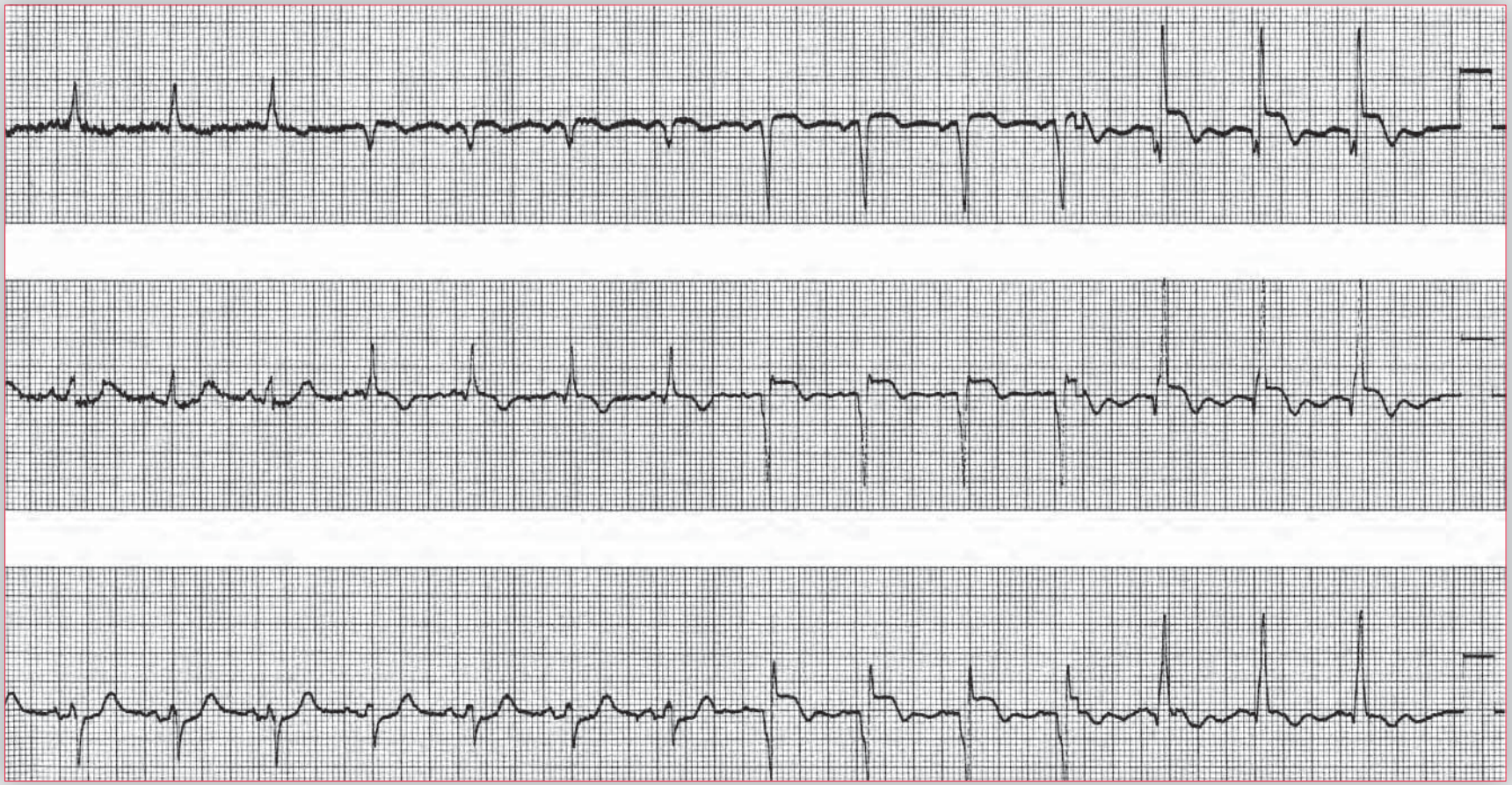

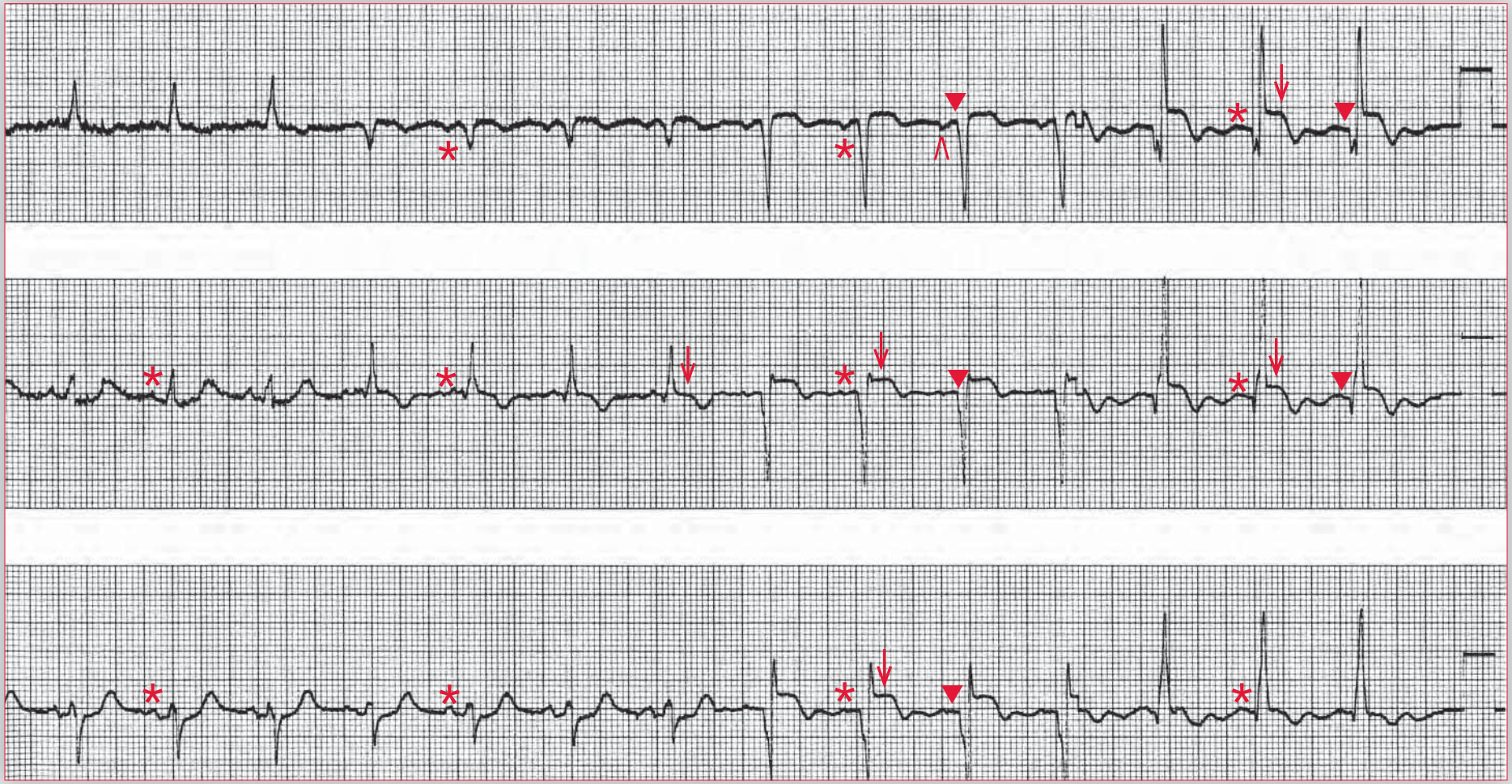

ECG 61 Analysis: Normal sinus rhythm, left atrial hypertrophy, old anterior wall MI, persistent ST-segment elevation (left ventricular aneurysm)

Although the leads are not labeled, the pattern is always the same (column 1 is leads I, II, and III; column 2 is leads aVR, aVL, and aVF; column 3 is leads V1-V3; and column 4 is leads V4-V6). There is a regular rhythm at a rate of 88 bpm. There is a P wave (*) before each QRS complex, with a stable PR interval (0.16 sec). The P wave is positive in leads I, II, aVF, and V4-V6 and negative in lead aVR. This is a normal sinus rhythm. The P wave is negative in lead V1 (^), suggesting left atrial hypertrophy (abnormality).

The QRS complex duration is normal (0.10 sec), and there is a physiologic left axis deviation, between 0° and –30° (positive QRS complex in leads I and II and negative QRS complex in lead aVF). The QT/QTc intervals are normal (360/440 msec and 340/410 msec when corrected for the prolonged QRS complex duration). There are Q waves (▼) in leads V1-V5 (the complex has a QS morphology in leads V1-V2), diagnostic for an extensive anterior wall myocardial infarction (MI). In addition, ST-segment elevation (↓) can be seen above the baseline (TP segment) in leads V2-V5; slight elevation is noted in lead aVL. ST-segment elevations are seen in the setting of an acute MI, and they return to baseline during the normal evolution of the ECG after the infarction. ST-segment elevation that persists for weeks to years after an MI indicates the presence of an aneurysm.

Although this patient was initially thought to have suffered a large anterior MI during his surgery, a pre-surgery ECG was identical to this one. Hence there has been a previous MI (as per his history) and the ST-segment changes are indicative of an anterior wall aneurysm. The episodes of tachycardia, likely ventricular tachycardia, as well as the increasing hypoxemia could perhaps be the result of heart failure due to increased vascular volume from excessive fluid infusion and possibly the effect of hypoxia. It is most likely that the ventricular tachycardia originates in the area of the aneurysm that is associated with scar. ■

Notes

Practice Case 62

A 61-year-old man with factor V Leiden presents for evaluation of a swollen and painful right calf, dyspnea, and pleuritic chest pain that began shortly after returning home from a long transatlantic flight. He has had two prior deep vein thromboses (DVTs) and had been maintained on warfarin for several years. However, warfarin was discontinued 1 year ago. His examination is notable for a loud P2, subtle right precordial heave, and a warm, edematous right calf.

What does his ECG show?

What is the likely diagnosis?

What further evaluation or therapy is indicated?

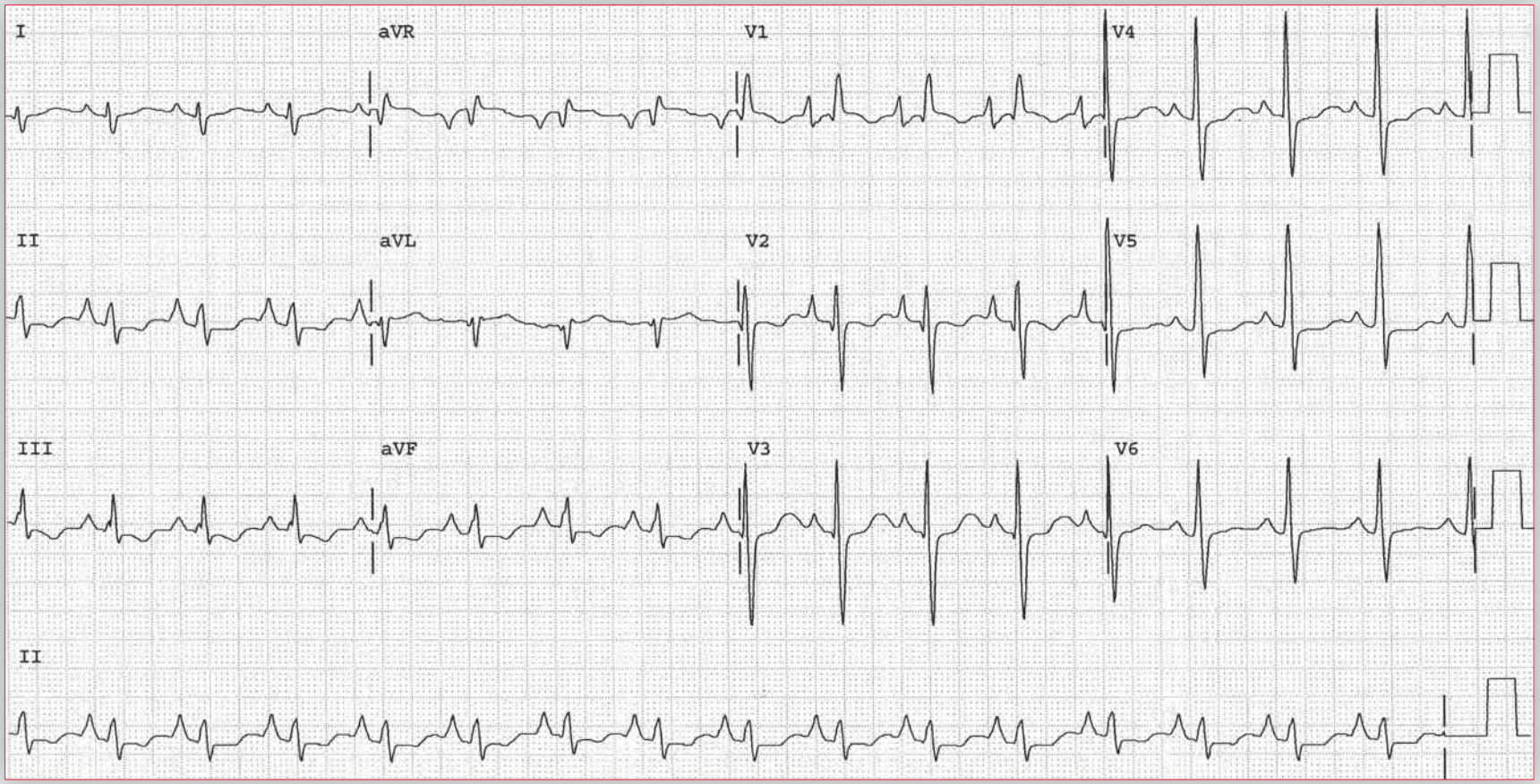

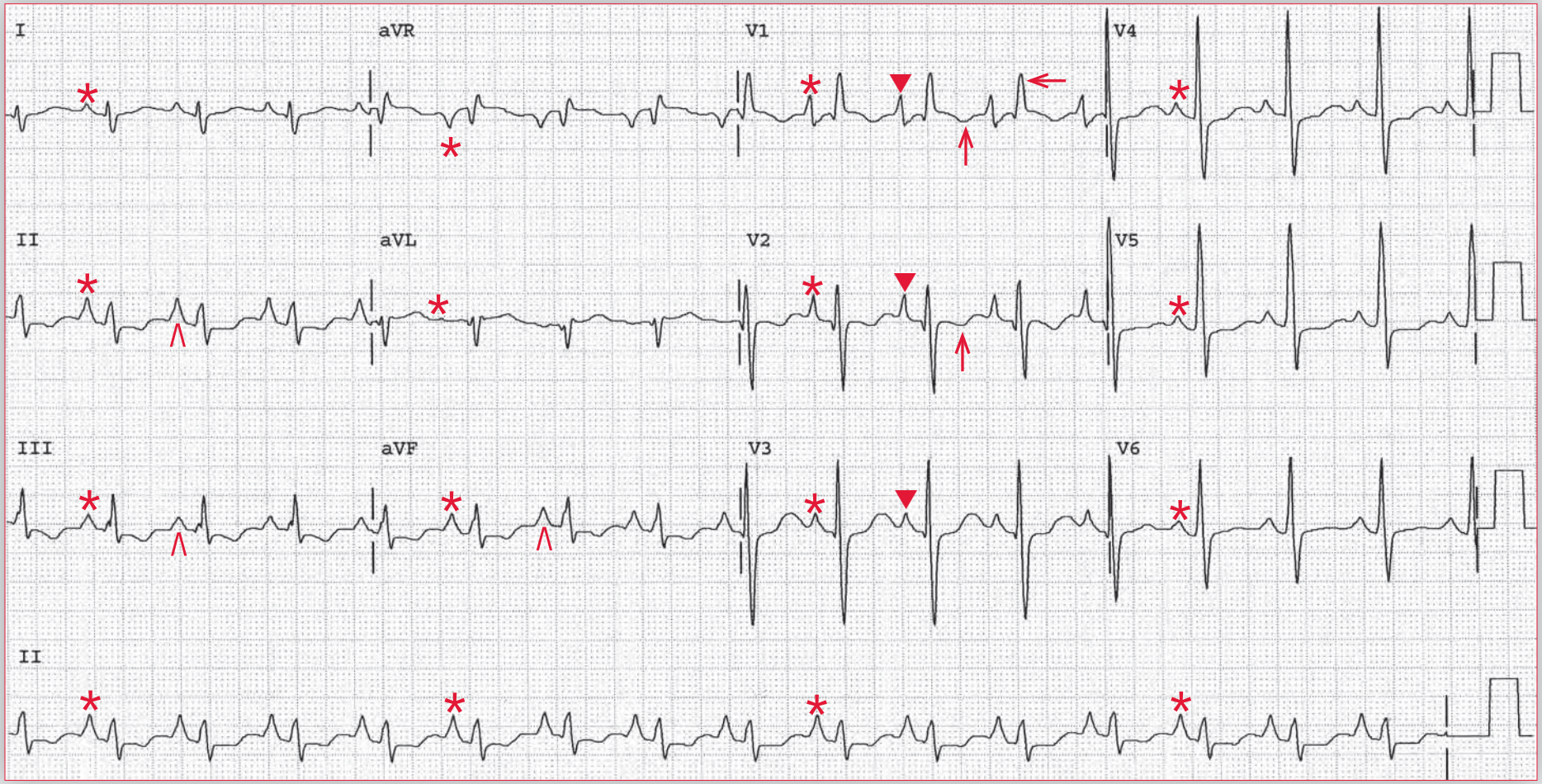

ECG 62 Analysis: Normal sinus rhythm, right atrial hypertrophy (abnormality), right ventricular hypertrophy (RVH), right axis deviation, prolonged QT interval

There is a regular rhythm at a rate of 94 bpm. There is a P wave (*) before each QRS complex, with a stable PR interval (0.20 sec). The P wave is positive in leads I, II, aVF, and V4-V6 and negative in lead aVR. This is a normal sinus rhythm.

The P waves are very tall (0.4 mV), peaked, and narrow (0.10 sec), especially in leads II, aVF (^), and V1-V3, where the P wave is primarily positive and narrow (▼). The P-wave morphology is characteristic of right atrial hypertrophy or P pulmonale. The etiology for right atrial hypertrophy (abnormality) is often right ventricular hypertrophy (RVH) resulting from right-sided valvular disease or pulmonary artery hypertension (primary or secondary from lung disease), left ventricular disease (systolic or diastolic), or left-sided valvular abnormalities.

The QRS complex duration is normal (0.10 sec), and the axis is rightward, between +90° and +180° (negative QRS complex in lead I and positive QRS complex in lead aVF). There are a number of causes for a right axis deviation that should be considered. These include RVH (associated with a tall R wave in lead V1 and right atrial hypertrophy or abnormality), a lateral wall myocardial infarction (a deep Q wave in leads I and aVL), right–left arm lead switch (associated with a negative P wave and T wave in leads I and aVL), dextrocardia (which resembles right–left arm lead switch and also has reverse R-wave progression across the precordium), Wolff-Parkinson-White pattern (with a prolonged QRS complex duration due to a delta wave and a short PR interval), and a left posterior fascicular block (a diagnosis of exclusion when there are no other causes for the right axis deviation). The QT/QTc intervals are prolonged (400/500 msec).

Noted is a tall R wave in lead V1 (←). This is characteristic of RVH, particularly when associated with a right axis deviation. Other causes for a tall R wave in lead V1 include a posterior wall myocardial infarction, lead misplacement, recording of right-sided leads, dextrocardia, Wolff-Parkinson-White pattern, hypertrophic cardiomyopathy, or Duchenne muscular dystrophy. However, no other ECG findings support any of these diagnoses. Associated with RVH are ST-T wave changes seen primarily in leads V1-V2 (↑), which possibly reflect subendocardial ischemia of the thick right ventricular myocardium.

The physical exam and ECG are consistent with deep vein thrombosis (DVT), the result of a long airplane trip, and likely a pulmonary embolism. The RVH suggests that the right ventricular pressure overload is chronic, perhaps due to prior pulmonary emboli. The diagnosis of DVT can be made by venous Doppler study of the lower extremity. Either a ventilation/perfusion (V/Q) scan or computed tomography pulmonary angiogram should be done to assess for pulmonary emboli. The patient should also be evaluated for pulmonary hypertension, initially with an echocardiogram. This patient should be treated with long-term anticoagulation. As he has had recurrent episodes of DVT and has a condition predisposing to thrombus formation, anticoagulation should be continued indefinitely. ■

Notes

Practice Case 63

A 72-year-old woman is admitted to the emergency department with unheralded syncope. She reports that she was walking in the grocery store when she collapsed and struck her head. She does not recall the event, but bystanders report that she was unconscious for about 90 seconds. When emergency medical services arrived, she was awake but groggy. An ECG is obtained.

What does her ECG show?

How does this finding affect the further workup she will require for her syncope?

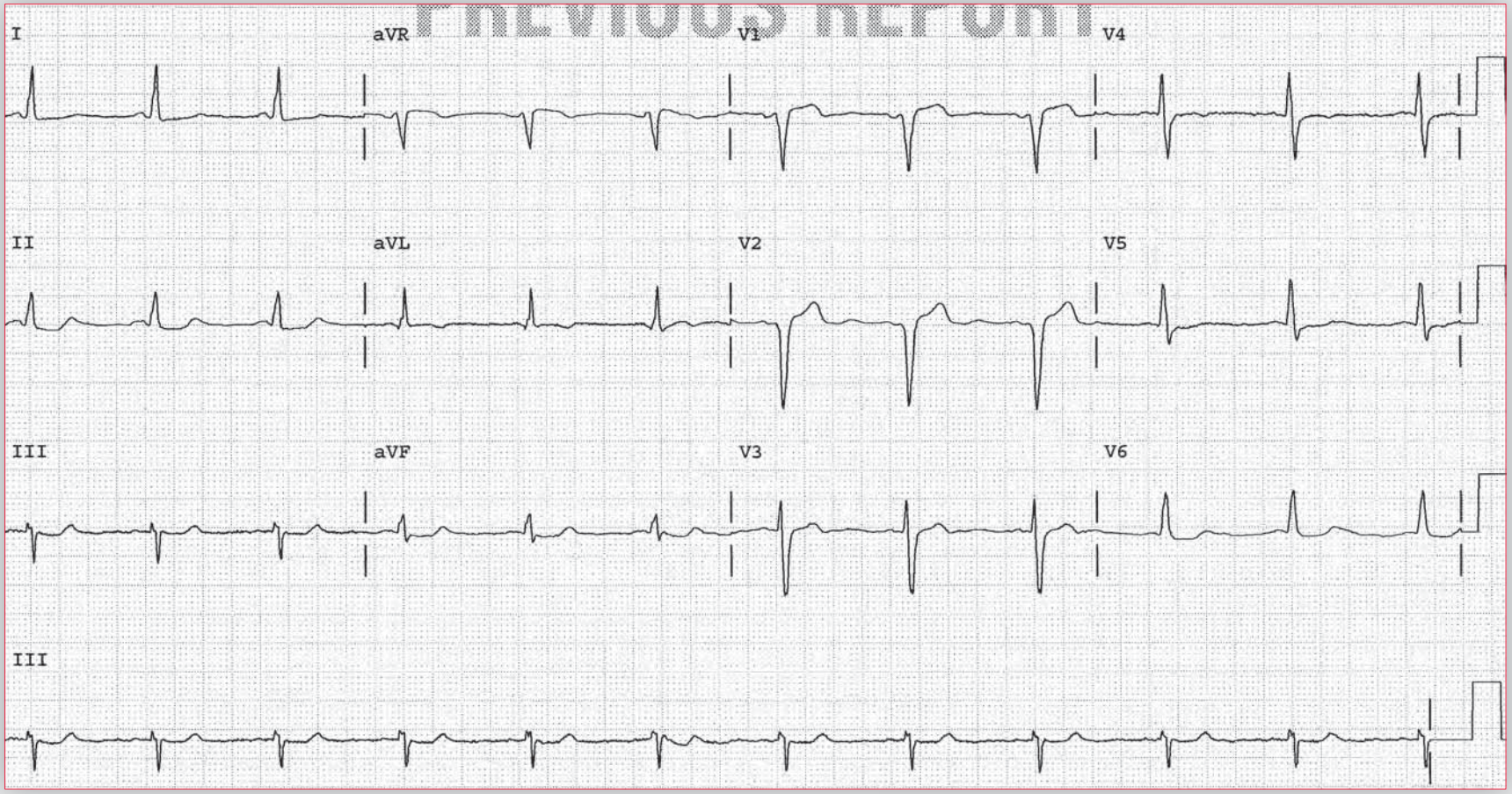

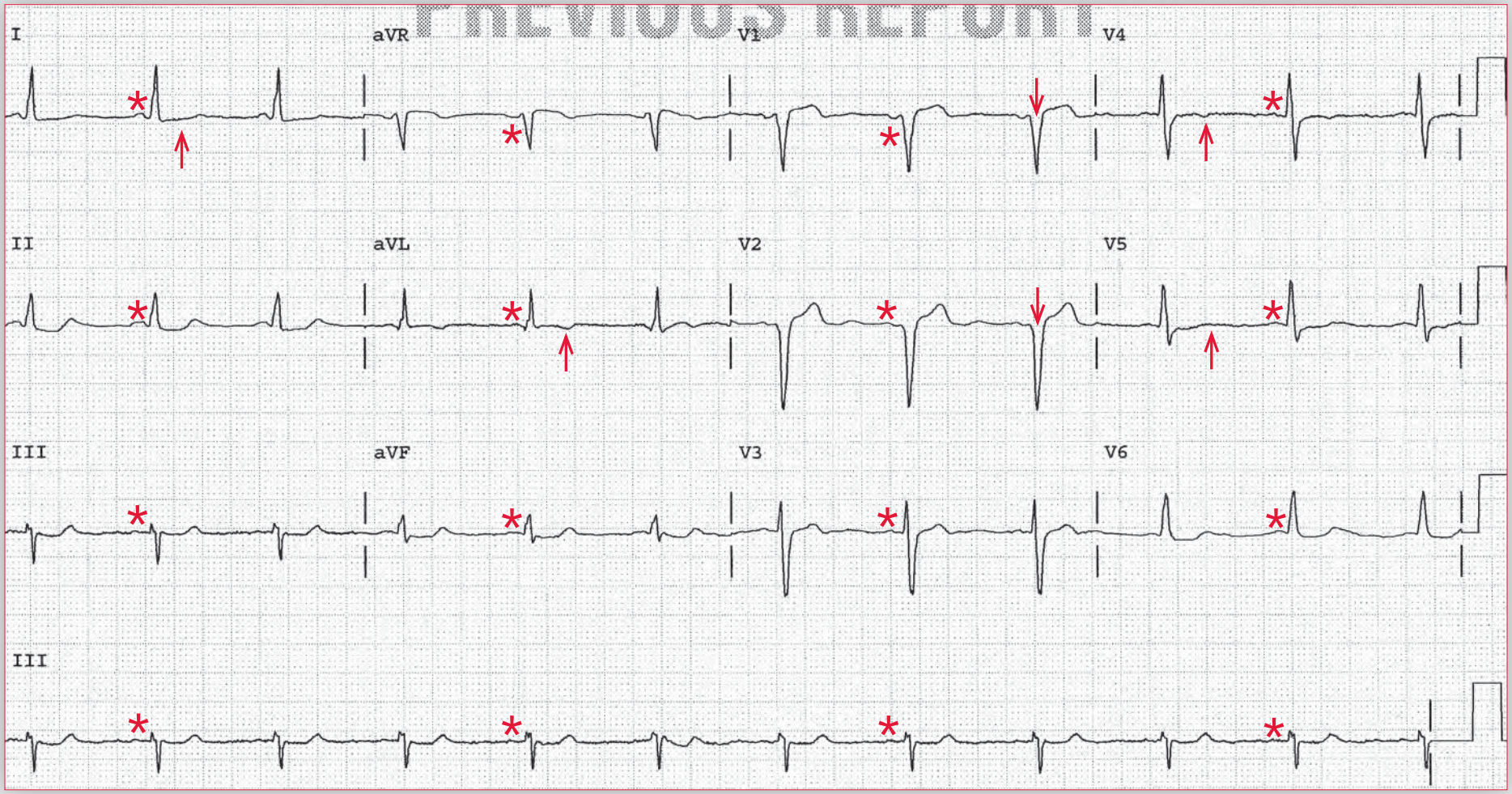

ECG 63 Analysis: Normal sinus rhythm, old anteroseptal myocardial infarction (MI), nonspecific ST-T wave changes

There is a regular rhythm at a rate of 68 bpm. There is a P wave (*) before each QRS complex, and the PR interval is stable (0.14 sec). The P wave is positive in leads I, II, aVF, and V4-V6 and negative in lead aVR. This is a normal sinus rhythm.

The QRS complex duration is normal (0.08 sec). The axis is normal, between 0° and +90° (positive QRS complex in leads I and aVF). There are Q waves or QS complexes in leads V1-V2 (↓), which are diagnostic for an old anteroseptal myocardial infarction (MI). In addition, nonspecific ST-T wave changes (↑) can be seen in leads I, aVL, and V4-V5.

This patient had unheralded syncope and suffered a head injury during the event. The clinical history strongly suggests that she may have had a cardiac etiology for the syncope. This would include a malignant ventricular arrhythmia or a profound bradycardia, particularly transient complete heart block. The finding of an old anteroseptal MI on ECG increases the possibility that she may have had either a ventricular tachycardia arising from the site of her myocardial scar or complete heart block with a slow ventricular escape rhythm as a result of significant septal damage that involves the His-Purkinje system. In this situation the syncopal episodes are termed Stokes-Adams attacks.

MI with scarring is the most common substrate abnormality associated with ventricular tachycardia in this age group and is also a common etiology for complete heart block. She should be monitored for evidence of a tachyarrhythmia or bradyarrhythmia. If complete heart block is noted, the treatment is a pacemaker. The occurrence of a spontaneous ventricular arrhythmia would be an indication for an implantable cardioverter–defibrillator to reduce her risk for a recurrent syncopal episode as well as the potential for sudden death. If no abnormality is noted spontaneously with monitoring, an electrophysiologic study may be in order to evaluate the conduction system and attempt to induce a ventricular tachyarrhythmia, indicating a site within the myocardium that is electrically unstable. Additionally, she should be evaluated for evidence of myocardial ischemia by an exercise test. ■

Notes

Practice Case 64

A 72-year-old woman was mugged while walking through the park. She alerted a nearby police officer, who found her distraught and clutching her chest. The woman reported marked chest discomfort and shortness of breath. The police officer took her to a nearby emergency department, where an ECG was obtained.

What does her ECG show?

What is the likely diagnosis?

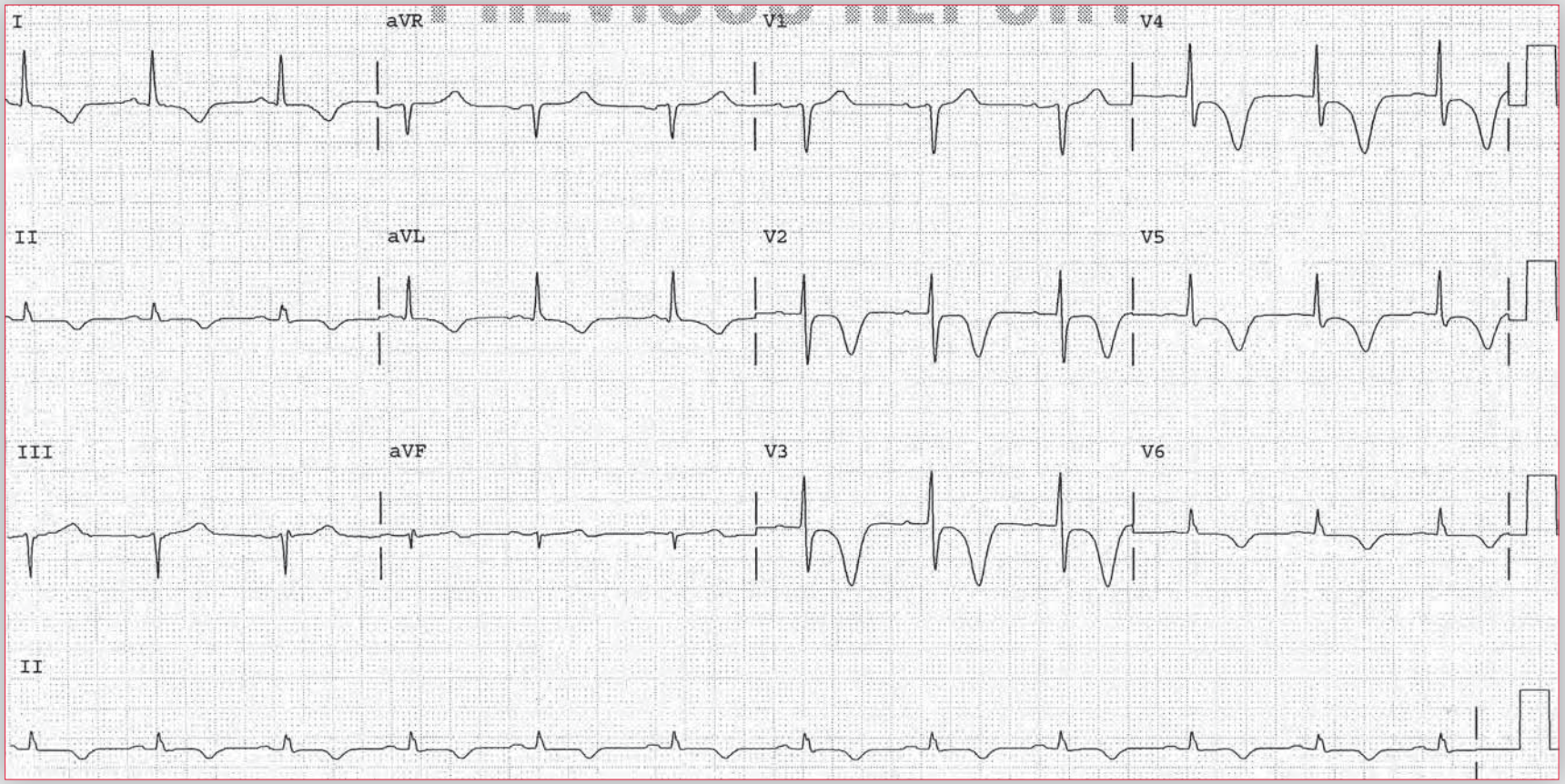

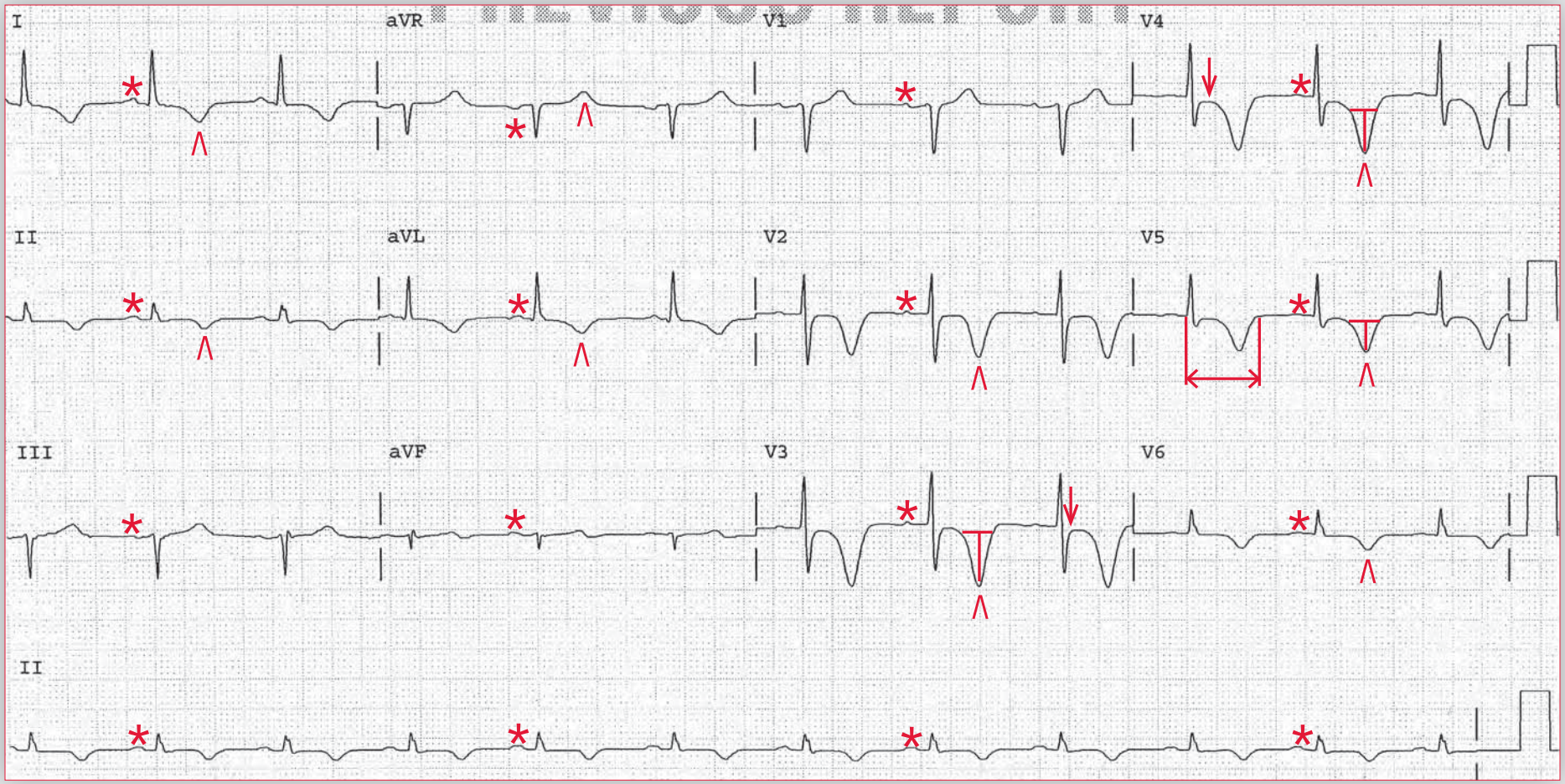

ECG 64 Analysis: Normal sinus rhythm, T-wave inversions and ST-segment depression (ischemia), prolonged QT interval

There is a regular rhythm at a rate of 70 bpm. There is a P wave (*) before each QRS complex, with a stable PR interval (0.18 sec). The P waves are positive in leads I, II, aVF, and V4-V6 and negative in lead aVR. This is a normal sinus rhythm.

The QRS complex duration is normal (0.08 sec), and the axis is physiologically leftward, between 0° and –30° (positive QRS complex in leads I and II and negative QRS complex in lead aVF). The QRS complex morphology is normal. There are inverted T waves (^) in leads I, II, aVR (normal T wave is inverted in this lead), aVL, and V2-V6. The inverted T waves are symmetric, and the QT/QTc intervals (↔) are prolonged (460/500 msec). In addition, there are ST-segment depressions (↓) in leads V3-V4. These T-wave inversions are strongly suggestive of ischemia (especially when associated with ST-segment depression and QT-interval prolongation), although this can only be established definitively with a clinical history.

This patient was taken to the catheterization laboratory given the high suspicion of acute myocardial ischemia. However, angiography revealed normal coronary arteries. Left ventriculography was then performed and showed apical and basal hypokinesis. Based on these findings, the patient was diagnosed with stress-induced cardiomyopathy (also called takotsubo cardiomyopathy). This syndrome was initially described by Japanese clinicians who noted that the shape of the left ventricular cavity resembled an octopus trap (called a takotsubo) in some patients experiencing significant emotional or physical stress. Stress cardiomyopathy is believed to be mediated by high levels of circulating catecholamines. Typically, the cardiomyopathy resolves over days to weeks and has no long-term consequences. The syndrome can mimic a myocardial infarction in almost every way. However, coronary artery disease is absent. ■

Notes

Practice Case 65

A 72-year-old man is awakened from sleep with severe retrosternal chest pressure and dyspnea. He calls emergency medical services. The responding medical technician finds him diaphoretic and in mild respiratory distress. An ECG is obtained in the field and transmitted to you in the emergency department.

What does his ECG show?

What is the likely diagnosis?

What is the next step?

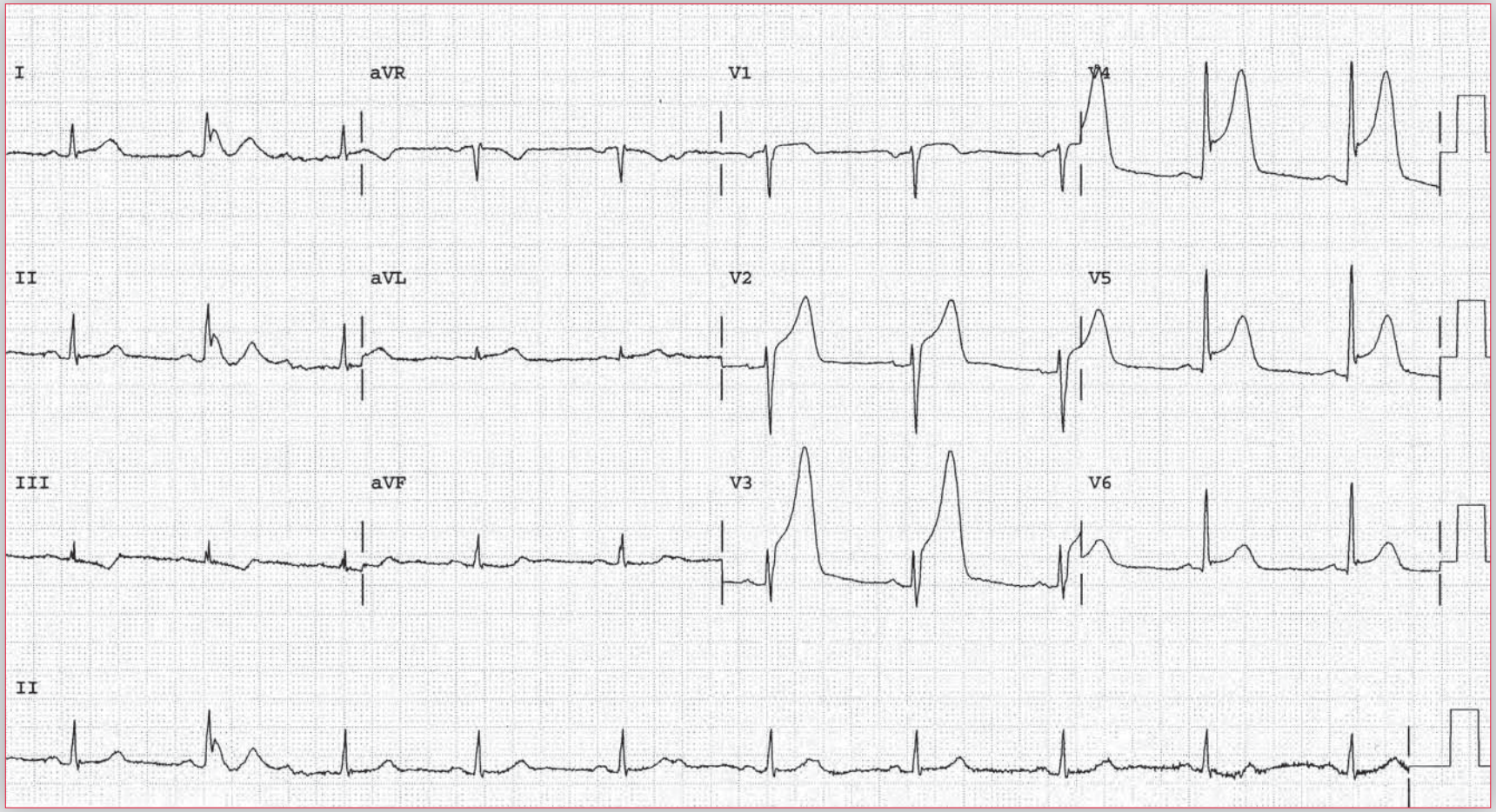

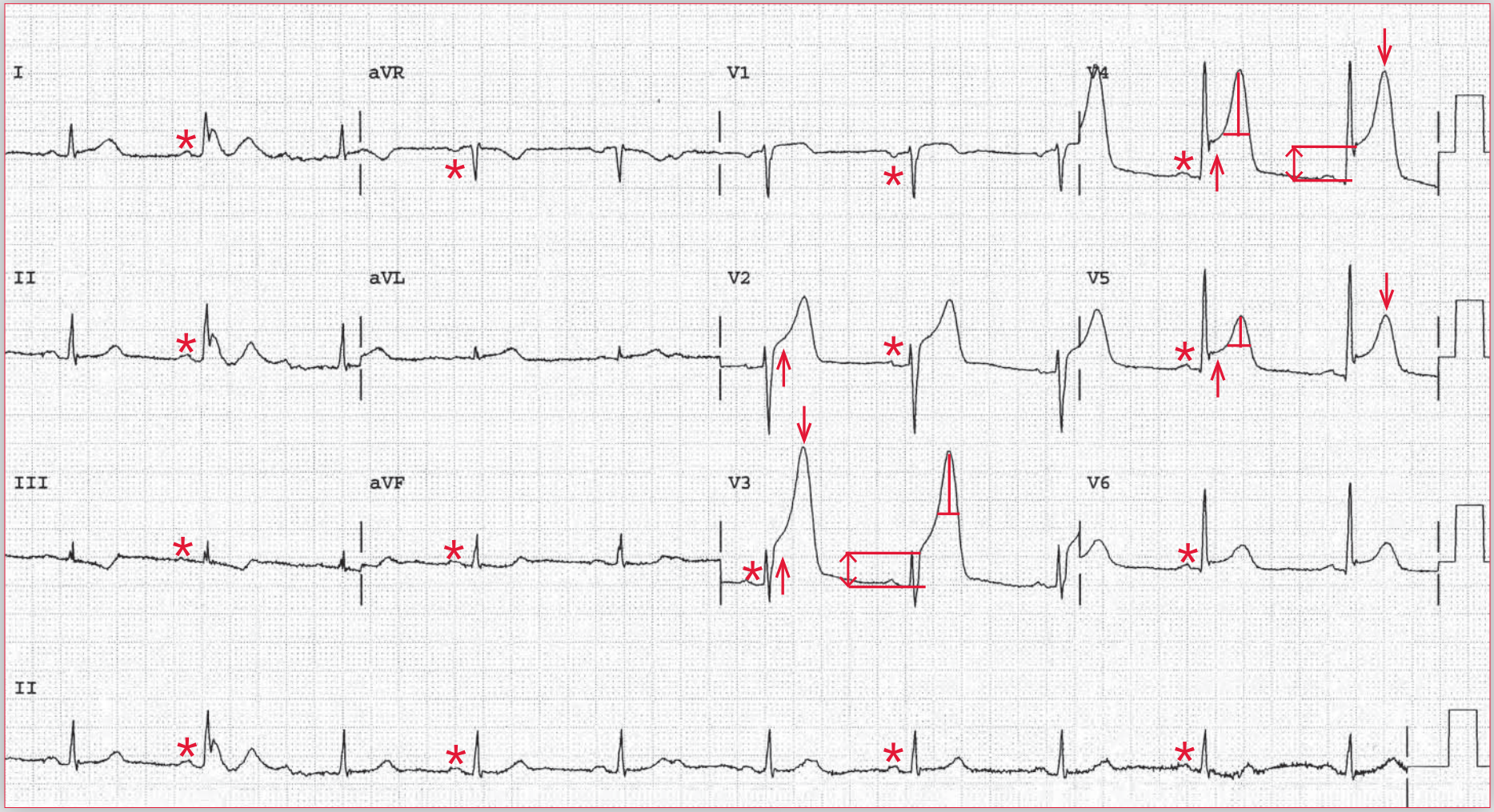

ECG 65 Analysis: Normal sinus rhythm, acute anterior wall ST-segment elevation myocardial infarction (STEMI), hyperacute T waves

There is a regular rhythm at a rate of 60 bpm. There are P waves (*) before each QRS complex, with a stable PR interval (0.18 sec). The P waves are positive in leads I, II, III, aVF, and V4-V6 and negative in lead aVR; they have a normal morphology. This is a normal sinus rhythm.

The QRS complex duration is normal (0.08 sec), and the morphology is normal. There is a normal axis, between 0° and +90° (positive QRS complex in leads I and aVF). The QT/QTc intervals are normal (360/360 msec). Noted are tall, peaked, and symmetric T waves (↓) in leads V3-V4 and symmetric T waves in leads V2-V5. In addition, there is ST-segment elevation (↑) in leads V2-V5; the ST-segment elevation is up to 6 mm (↕). The ST segments are still concave. This is an acute anterior wall ST-segment elevation myocardial infarction (STEMI; apex and possibly anterolateral).

An acute MI is identified by the presence of localized ST-segment elevation, hyperacute T waves (tall, peaked, and symmetric), and reciprocal ST-segment depressions (due to the same ST-segment elevations viewed from another angle or direction). The location of these ST-segment elevations identifies the region of the myocardium involved.

The goal of therapy for a patient with an acute anterior wall MI should be to restore adequate coronary blood flow in a timely manner. This can be accomplished either with primary angioplasty and stenting or thrombolysis. If the transit time to a primary angioplasty center is longer than 90 minutes, the patient should undergo thrombolysis; otherwise, primary angioplasty and stenting is preferred.

Because the ECG is available before the patient arrives in the emergency department, the treating physicians can expedite care by preparing for the patient's arrival. A commonly used metric for the efficiency of this process is the "door-to-balloon time" (DTBT), which measures the time from presentation to the emergency department to the inflation of the angioplasty balloon. Many hospitals set a goal DTBT of less than 90 minutes and door-to-needle time for thrombolysis of less than 30 minutes. ■

Notes

Practice Case 66

An 81-year-old man presents for his first visit with a new primary care physician. Over the past 6 months he has noted progressive dyspnea on exertion and pedal edema. He recalls an episode of severe chest discomfort and dyspnea about 8 months ago, but he did not seek medical attention at that time.

What does his ECG show?
What is the likely diagnosis?
What therapy is indicated?

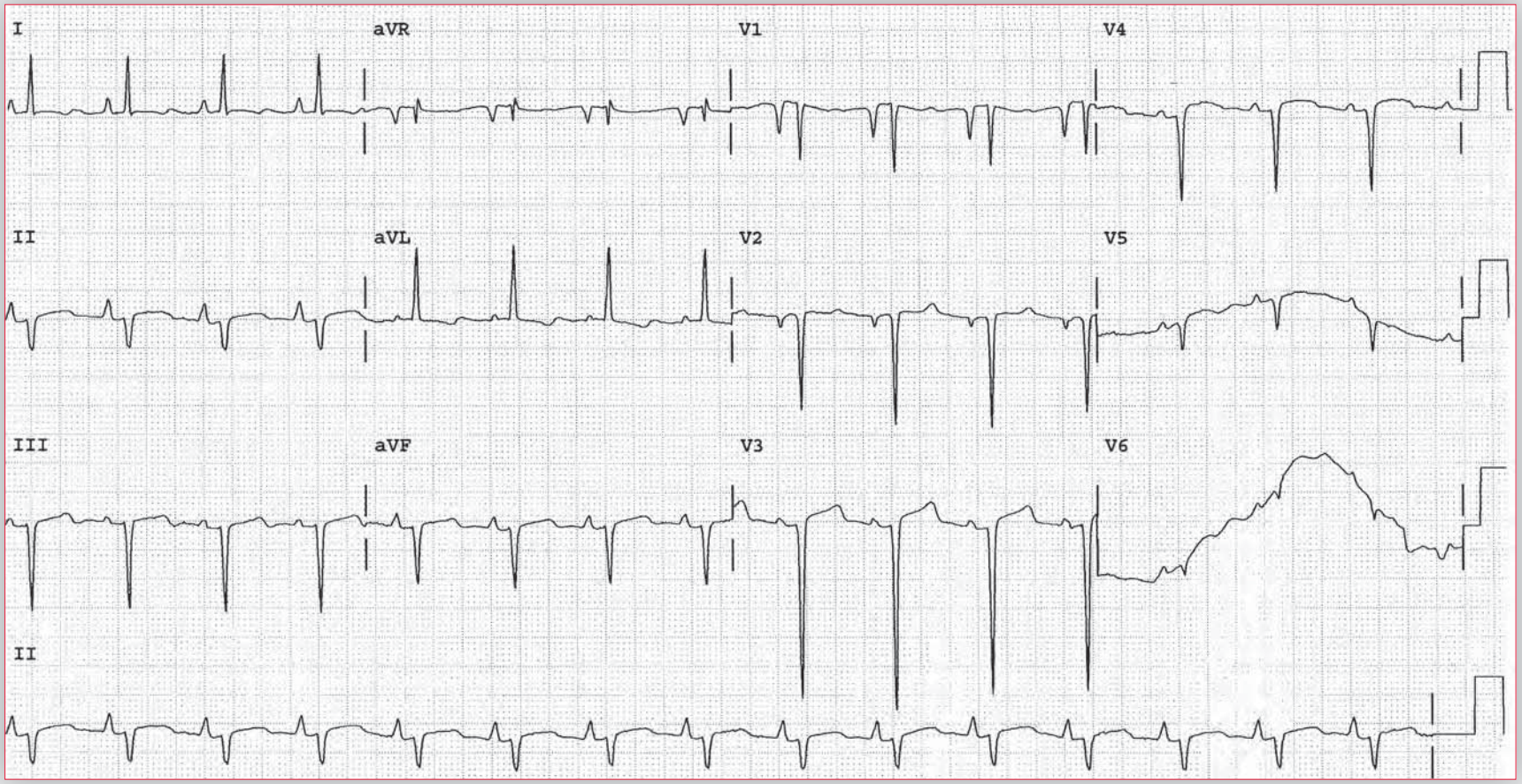

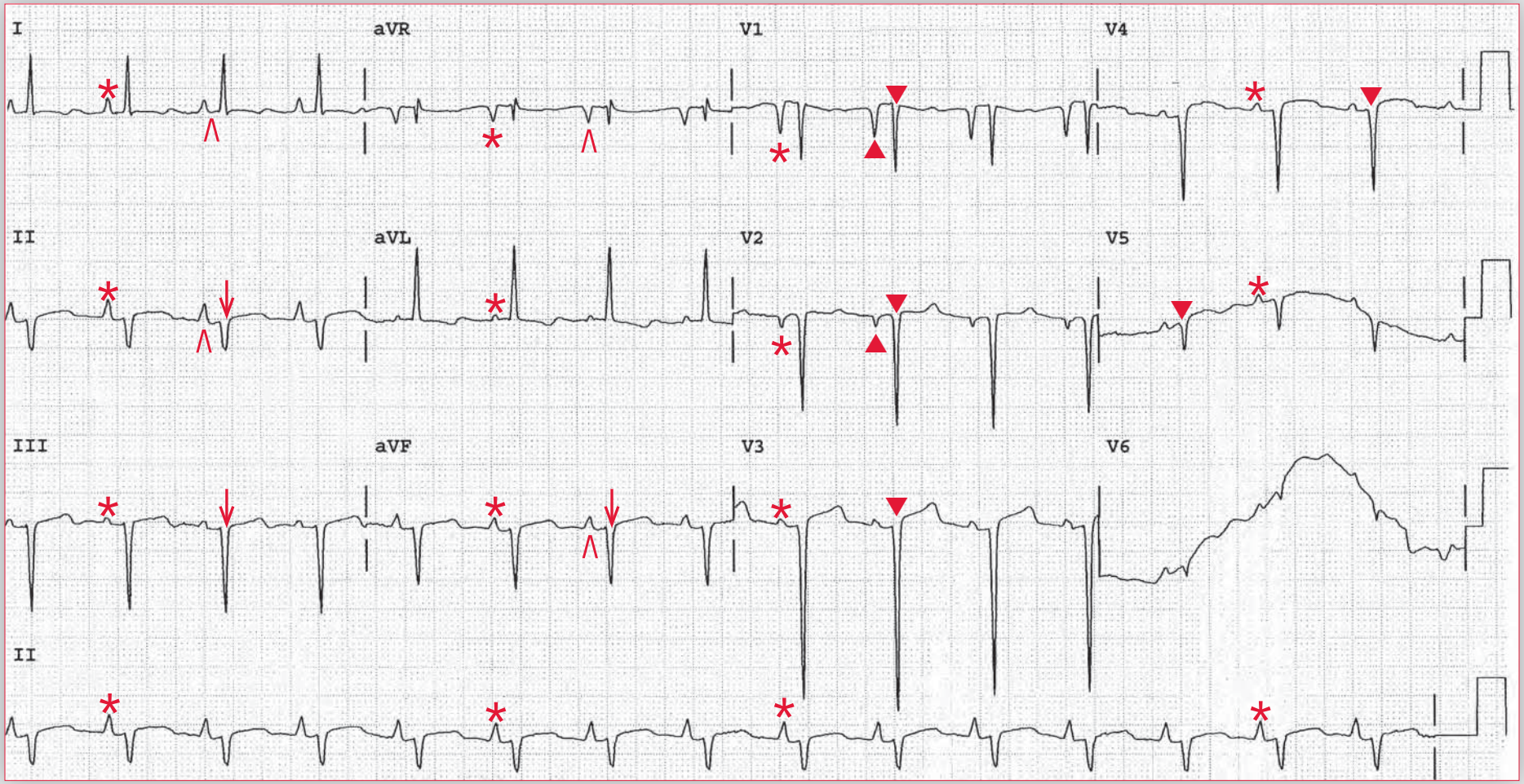

ECG 66 Analysis: Normal sinus rhythm, right atrial hypertrophy (abnormality), left atrial hypertrophy (abnormality), biatrial hypertrophy (abnormality), old inferior wall myocardial infarction (MI), old anterior wall MI, left axis deviation due to an old inferior wall MI

The rhythm is regular at a rate of 90 bpm. There is a P wave (*) in front of each QRS complex, with a stable PR interval (0.18 sec). The P wave is positive in leads I, II, aVF, and V4-V6 and negative in lead aVR. This is a normal sinus rhythm. The P wave is narrow (0.10 sec) and of increased amplitude (0.3 mV), especially in leads I, II, aVF, and aVR (^). The P waves in these leads have a morphology characteristic of right atrial hypertrophy (abnormality) or P pulmonale. The P waves in leads V1-V2 are deeply inverted or negative (▲), which is a feature of left atrial hypertrophy (abnormality). This represents biatrial hypertrophy (abnormality).

The QRS complex duration is normal (0.08 sec), and the axis is extremely leftward, between –30° and –90° (positive QRS complex in lead I and negative QRS complex in leads II and aVF). However, the QRS complex has a QS morphology in these leads (↓), consistent with a diagnosis of a chronic (old) inferior wall myocardial infarction (MI). The left axis deviation is not the result of a conduction problem (*ie*, it is not a left anterior fascicular block). There is also a QS complex in leads V1-V5 (▼), diagnostic for an extensive chronic (old) anterior wall MI. The QT/QTc intervals are normal (320/390 msec).

This patient has suffered a prior inferior and anterior wall MI. At this point the focus of care should be on treating modifiable risk factors and reducing the likelihood of future coronary events. This would include controlling blood pressure, screening for diabetes, quitting smoking, and treating hyperlipidemia. Most patients like this would be treated with a daily aspirin, an HMG-CoA reductase inhibitor (statin), and an anti-hypertensive regimen.

When both an inferior wall MI and a large anterior wall MI are present, there can be a significant reduction in left ventricular systolic function, although this patient does not complain of symptoms of low stroke volume and low cardiac output. The finding of biatrial hypertrophy does suggest elevated ventricular filling pressures and perhaps some degree of occult heart failure. An echocardiogram is warranted to assess chamber size and function. Stress testing, once symptoms are treated and the patient is stable, is useful for establishing functional status and predicting outcome as well as risk stratification if he again develops exertional chest discomfort. ■

Practice Case 67

A 62-year-old man with multiple cardiovascular risk factors, including insulin-dependent diabetes, dyslipidemia, and hypertension, undergoes a stress test for evaluation of dyspnea on exertion. He exercises for 6 minutes, 38 seconds without

ECG 67A

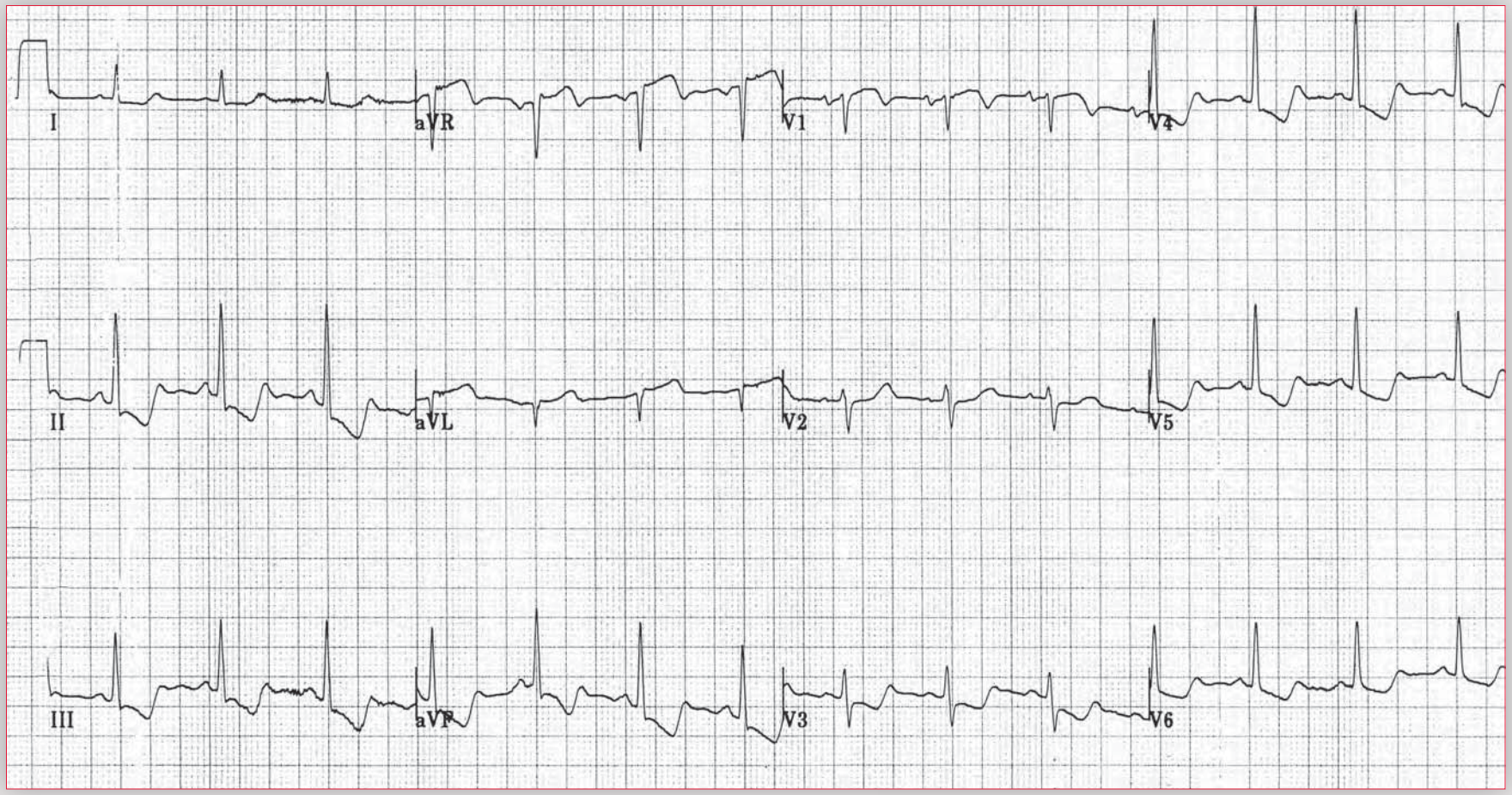

developing dynamic ECG changes or chest pain. He stops the test due to fatigue. Blood pressure at the time was 220/110 mm Hg. Two minutes into recovery, his ECG changes (67A). His baseline pre-exercise ECG is also shown (67B).

What does his posttest ECG show?

What is the likely diagnosis?

ECG 67B

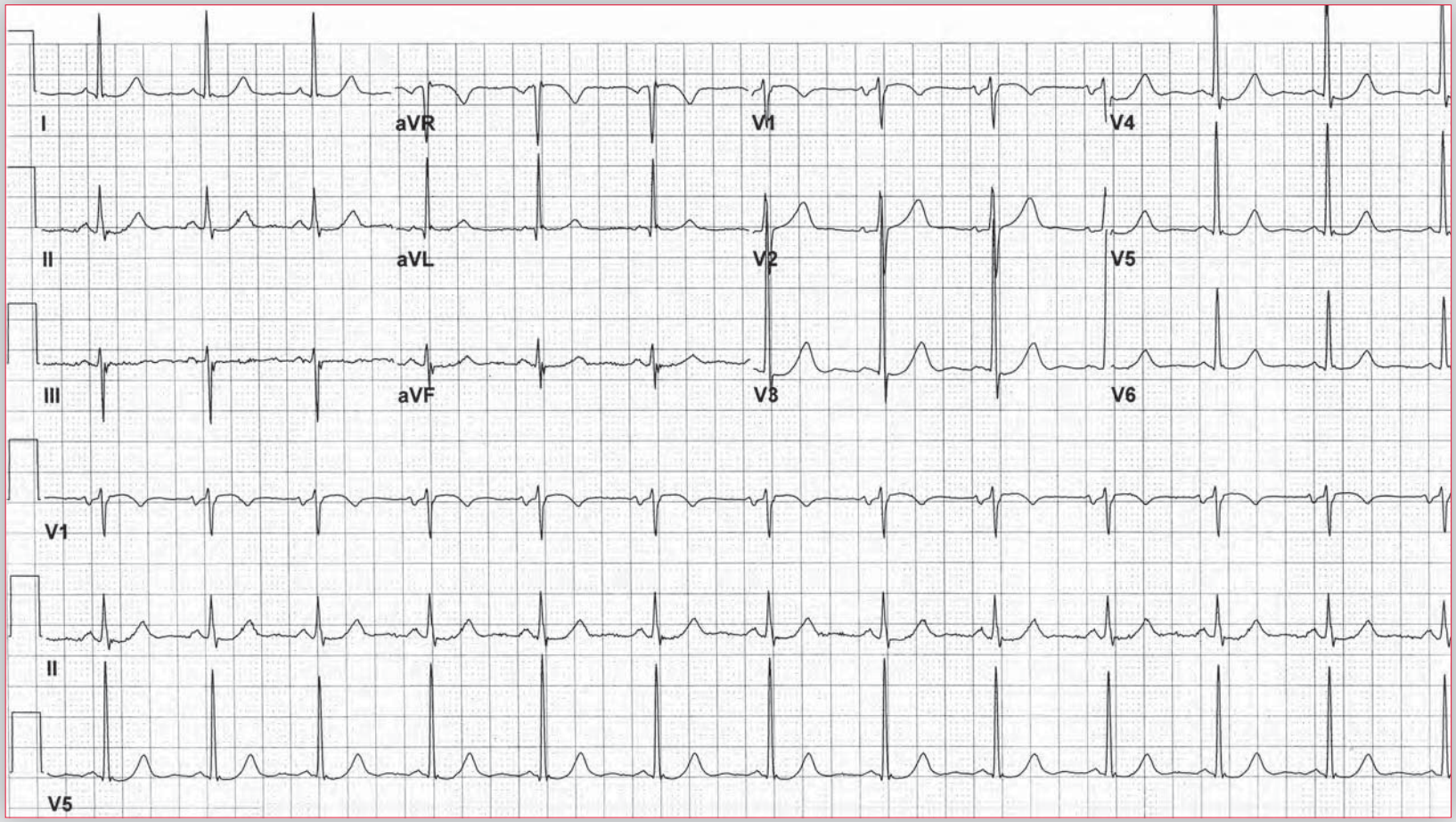

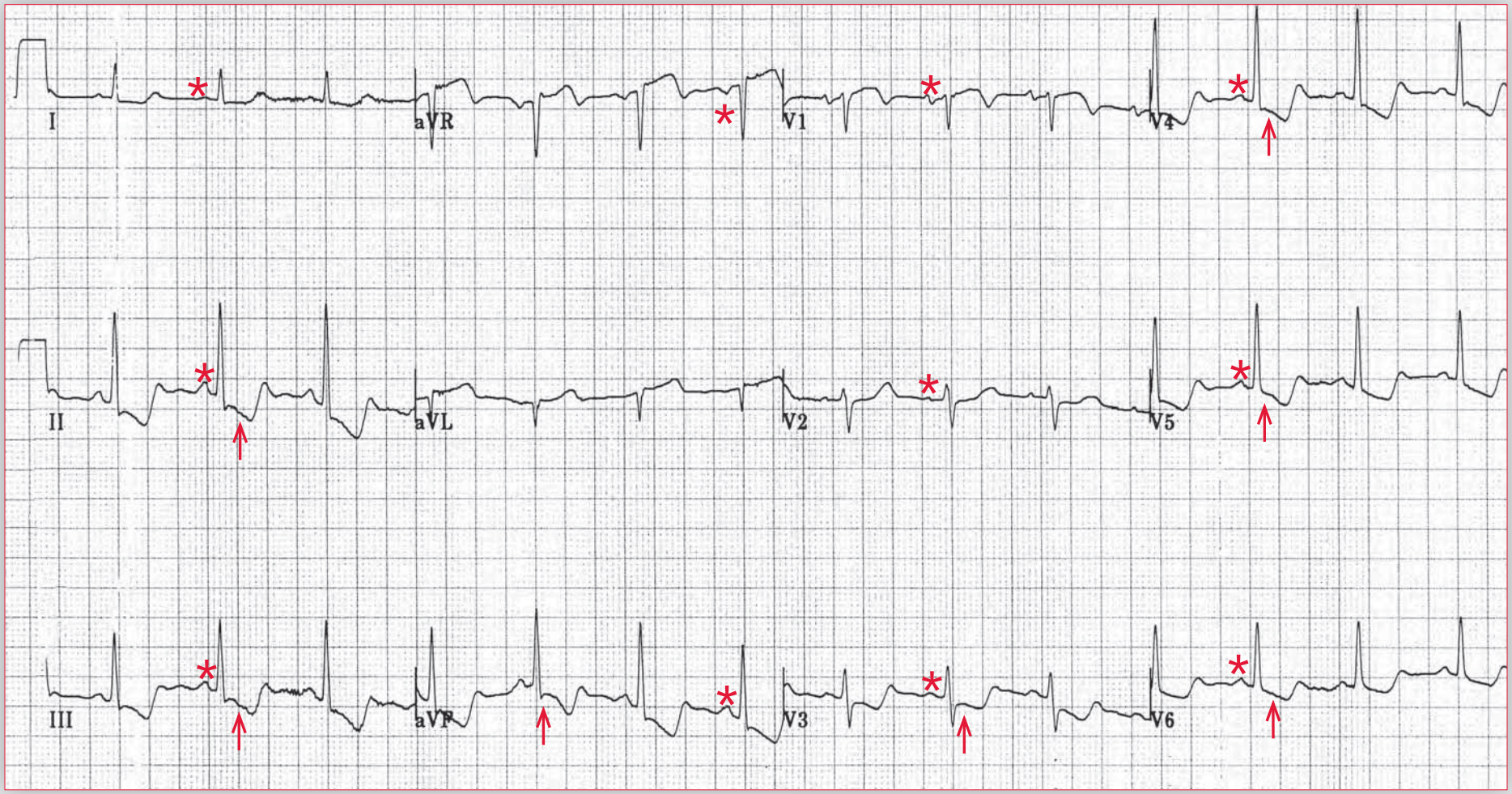

ECG 67A Analysis: Normal sinus rhythm, downsloping ST-segment depression

ECG 67A was obtained during recovery after an exercise test. There is a regular rhythm at a rate of 88 bpm. There is a P wave (*) before each QRS complex, with a stable PR interval (0.16 sec). The P wave is upright in leads I, II, III, and V4-V6 and negative in lead aVR. The P-wave morphology is normal. This is a normal sinus rhythm.

The QRS complex duration is normal (0.08 sec), and there is a normal QRS morphology with normal R-wave progression from leads V1 to V6. The QRS axis is normal, between 0° and +90° (positive QRS complex in leads I and aVF). The QT/QTc intervals are normal (360/440 msec). There is significant J-point and ST-segment depression (↑) (up to 2 mm below baseline, *ie*, TP segment) in leads II, III, aVF, and V3-V6. The ST-segment depression is downsloping. Downsloping ST-segment depression is the type of ST-segment change that is most predictive of myocardial ischemia, most often the result of occlusive coronary artery disease.

continues

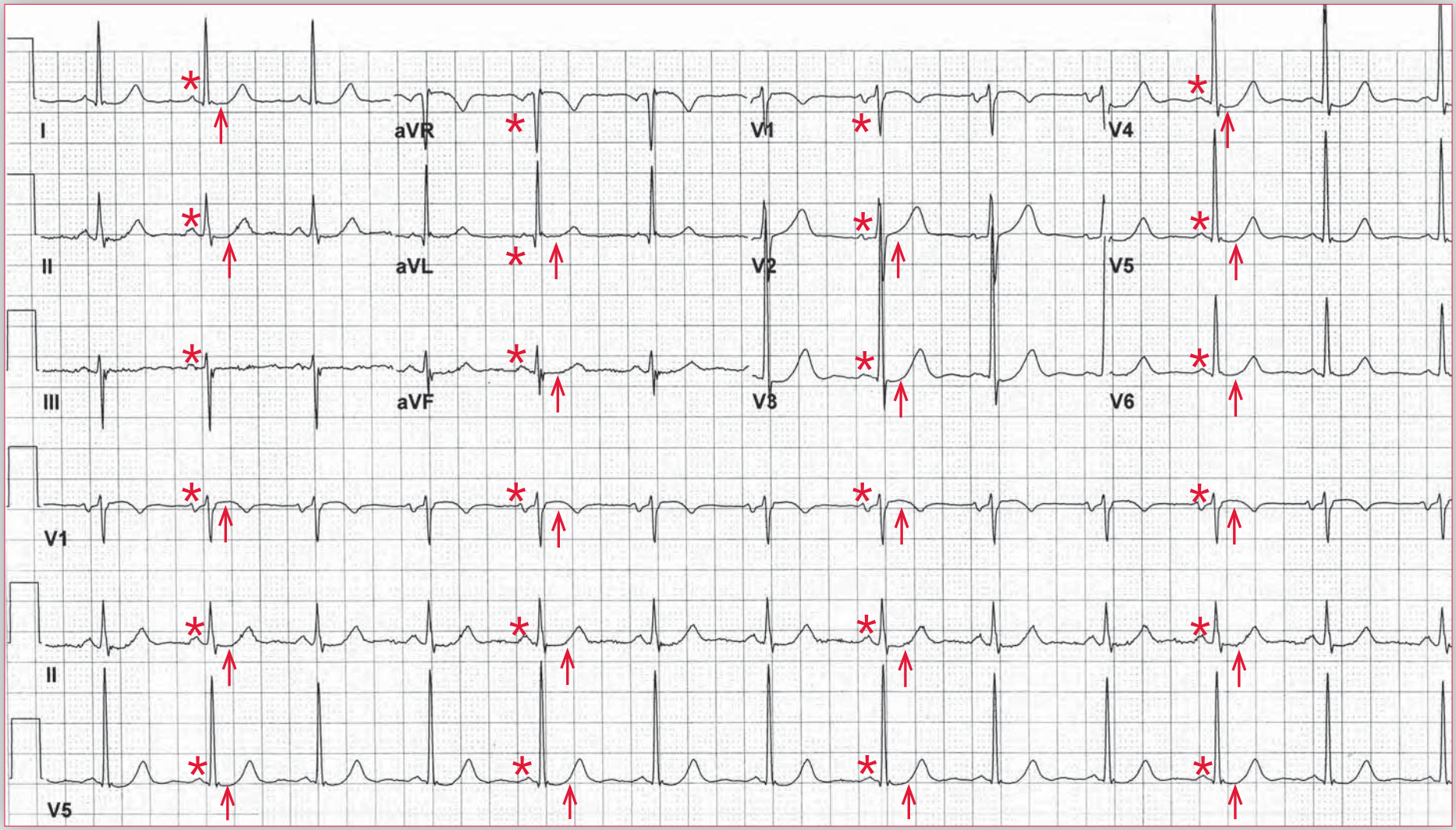

ECG 67B Analysis: Normal

ECG 67B is the baseline ECG obtained prior to the exercise test. The P waves (*), PR interval, QRS complexes, QT interval, and T waves are normal and are the same as those seen in **ECG 67A**. However, there is no J-point or ST-segment depression present. The ST segments are at baseline (↑) and have a normal concave morphology.

Although the stress test is positive for myocardial ischemia based on the ST-segment depression, the depressions occurred in the absence of symptoms and were associated with a significant hypertensive response. Not uncommonly, ST-segment changes occur after exercise, during recovery. This is likely due to the fact that during recovery there is still an increase in heart rate, blood pressure, and inotropy. Additionally, after exercise patients lie on a bed or stretcher, which results in an increase in venous return or preload—another factor that increases myocardial oxygen demand.

Stress tests should always be interpreted in the context of the patient's pretest probability of coronary artery disease. This patient with diabetes, dyslipidemia, hypertension, and a history of dyspnea on exertion has a high pretest probability of coronary artery disease. In this setting, the probability of a false-positive test is very low. Further medical therapy is warranted, even though the patient does not give a history of angina. However, diabetics often have discomfortless ischemia (*ie*, they do not experience angina but do have other symptoms that in patients with angina often occur along with the chest discomfort, including fatigue, diaphoresis, nausea, and shortness of breath or dyspnea on exertion).

Therapy should be directed at controlling exercise-induced hypertension as well as modifying risk factors. Therapy includes aspirin, an angiotensin-converting enzyme inhibitor, a statin, and a β-blocker as well as a long-acting nitrate as the patient does have evidence of ischemia associated with the symptom of dyspnea on exertion. However, there might still be uncertainty about the presence of significant coronary artery disease as the patient had a significant increase in blood pressure, which would also result in ST-segment depression due to impaired subendocardial blood and oxygen supply. In addition, exercise did not provoke his symptom of shortness of breath. In this situation, exercise testing could be repeated with echocardiography to look for the development of a wall motion abnormality correlating with the ST-segment changes. In some situations diagnostic coronary angiography would be indicated to define the coronary anatomy. If severe disease is present, percutaneous or surgical revascularization might be necessary. ■

Notes

Practice Case 68

A 52-year-old man presents to the emergency department with chest discomfort occurring at rest. He has had several episodes similar to this over the past few years but has not sought medical attention. On exam, he is noted to have jugular venous distension, trace pedal edema, and bilateral rales. The first set of cardiac markers is negative.

What does his ECG show?

What is the likely diagnosis?

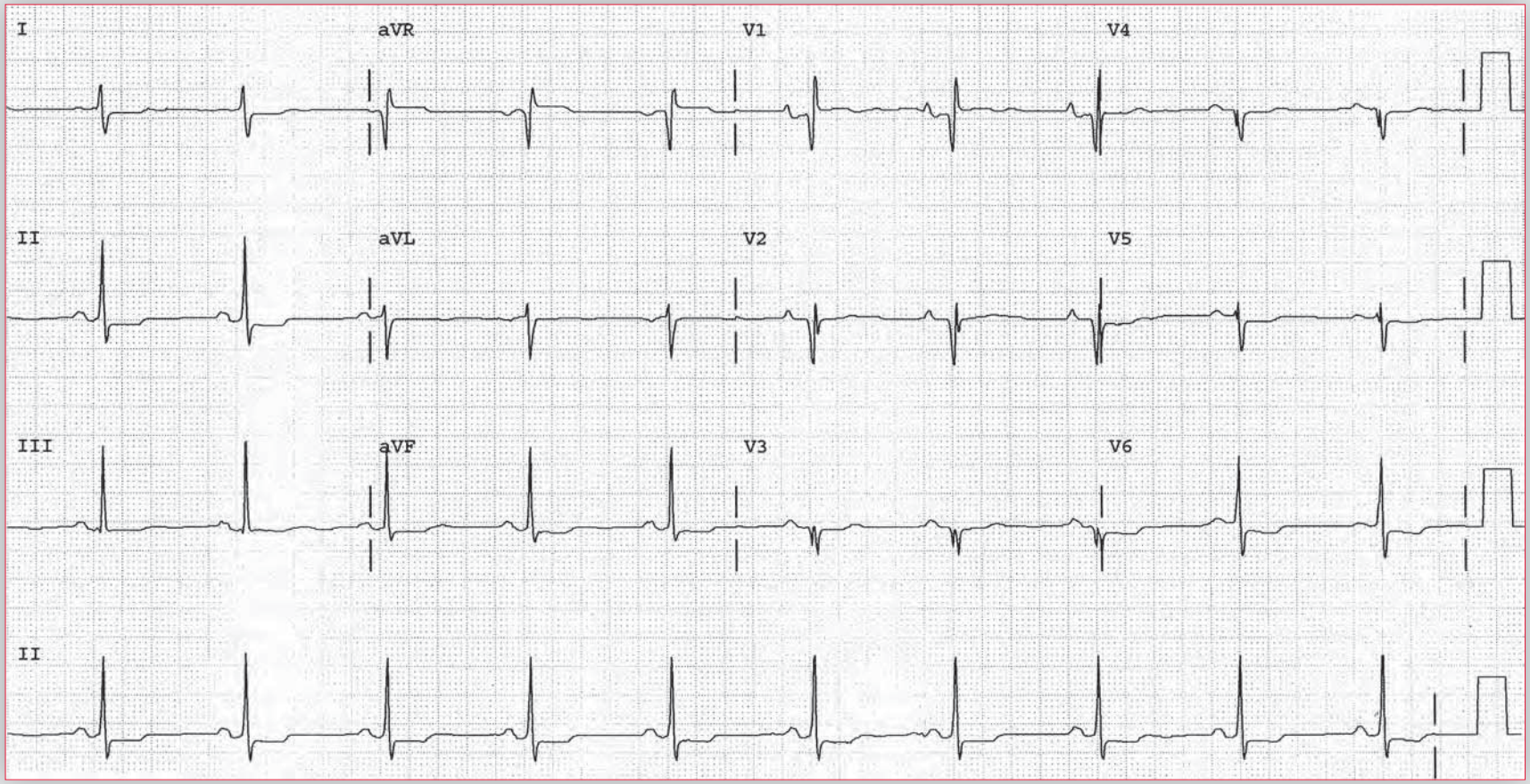

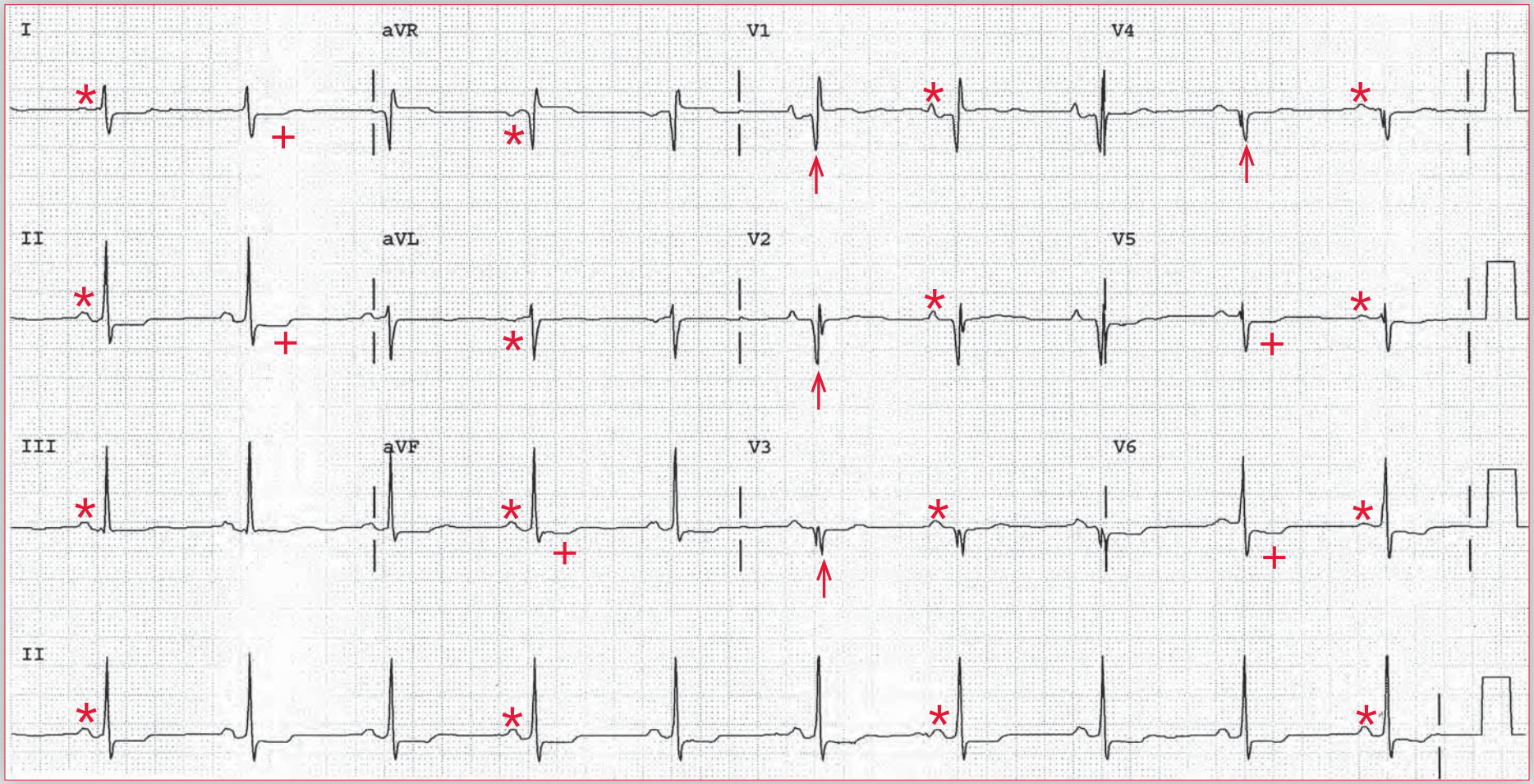

ECG 68 Analysis: Normal sinus rhythm, old anteroseptal and anteroapical myocardial infarction, ST-segment depression (ischemia)

There is a regular rhythm at a rate of 60 bpm. There is a P wave (*) before each QRS complex, with a stable PR interval (0.20 sec). The P wave is positive in leads I, II, aVF, and V4-V6 and negative in lead aVR. This is a normal sinus rhythm.

The QRS complex duration is normal (0.10 sec), and the axis is normal, about +90° (biphasic QRS complex in lead I and positive QRS complex in lead aVF). The QT/QTc intervals are normal (360/360 msec). There are significant Q waves (↑) in leads V1-V4, diagnostic for an old anteroseptal and anteroapical myocardial infarction. There are diffuse ST-T wave abnormalities with slight horizontal ST-segment depression (+) in leads I, II, aVF, and V5-V6, suggestive of ischemia.

This patient has significant coronary disease on the basis of his ECG and an acute coronary syndrome based on his clinical presentation. He has evidence of an old anterior wall myocardial infarction and possibly superimposed myocardial ischemia. Additionally, he has some evidence of congestive heart failure on examination. Given his evidence of prior myocardial infarction and heart failure as well as chest discomfort at rest, he is considered to be at high risk for adverse events. He should undergo coronary angiography within the next 48 hours. ■

Notes

Practice Case 69

A 55-year-old man presents to the emergency department with 2 days of sharp retrosternal chest pain. He tried taking an over-the-counter pain reliever (acetaminophen) with little effect. His ECG prompts activation of the coronary angiography suite. Before starting the procedure, the treating cardiologist reviews the presenting ECG.

What is the ECG diagnosis?

What further diagnostic testing would be useful?

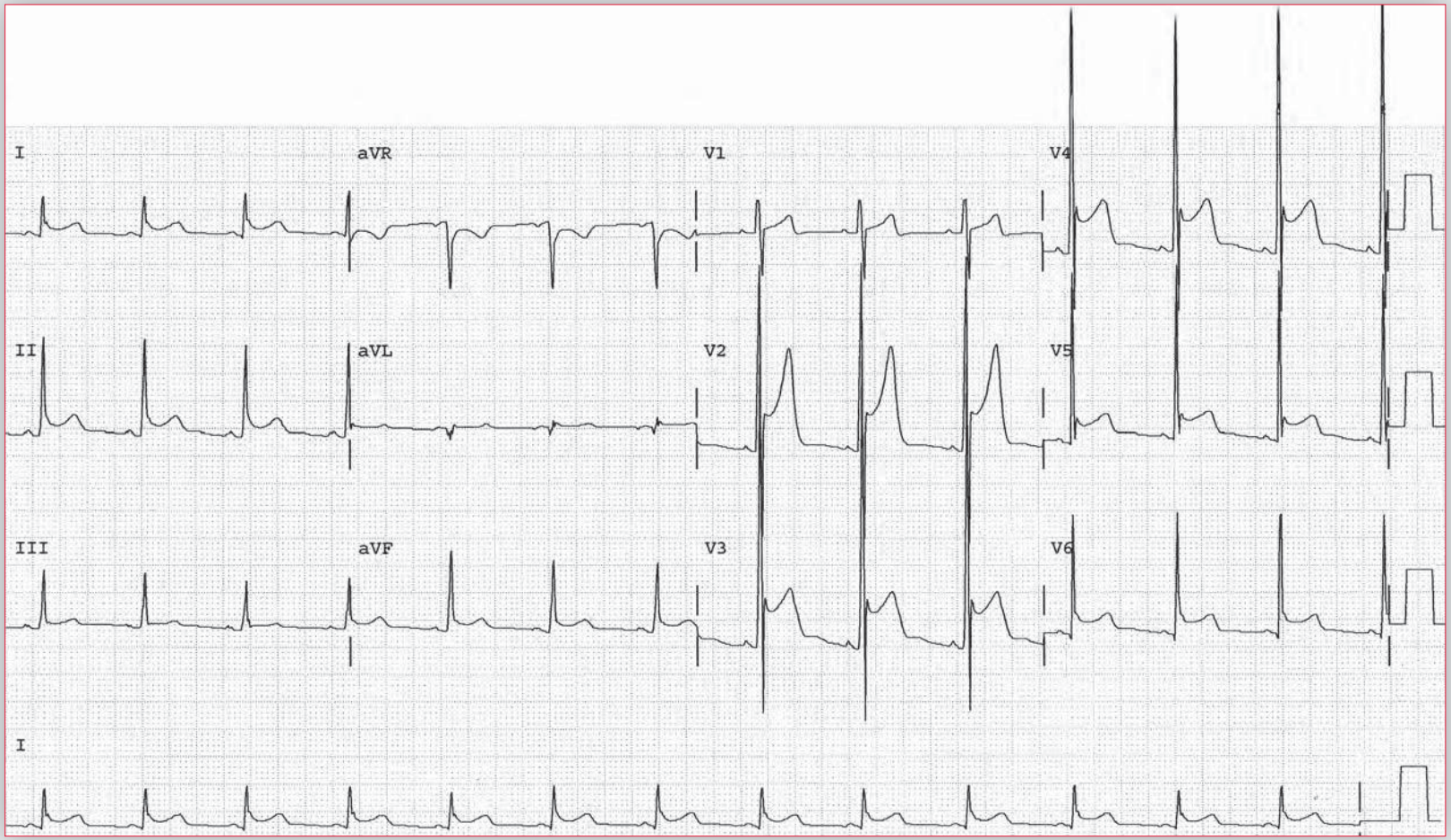

ECG 69 Analysis: Normal sinus rhythm, left ventricular hypertrophy, counterclockwise rotation (early transition), pericarditis

There is a regular rhythm at a rate of 80 bpm. There is a P wave (*) before each QRS complex, with a stable PR interval (0.14 sec). The P wave is positive in leads I, II, aVF, and V4-V6. This is a normal sinus rhythm. The P-wave morphology is normal.

The QRS complex duration is normal (0.08 sec), and there is a normal axis, between 0° and +90° (positive QRS complex in leads I and aVF). The QT/QTc intervals are normal (320/370 msec). The amplitude (voltage) of the R wave in leads V4 and V5 is increased (48 mm) ([ ), meeting one of the criteria for left ventricular hypertrophy (*ie*, S-wave depth or R-wave amplitude in any precordial lead ≥ 25 mm). The T wave (+) has an increased amplitude in lead V2 but is asymmetric and hence normal. Prominent T waves are often associated with left ventricular hypertrophy. Also noted is early transition with a tall R wave (←) in lead V2. This is due to counterclockwise rotation of the axis in the horizontal plane, determined by imagining the heart as viewed from under the diaphragm. With counterclockwise rotation, the left ventricular forces are seen early in the right precordial leads (*ie*, the tall R wave in lead V2).

There is widespread J-point and ST-segment elevation (^) of 6 to 7 mm (↕), apparent in leads I, III, aVR (ST-segment depression in this lead is actually elevation), aVF, and V2-V6. The ST segment has a normal concave morphology. Also noted is slight PR-segment depression, most obvious in leads V2-V3. The ECG shows pericarditis. Although J-point and ST-segment elevation can be seen with left ventricular hypertrophy and is termed early repolarization, this is usually present only in the lateral precordial leads and the J point and ST segments are not generally this elevated.

Although the marked ST-segment elevation raises concern for an acute myocardial infarction, this pattern is more typical of acute pericarditis. The ST segments have a normal concave morphology, the T waves are normal, the ST-segment elevations are diffuse, and there are no reciprocal changes. Additionally, this patient has had chest pain for 2 days and has not developed the pathologic Q waves that are typical of an evolving myocardial infarction. An echocardiogram to evaluate for wall motion abnormalities would be useful in determining if there is active myocardial ischemia. ■

Notes

Practice Case 70

A 48-year-old man with a 20 pack-year smoking history develops retrosternal chest pain while playing squash. He stops playing and sits to rest. When the pain does not remit, his partners bring him to a nearby emergency department, where an ECG is obtained.

What does his ECG show?

What is the likely diagnosis?

What coronary artery is likely to be involved?

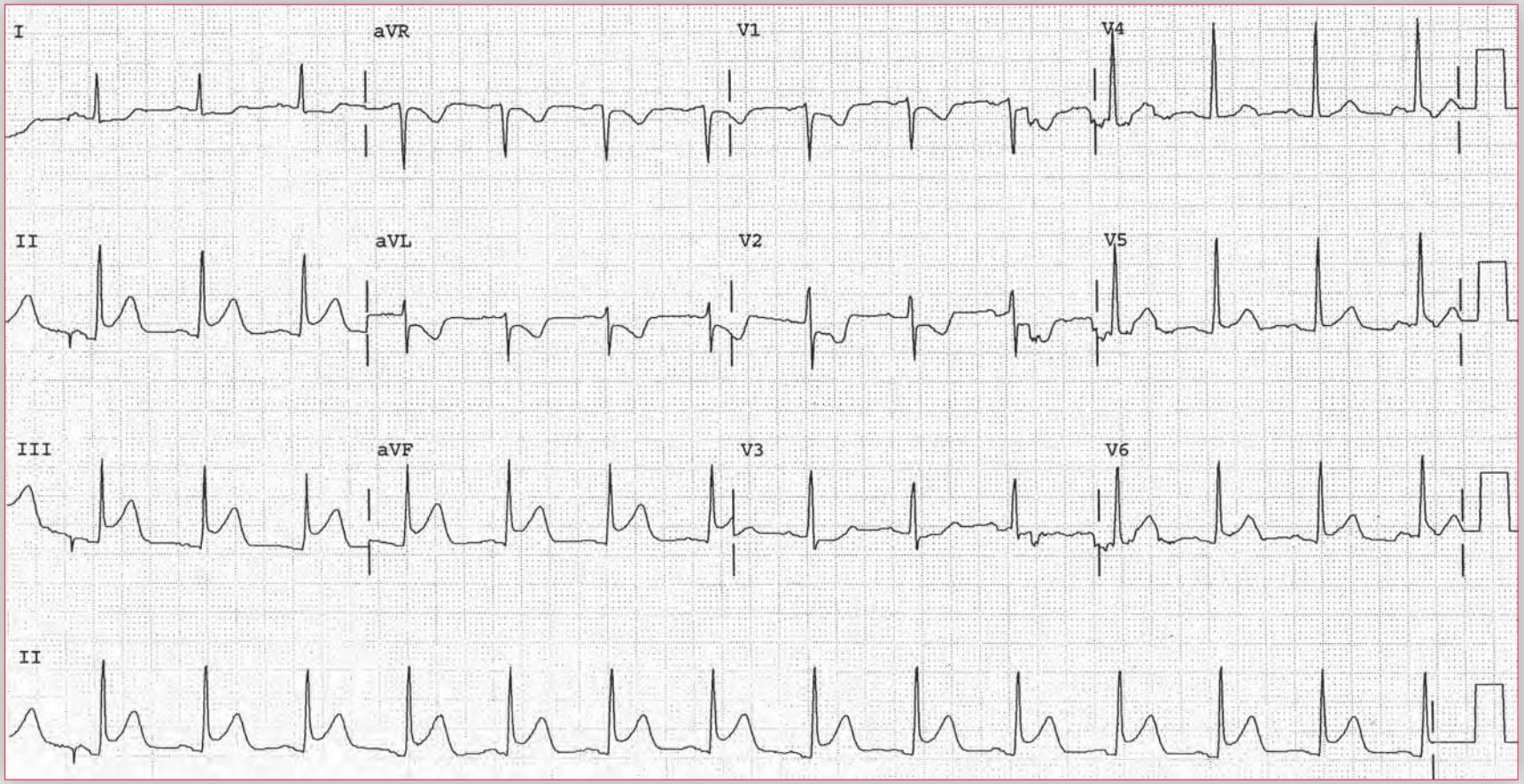

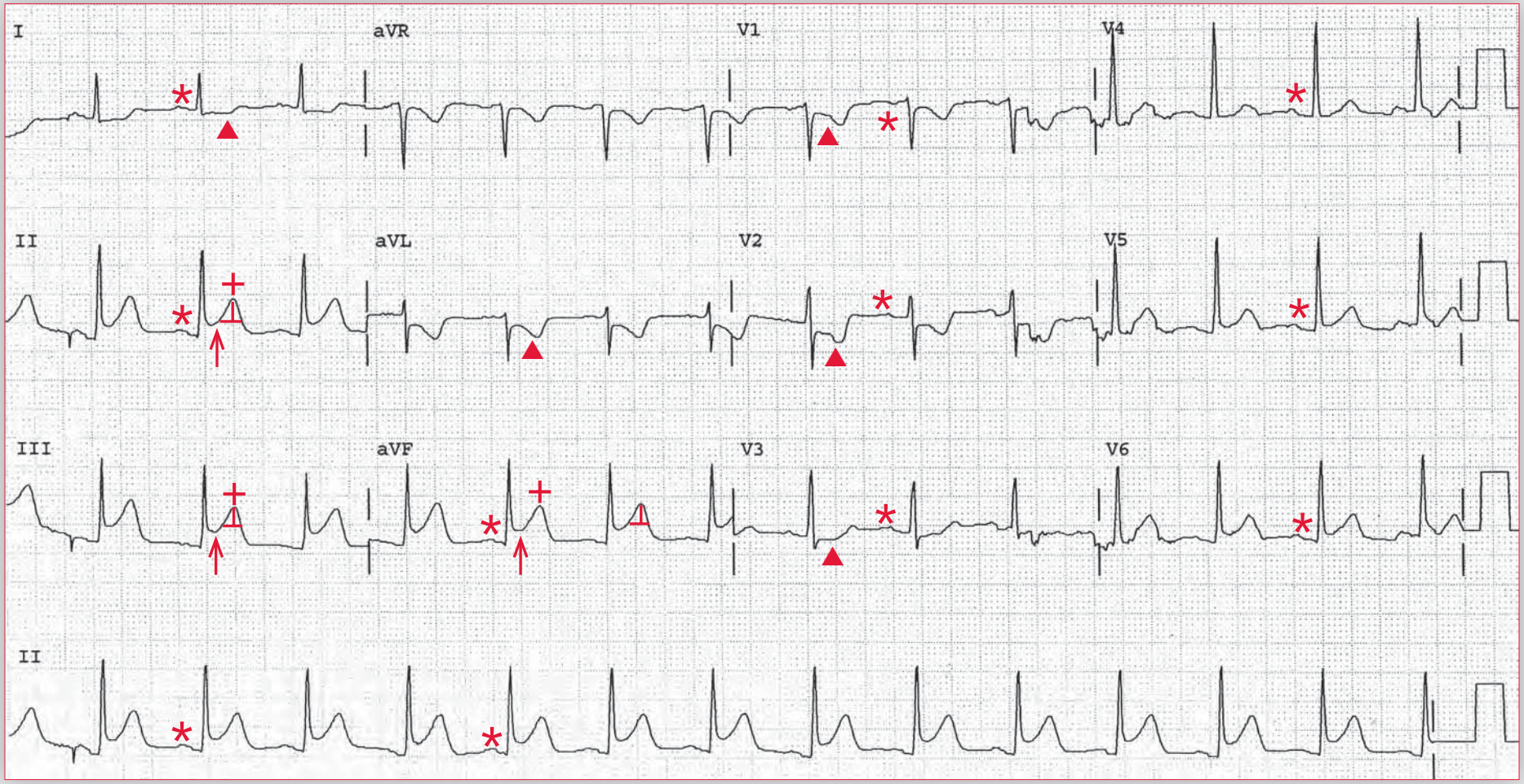

ECG 70 Analysis: Normal sinus rhythm, acute inferior wall ST-segment elevation myocardial infarction (STEMI)

There is a regular rhythm at a rate of 84 bpm. There is a P wave (*) before each QRS complex, with a stable PR interval (0.18 sec). The P wave is positive in leads I, II, aVF, and V4-V6 and negative in lead aVR. This is a normal sinus rhythm.

The QRS duration is normal (0.08 sec), and there is a normal morphology and axis, between 0° and +90° (positive QRS complex in leads I and aVF). The QT/QTc intervals are normal (340/400 msec). The T waves (+) in leads II, III, and aVF are tall and symmetric. In addition, there is ST-segment elevation (↑) in these leads and the ST segment has a normal concave morphology. This is an early acute inferior wall ST-segment elevation myocardial infarction (STEMI). Noted are ST-segment depression (▲) in leads I, aVL, and V1-V3. Reciprocal changes associated with an inferior wall myocardial infarction are usually seen in leads I and aVL. While the ST-segment depression in leads V1-V3 could represent reciprocal changes, in the setting of an inferior wall infarction they may be indicative of posterior wall involvement. In this situation it would be useful to place posterior leads under the left scapula (leads V7-V8, over the posterior wall of the left ventricle) to look for ST-segment elevation and possible posterior wall involvement.

In the case of a right dominant circulation, the posterior wall is supplied by the posterior left ventricular branch of the right coronary artery. In the case of a left dominant circulation, the posterior wall is supplied by branches of the circumflex artery. ■

Notes

Practice Case 71

A 54-year-old Taiwanese woman is referred to a cardiologist because of an abnormal ECG. She feels generally well but has had two episodes of syncope that came on without warning over the past 2 years. On exam, she has a palpable S4 but no other abnormalities.

What does her ECG show?
What is the likely diagnosis?
What further testing is indicated?

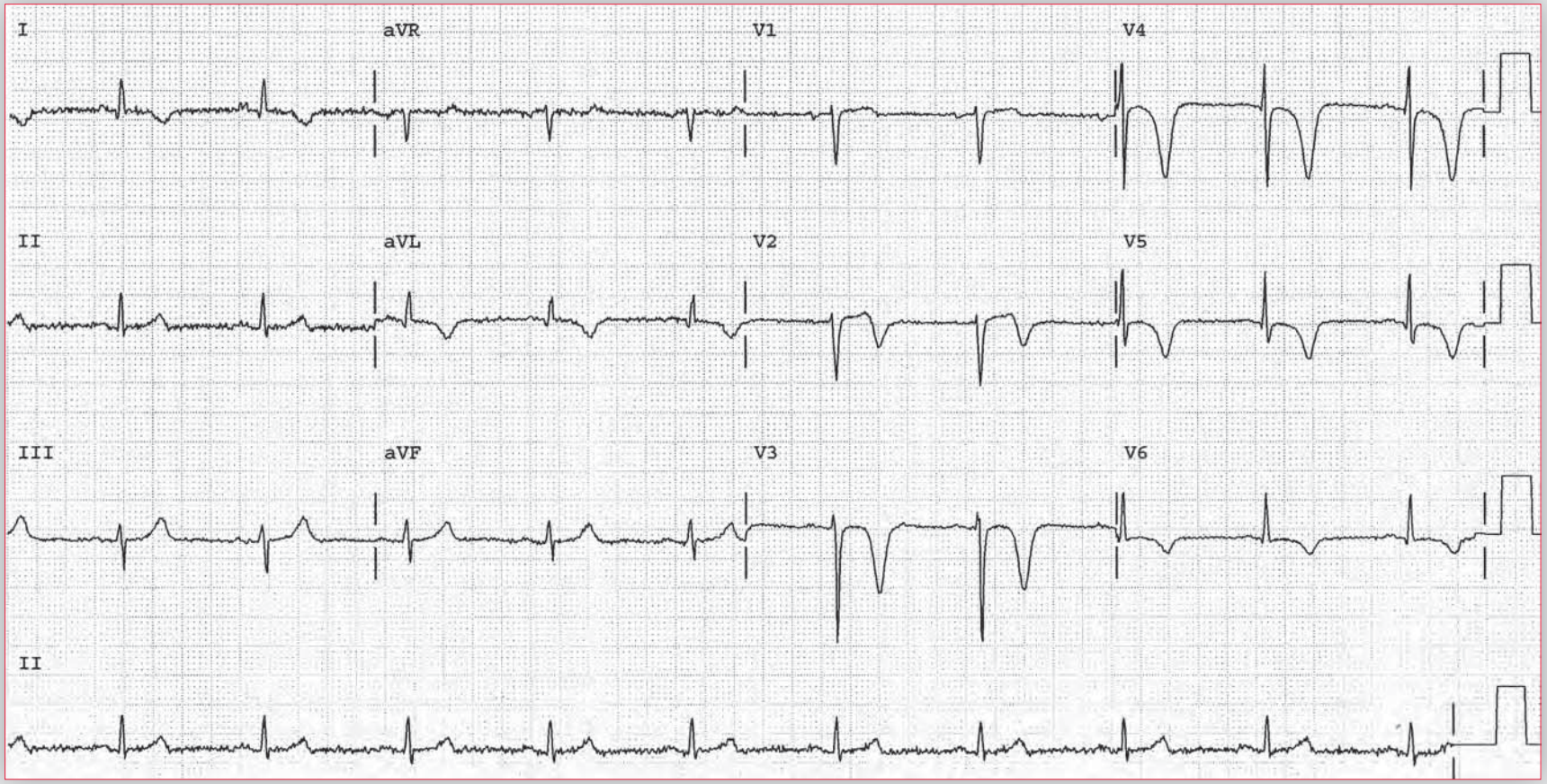

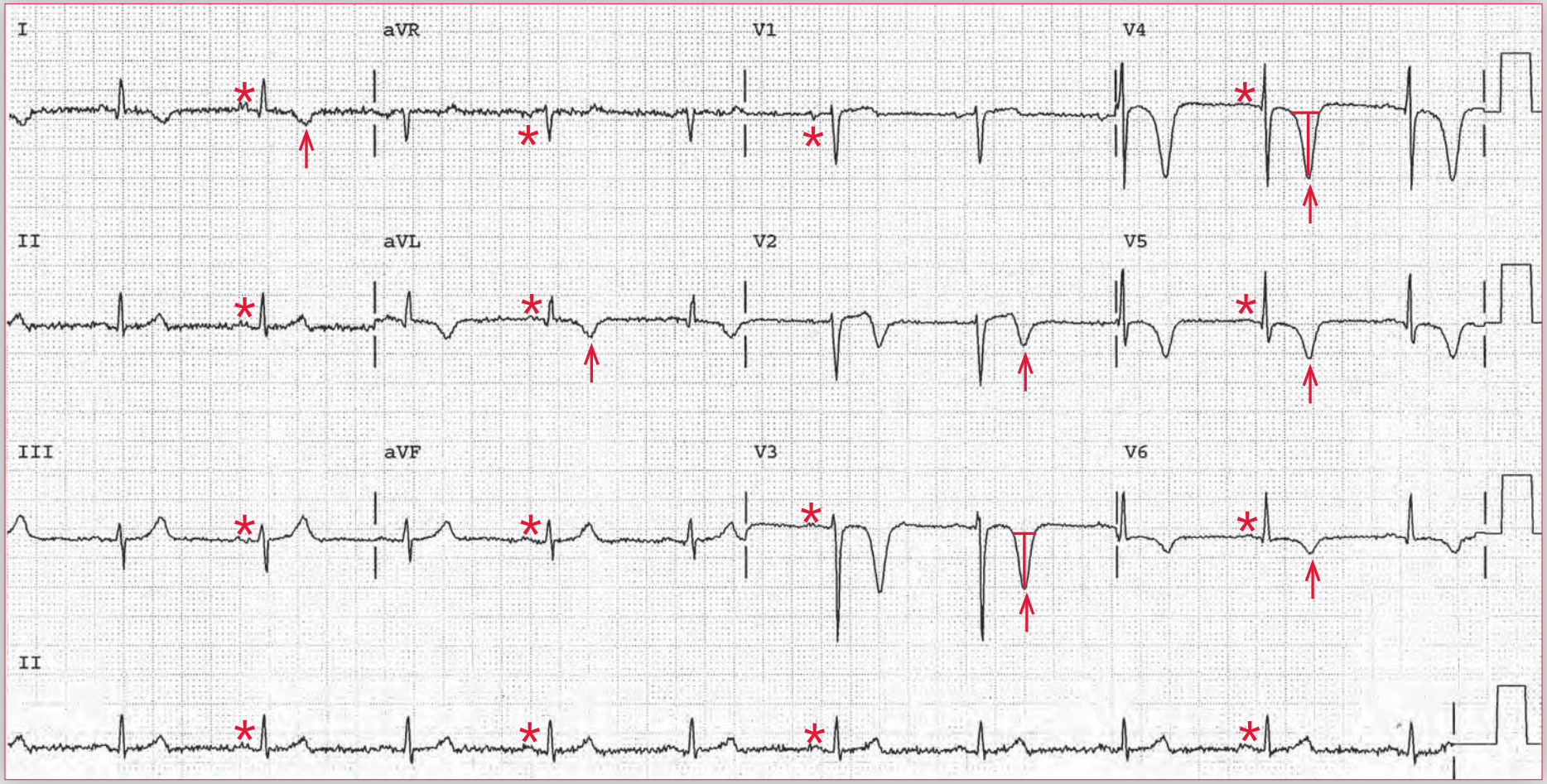

ECG 71 Analysis: Normal sinus rhythm, T-wave inversions

There is a regular rhythm at a rate of 60 bpm. There is a P wave (*) before each QRS complex, with a stable PR interval (0.20 sec). The P waves are positive in leads I, II, aVF, and V4-V6 and negative in lead aVR. This is a normal sinus rhythm.

The QRS complex duration is normal (0.08 sec), and the axis is normal at about 0° (positive QRS complex in lead I and biphasic QRS complex in lead aVF). The QRS morphology is normal. The QT/QTc intervals are normal (440/440 msec). There are deeply inverted T waves (↑) in leads I, aVL, and V2-V6. However, the T waves are asymmetric with a faster upstroke and a slower downstroke.

Diffuse T-wave inversions are nonspecific and not definitely the result of ischemia, especially since they are asymmetric. However, as this woman is from southeast Asia, the possibility of an apical variant of hypertrophic cardiomyopathy should be considered. This diagnosis is supported by the presence of prominent and inverted T waves across the left precordial leads (V3-V5); these T-wave changes are a frequent finding in this disease. An echocardiogram should be obtained. If there were an apical hypertrophic cardiomyopathy, the echocardiogram would show a thickened apex that obliterates the ventricular cavity at end systole. Unlike hypertrophic cardiomyopathy affecting the base of the heart, the apical variant does not cause left ventricular outflow tract obstruction. If she were to have this entity, strong consideration would be given to a ventricular tachyarrhythmia as the cause of her syncope. In this variant of hypertrophic cardiomyopathy, mechanical obstruction and decreased cardiac output do not occur. ■

Notes

Practice Case 72

A 68-year-old woman presents with marked dyspnea on exertion. She has been reluctant to seek medical care for much of her life, but her dyspnea is now preventing her from carrying out her daily activities. In recent weeks, she has gained about 15 pounds and notes marked swelling of her ankles. She feels a fullness in her abdomen and notes that her pants are no longer fitting.

What does her ECG show?

What is the likely diagnosis?

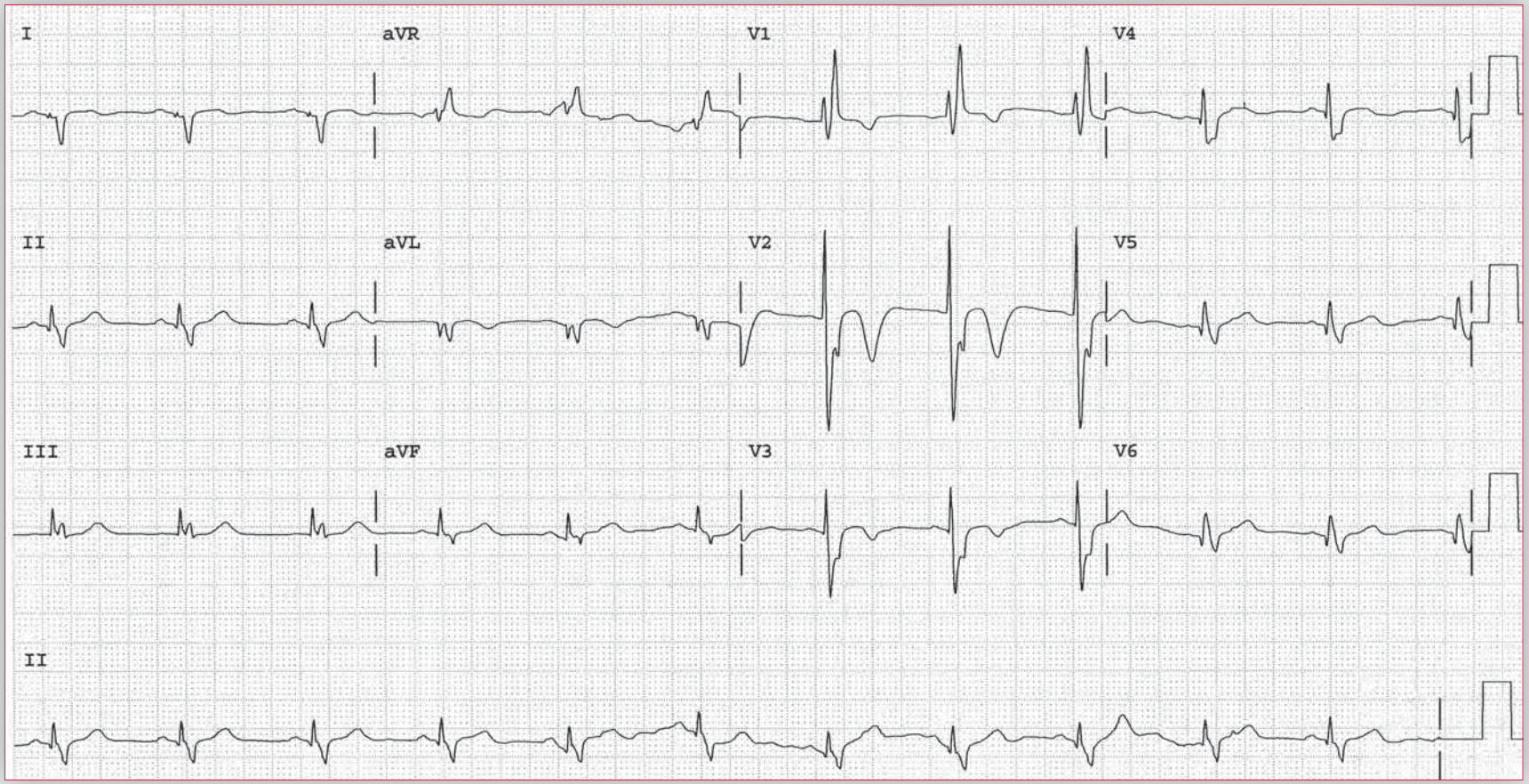

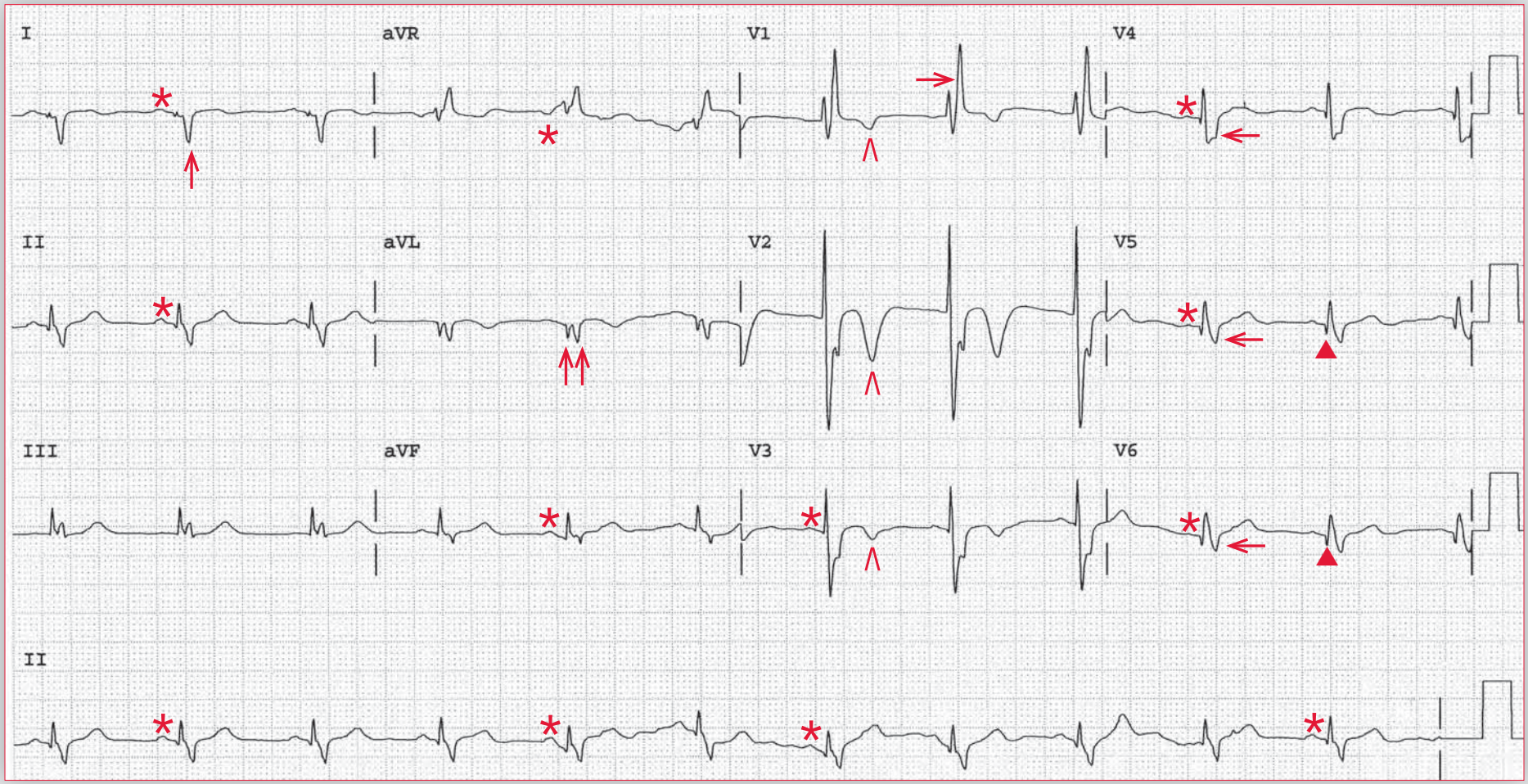

ECG 72 Analysis: Normal sinus rhythm, right bundle branch block (RBBB) associated with ST-T waves, old lateral wall myocardial infarction (MI), old anterolateral wall MI, right axis deviation due to an old lateral wall MI

There is a regular rhythm at a rate of 68 bpm. There are P waves (*) before each QRS complex, with a stable PR interval (0.16 sec). The P waves are upright in leads I, II, aVF, and V4-V6 and negative in lead aVR. This is a normal sinus rhythm.

The QRS complex duration is prolonged (0.16 sec), and there is a typical right bundle branch block morphology, that is, an RSR′ morphology in lead V1 (→) and a broad terminal S wave (←) in leads V4-V6. There are T-wave inversions (^) in leads V1-V3 that are associated with the right bundle branch block (RBBB). The QT/QTc intervals are normal (400/430 msec and 320/340 msec when corrected for the prolonged QRS complex duration).

There is a broad QS complex in lead I (↑) and two distinct negative deflections in lead aVL (↑↑), reflecting not only the RBBB but also a lateral wall myocardial infarction (MI) (*ie*, Q waves in leads I and aVL). The right axis deviation (negative QRS complex in lead I and positive QRS complex in lead aVF) is the result of the lateral wall infarction and not a conduction abnormality (*ie*, a left posterior fascicular block, in which the QRS complex has an rS morphology in leads I and aVL). There are also significant Q waves in leads V5-V6 (▲), diagnostic for an old anterolateral MI.

This patient has clinical evidence of both right- and left-sided heart failure. Her ECG shows evidence of an old MI, which likely resulted in left ventricular systolic dysfunction. Although there are many etiologies for an RBBB, this conduction abnormality associated with clinical evidence of right-sided heart failure may be a consequence of longstanding left-sided heart failure with secondary pulmonary hypertension and now marked right ventricular dysfunction. ■

Notes

Practice Case 73

A 79-year-old woman with known mild aortic stenosis presents to her cardiologist after a hiatus of 5 years for evaluation of chest discomfort. She reports that the discomfort occurs with minimal activity such as doing light housework. She denies any pain at rest.

What does her ECG show?

What is the likely diagnosis?

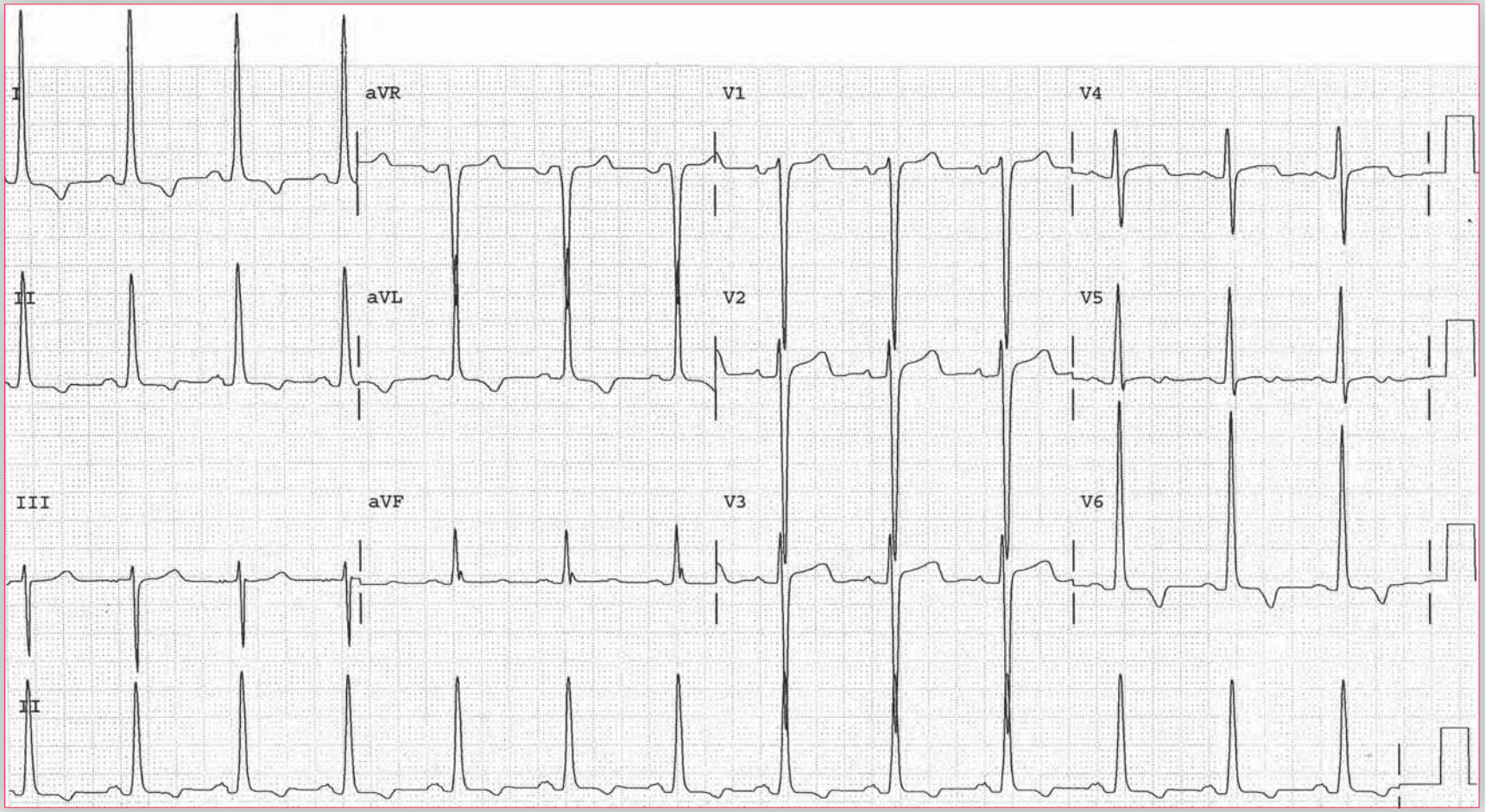

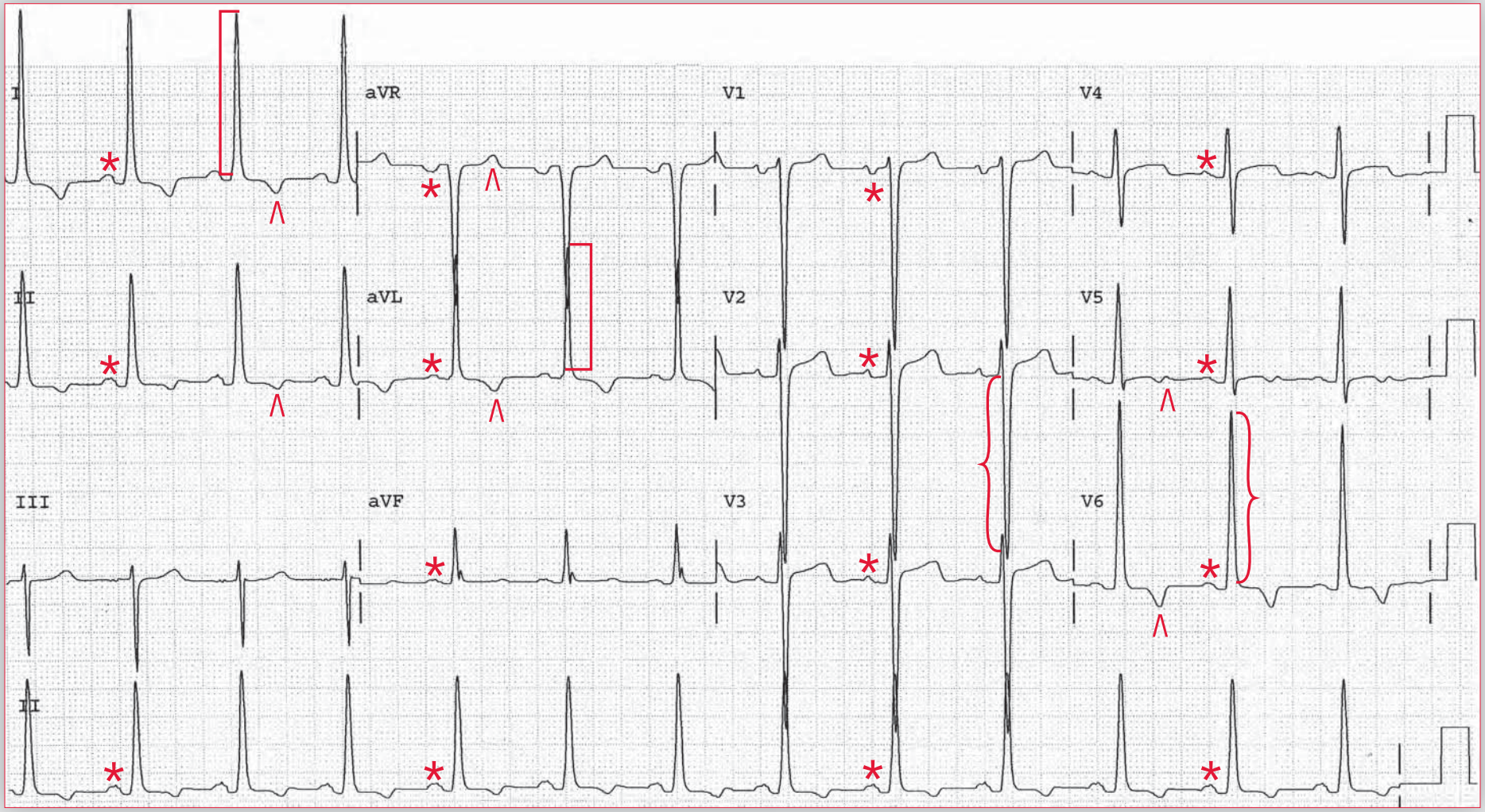

ECG 73 Analysis: Normal sinus rhythm, intraventricular conduction delay, left ventricular hypertrophy (LVH) with associated ST-T wave abnormalities

There is a regular rhythm at a rate of 76 bpm. There are P waves (*) before each QRS complex, and the P waves are upright in leads I, II, aVF, and V4-V6 and negative in lead aVR. The PR interval is stable (0.18 sec). The P-wave morphology is normal. This is a normal sinus rhythm.

The QRS complex duration is prolonged (0.12 sec), but the morphology is normal. This is, therefore, an intraventricular conduction delay. The QRS axis is normal, between 0° and +90° (positive QRS complex in leads I and aVF). The QT/QTc intervals are slightly prolonged (400/450 msec) but are actually normal when the increased QRS complex duration is considered (360/410 msec). There is marked increased amplitude of the QRS complex: 22 mm in lead aVL (]), 28 mm in lead I ([), and 31 mm in lead V6 (}). In addition, the S wave depth is 32 mm in lead V2 ({). These meet various criteria for left ventricular hypertrophy (LVH; R-wave amplitude in lead aVL ≥ 11 mm, R-wave amplitude in any limb lead ≥ 20 mm, and S-wave depth or R-wave amplitude in any precordial lead ≥ 25 mm). The presence of LVH is the reason for the intraventricular conduction delay as it takes longer to depolarize the thickened left ventricular myocardium. Associated ST-T wave changes (^) are also seen in leads I, II, aVR (T wave should be negative in this lead), aVL, and V5-V6. These repolarization changes are the result of chronic subendocardial ischemia due to reduced subendocardial blood flow resulting from the hypertrophy.

In this case, LVH is likely attributable to aortic stenosis. Over time, the increased force generated by the left ventricle to overcome the stenotic aortic valve results in compensatory LVH. Exertional angina is a typical presenting symptom of progressive aortic stenosis (along with shortness of breath and syncope). Angina may be the result of concomitant coronary artery disease or due to relative ischemia and poor reserve of the hypertrophied myocardium, with a reduction in the supply of blood and oxygen to the subendocardium. Asymptomatic aortic stenosis can exist for many years before producing symptoms, but once a patient becomes symptomatic, there is often rapid progression of the disease. Aortic valve replacement is the only effective therapy for aortic stenosis and is indicated once a patient develops angina, syncope, or symptoms of heart failure.

The degree of aortic stenosis (as well as LVH, left atrial hypertrophy, left ventricular dysfunction, and other valvular abnormalities) should be evaluated by echocardiography. At this patient's advanced age, the etiology of the aortic stenosis is most certainly degenerative calcific disease, but rheumatic and bicuspid aortic valves can also produce symptomatic aortic stenosis. ■

Practice Case 74

A 63-year-old man with a known bicuspid aortic valve and a history of hypertension presents to the emergency department with severe chest and mid-back discomfort. He was unloading groceries from his car when he developed 10/10 chest discomfort that caused him to fall to the ground.

ECG 74A

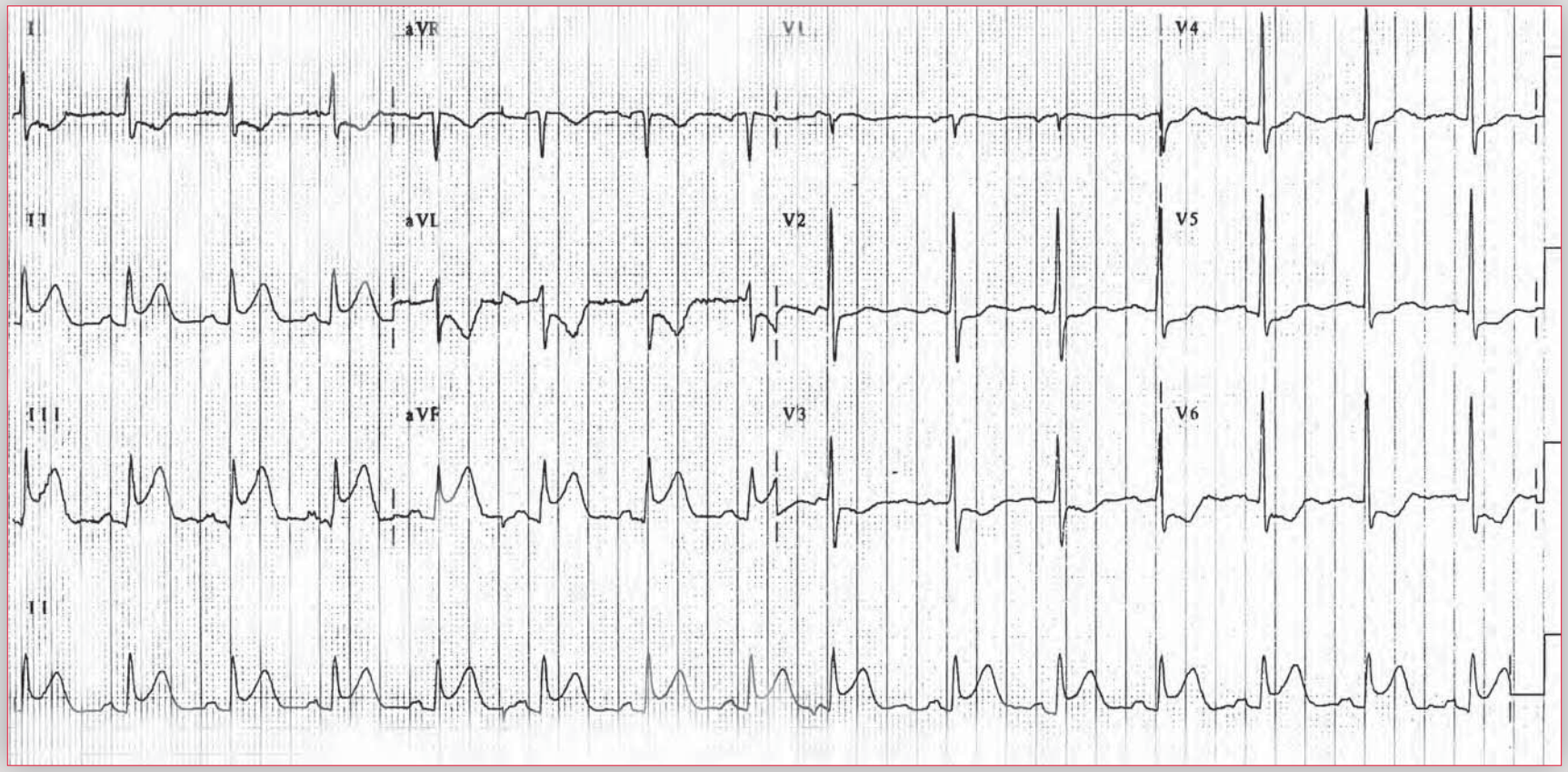

His wife called an ambulance immediately. Upon arrival to the emergency department he has a blood pressure of 70/44 mm Hg and is intermittently alert. He vomits several times. An ECG (74A) is obtained. Based on the results, a second ECG (74B) is obtained.

What do his ECGs show?

What is the likely diagnosis?

ECG 74B

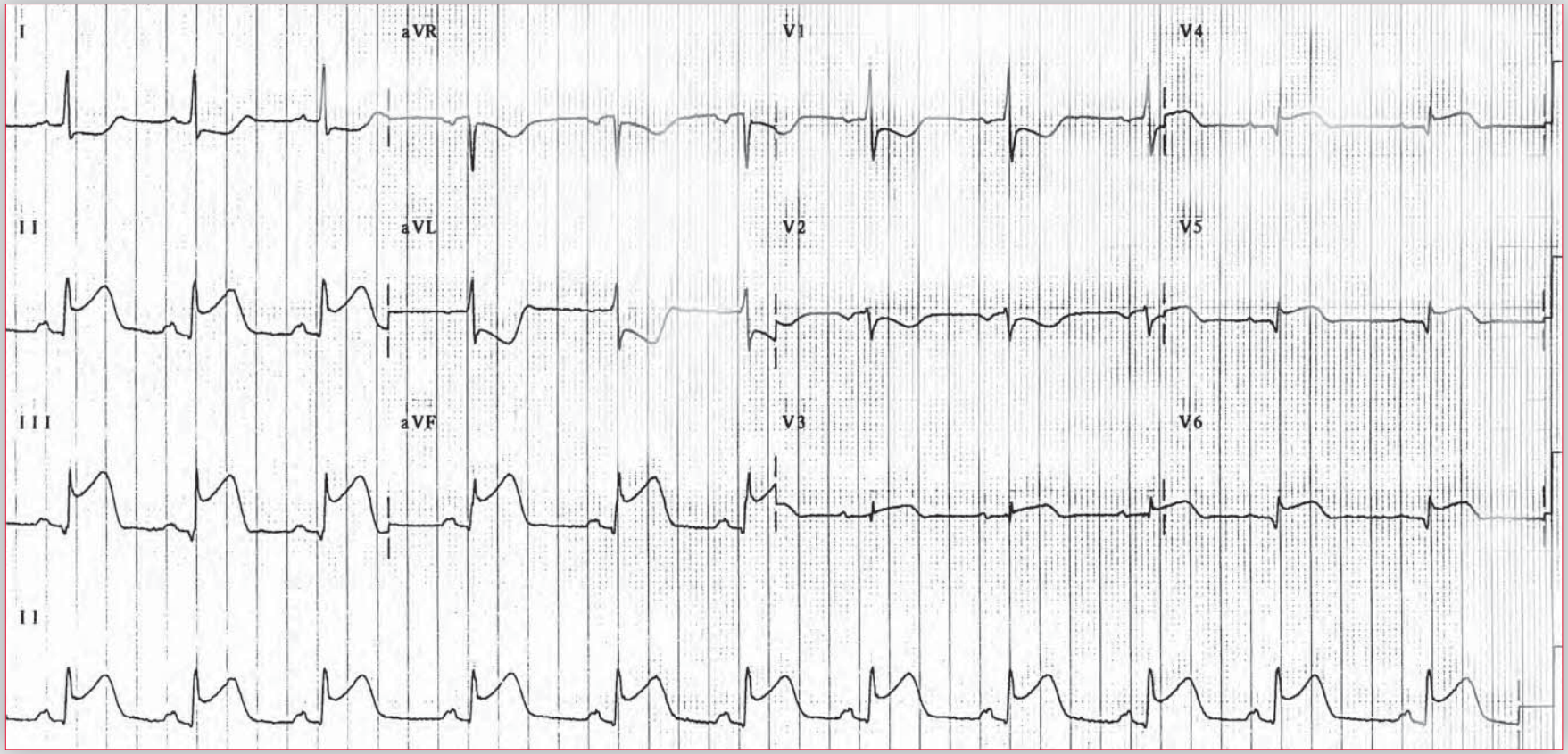

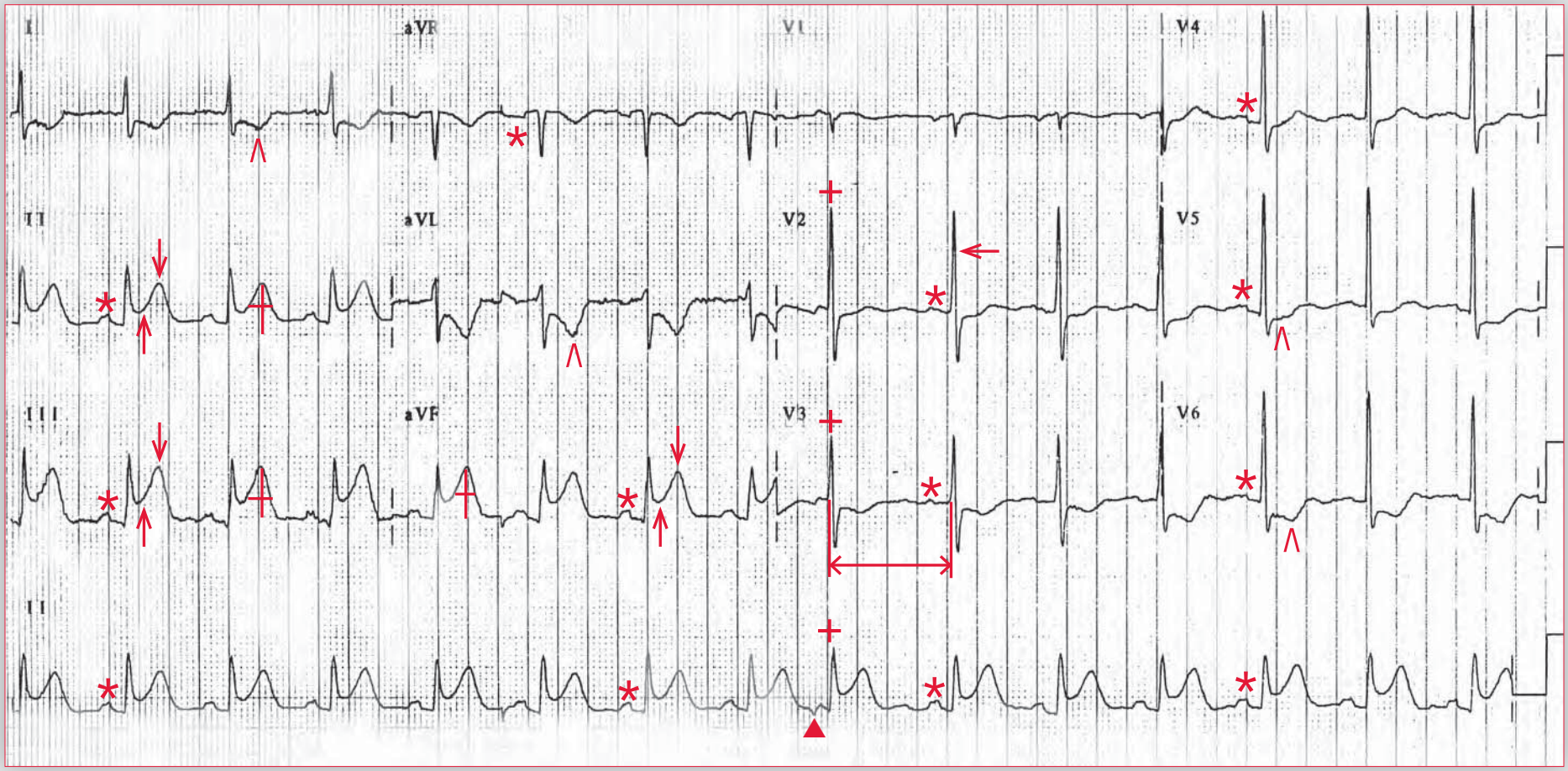

ECG 74A Analysis: Normal sinus rhythm, premature atrial complex, counterclockwise rotation (early transition), acute inferior wall ST-segment elevation myocardial infarction (STEMI), prolonged QT interval

ECG 74A shows a regular rhythm at a rate of 88 bpm. There is a P wave (*) before each QRS complex, and the P wave is positive in leads I, II, aVF, and V4-V6 and negative in lead aVR. The P-wave morphology is normal. The PR interval is constant (0.18 sec). This is a normal sinus rhythm. However, the ninth QRS complex (+) is early and is preceded by a P wave (▲) that has a different morphology than the other P waves. It is followed by a longer RR interval (↔). This is a premature atrial complex.

The QRS complex duration is normal (0.08 sec), and there is a normal morphology except for early transition, with a tall R wave (←) in lead V2. This is termed counterclockwise rotation, determined by imagining the heart as viewed from under the diaphragm. When there is counterclockwise electrical rotation, left ventricular forces are seen earlier in the precordial or chest leads, accounting for early transition with a tall R wave in lead V2. The axis is normal, between 0° and +90° (positive QRS complex in leads I and aVF). The QT/QTc intervals are slightly prolonged (400/480 msec).

The T waves (↓) in leads II, III, and aVF are symmetric, and there is ST-segment elevation (↑) in these leads. The ST segments still have a concave morphology. This is an acute inferior wall ST-segment elevation myocardial infarction (STEMI). There is reciprocal ST-segment depression (^) in leads I, aVL, and V5-V6. The tall R wave in lead V2 could reflect posterior involvement of the myocardial infarction; however, this is less likely since lead V1 does not have a tall R wave.

Although there is ECG evidence of an acute inferior wall MI, the history of sudden-onset chest and mid-back discomfort is not common for a primary MI but is more typical of an aortic dissection, which should be considered. Of note, the presence of a bicuspid aortic valve puts a patient at increased risk for aortic dissection due to an association with aortic root and ascending aortic aneurysms. Another risk factor is the history of hypertension. Occasionally, a dissection flap will extend into the ostium of the right coronary artery and occlude flow, resulting in an acute inferior MI. An urgent transthoracic echocardiogram would be useful to evaluate the proximal aortic root for the presence of a dissection. Other useful imaging modalities include urgent computed tomography or transesophageal echocardiography. An aortic dissection involving the ascending aorta is a type A dissection, and the treatment involves prompt surgical repair.

continues

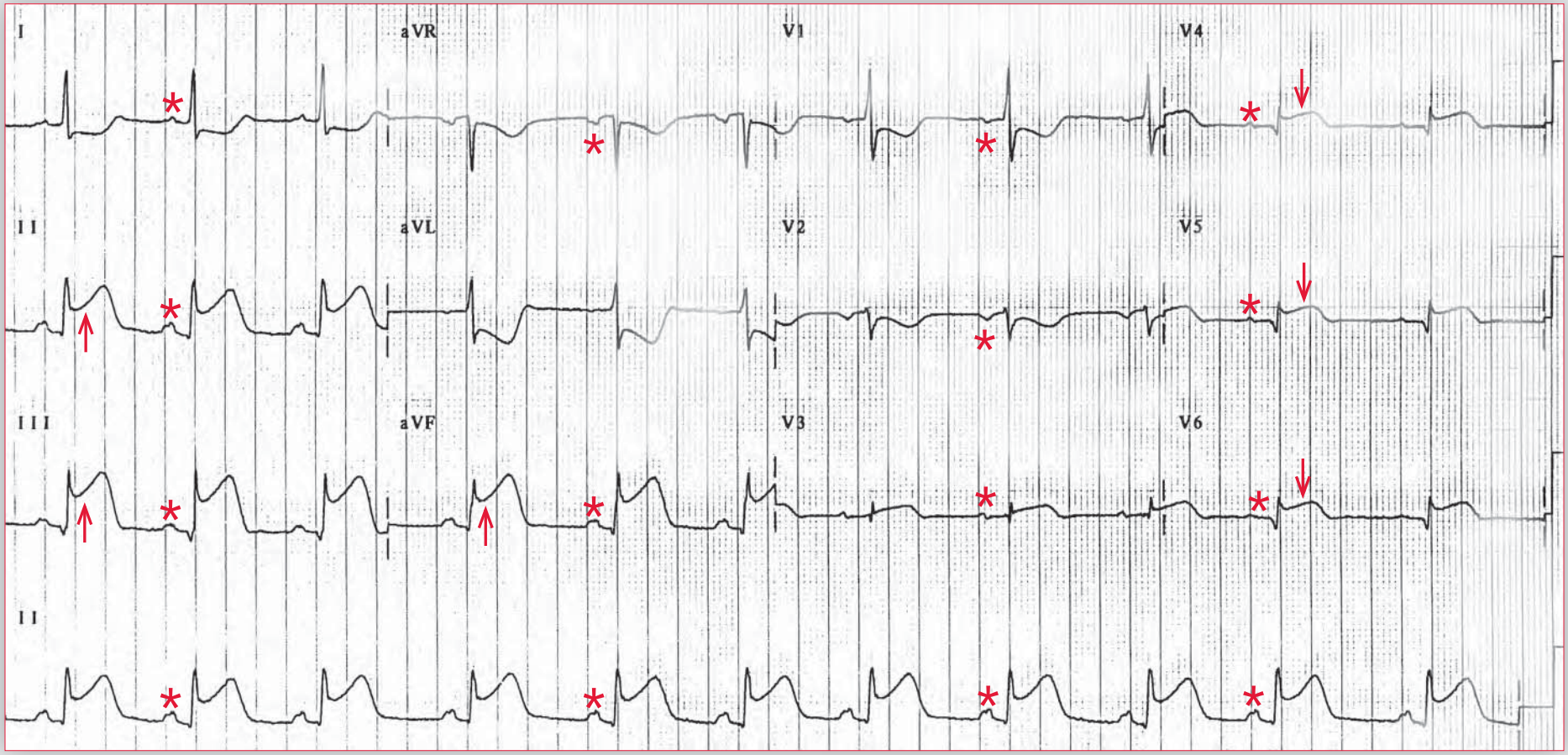

ECG 74B Analysis: Right-sided leads, right ventricular infarction

In **ECG 74B**, the P waves (*), PR interval, QRS complexes, QT/QTc intervals, and ST-segment elevation (↑) in the limb leads are identical to those seen in **ECG 74A**. However, the precordial or chest leads are different and there is loss of R-wave amplitude in leads V4-V6. These are right-sided leads, which means the ECG was recorded with the precordial leads placed on the right side of the chest. Right-sided leads are commonly obtained when an inferior wall infarction is present to evaluate for an associated right ventricular infarction. ST-segment elevation (↓) is noted in leads V4R-V6R. This represents acute infarction of the free wall of the right ventricle (*ie*, a right ventricular infarction). Right ventricular infarction may be present when the right coronary artery is occluded proximally. Diagnosing the presence of a right ventricular infarction is of clinical importance as patients are preload dependent, requiring an adequate volume to maintain normal right ventricular stroke volume to adequately fill the left ventricle. When right ventricular preload is reduced, as with nitrates or diuretics, there is a reduction in right ventricular stroke volume and left ventricular filling and hence a reduction in stroke volume. This causes a drop in blood pressure, as was seen in this patient, and raises concern for cardiogenic shock. Treatment in this situation involves giving an increased amount of fluids. ■

Notes

Practice Case 75

A 48-year-old man is evaluated for episodic headaches, sweating, and palpitations. Physical exam shows a prominent S4 and a sustained apical impulse. Blood pressure is 188/92 mm Hg supine and 155/80 mm Hg standing. Screening fractionated plasma free metanephrines are elevated.

What does his ECG show?

What is the likely diagnosis?

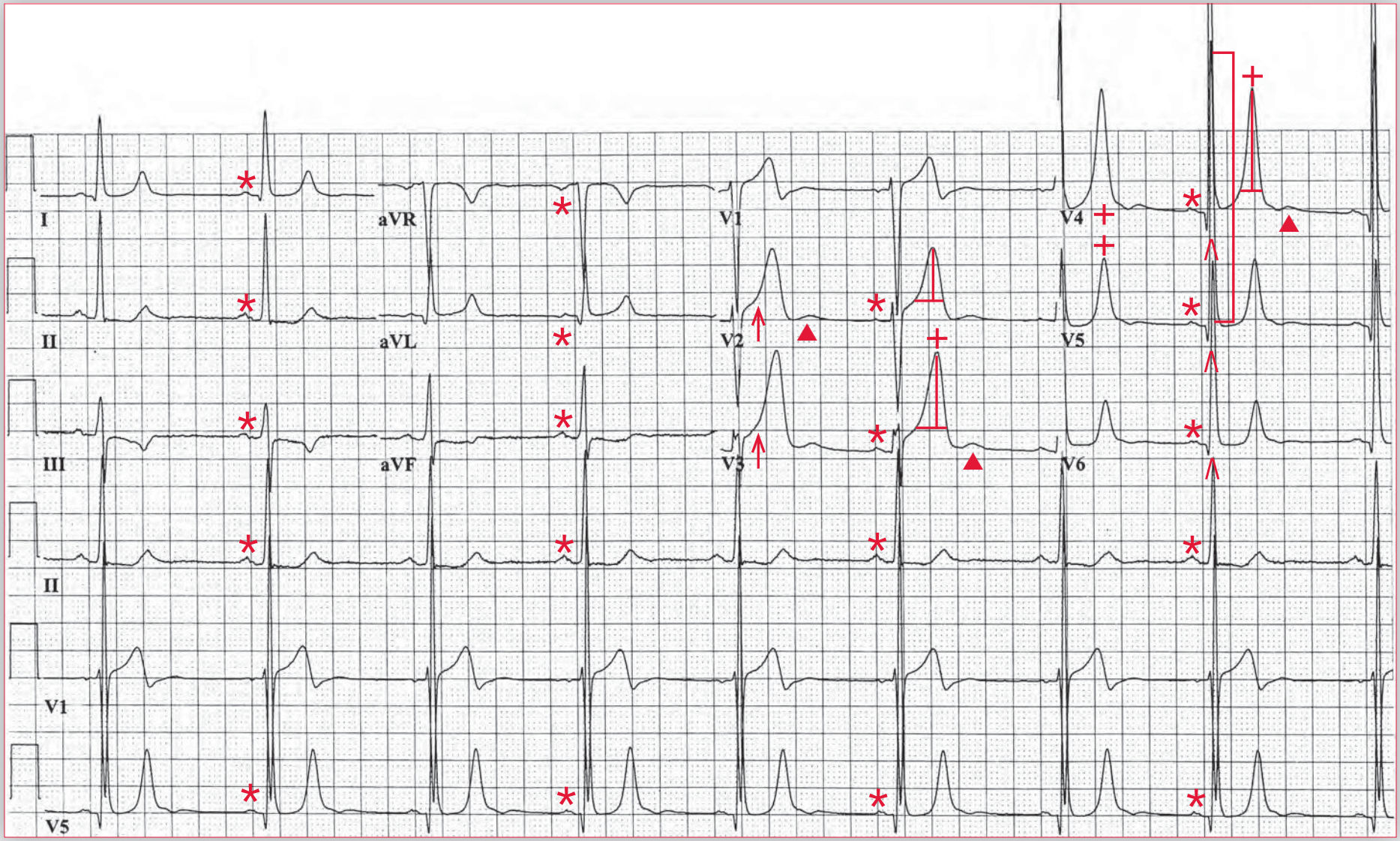

ECG 75 Analysis: Sinus bradycardia, left ventricular hypertrophy (LVH), U waves, early repolarization

There is a regular rhythm at a rate of 50 bpm. There is a P wave (*) before each QRS complex, with a stable PR interval (0.18 sec). The P wave is upright in leads I, II, aVF, and V4-V6 and negative in lead aVR. This is a sinus bradycardia.

The QRS complex duration is at the upper limit of normal (0.10 sec), and the axis is normal, between 0° and +90° (positive QRS complex in leads I and aVF). The QT/QTc intervals are normal (440/400 msec). The R-wave amplitude (voltage) is significantly increased, *ie*, 50 mm in lead V5 ( ]), which meets one of the criteria for left ventricular hypertrophy (LVH) (S-wave depth or R-wave amplitude in any precordial lead ≥ 25mm). The T waves are tall and peaked-looking in leads V3-V4 (+). However, the T-wave morphology is normal (*ie*, the T waves are asymmetric). The T waves are tall and more prominent as a result of LVH. Also noted is slight ST-segment elevation in leads V2-V3 (↑), which is early repolarization and is also commonly seen with LVH since with the increased voltage all components of the ventricular waveform are augmented. There are small Q waves in leads V4-V6 (^) that are due to septal depolarization (septal Q wave). Although the Q waves are prominent, they are in proportion to the amplitude of the R wave. Lastly, there are prominent U waves seen after the T waves in leads V2-V4 (▲). They are likely prominent because of LVH, which may make some of the ECG waveforms more prominent, including J-point elevation, T-wave amplitude, and U waves.

Given the clinical history and laboratory findings, this patient may have hypertension (and resultant LVH) attributable to a pheochromocytoma. Pheochromocytoma is a rare catecholamine-secreting tumor arising from the adrenal medulla. This patient demonstrates the classic triad of episodic headache, sweating, and tachycardia. Although these symptoms are typical, they are not unique to pheochromocytoma and can be seen in other cases of severe hypertension. This patient also demonstrates an orthostatic drop in blood pressure, which likely arises from intravascular volume depletion. If a pheochromocytoma is diagnosed, the patient should be treated with α-adrenergic receptor blocking agents and intravascular volume expansion before undergoing surgical resection of the tumor. ■

Practice Case 76

A 50-year-old man presents for a routine physical exam by a new provider at a primary care clinic. The physician notes a marked difference between the ECG in his chart from 1 year earlier (ECG 76A) and the one obtained in the clinic today (ECG 76B).

ECG 76A

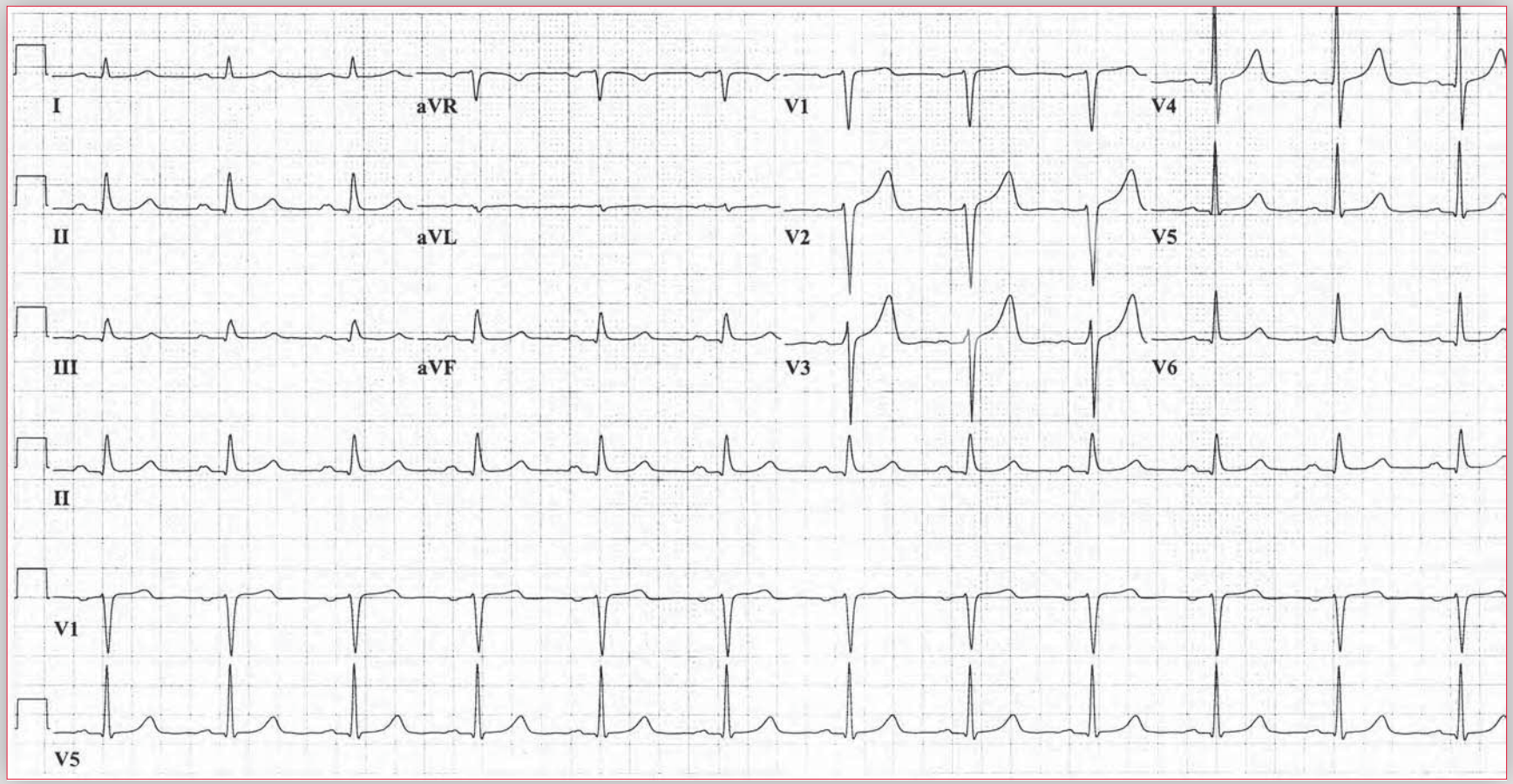

What do his ECGs show?
What accounts for this difference?

ECG 76B

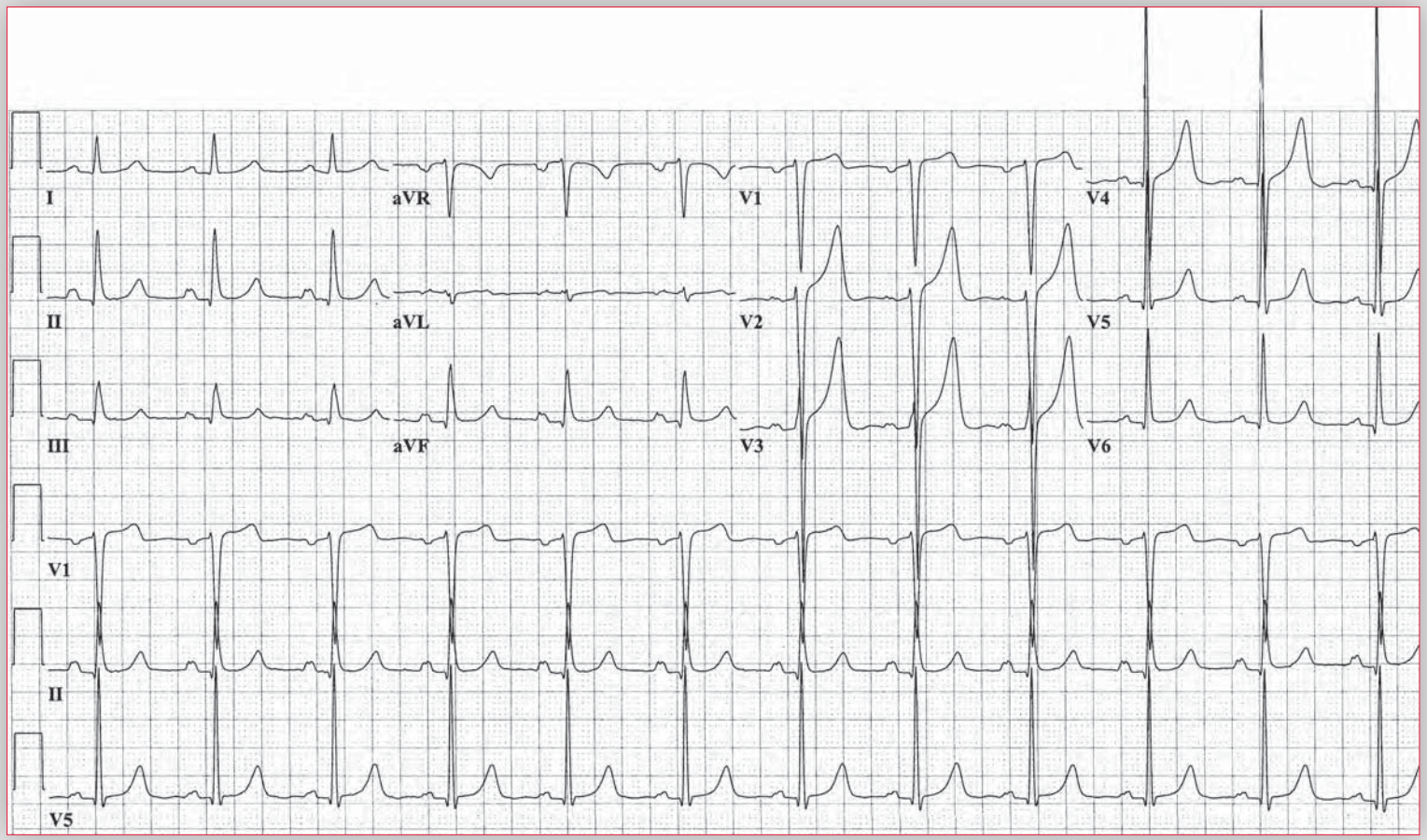

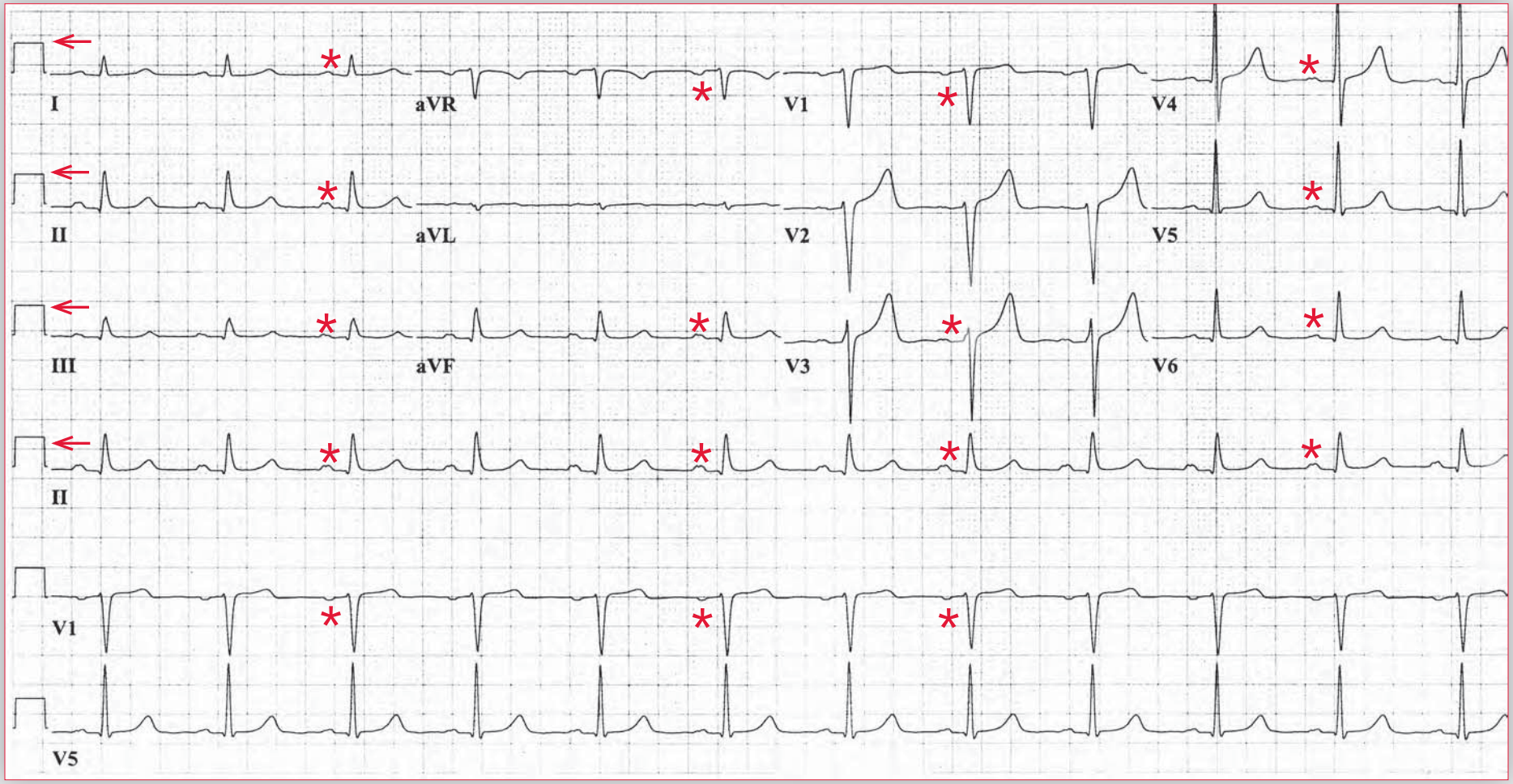

ECG 76A Analysis: Normal sinus rhythm, ECG recorded at half-standard, left ventricular hypertrophy, left atrial hypertrophy or abnormality

ECG 76A shows a regular rhythm at a rate of 70 bpm. There is a P wave (*) before each QRS complex, with a stable PR interval (0.18 sec). The P waves are upright in leads I, II, aVF, and V4-V6. This is a normal sinus rhythm. The P waves are notched in leads II and aVF and are primarily negative in lead V1; this is characteristic of left atrial hypertrophy or abnormality.

The QRS complex duration (0.10 sec), morphology, and amplitude are normal. The axis is normal, between 0° and +90° (positive QRS complex in leads I and aVF). The QT/QTc intervals are normal (340/370 msec). This is a normal ECG. However, it should be noted that the ECG was recorded at half-standard (←), in which 1 mV equals 5 mm (five small boxes), rather than the normal standard, in which 1 mV equals 10 mm (10 small boxes). Hence the amplitude (voltage) of the QRS complex (R-wave amplitude in lead V4 = 17 mm and S-wave depth in lead V3 = 13 mm) is actually twice the actual measurement. Thus the R-wave amplitude (voltage) in lead V4 is actually 34 mm and the S-wave depth in lead V3 is 26 mm (S-wave depth in lead V3 + R-wave amplitude in lead V4 = 60 mm); these values meet criteria for left ventricular hypertrophy (*ie*, S-wave depth in any precordial lead + R-wave amplitude in any precordial lead ≥ 35 mm).

Although many ECG machines indicate whether the ECG is recorded at half-standard or double standard, it is important to look at the standardization as recorded on the ECG (at the beginning or end of the tracing) to confirm what standardization was used. Failing to do this can result in an incorrect diagnosis of hypertrophy or low voltage.

continues

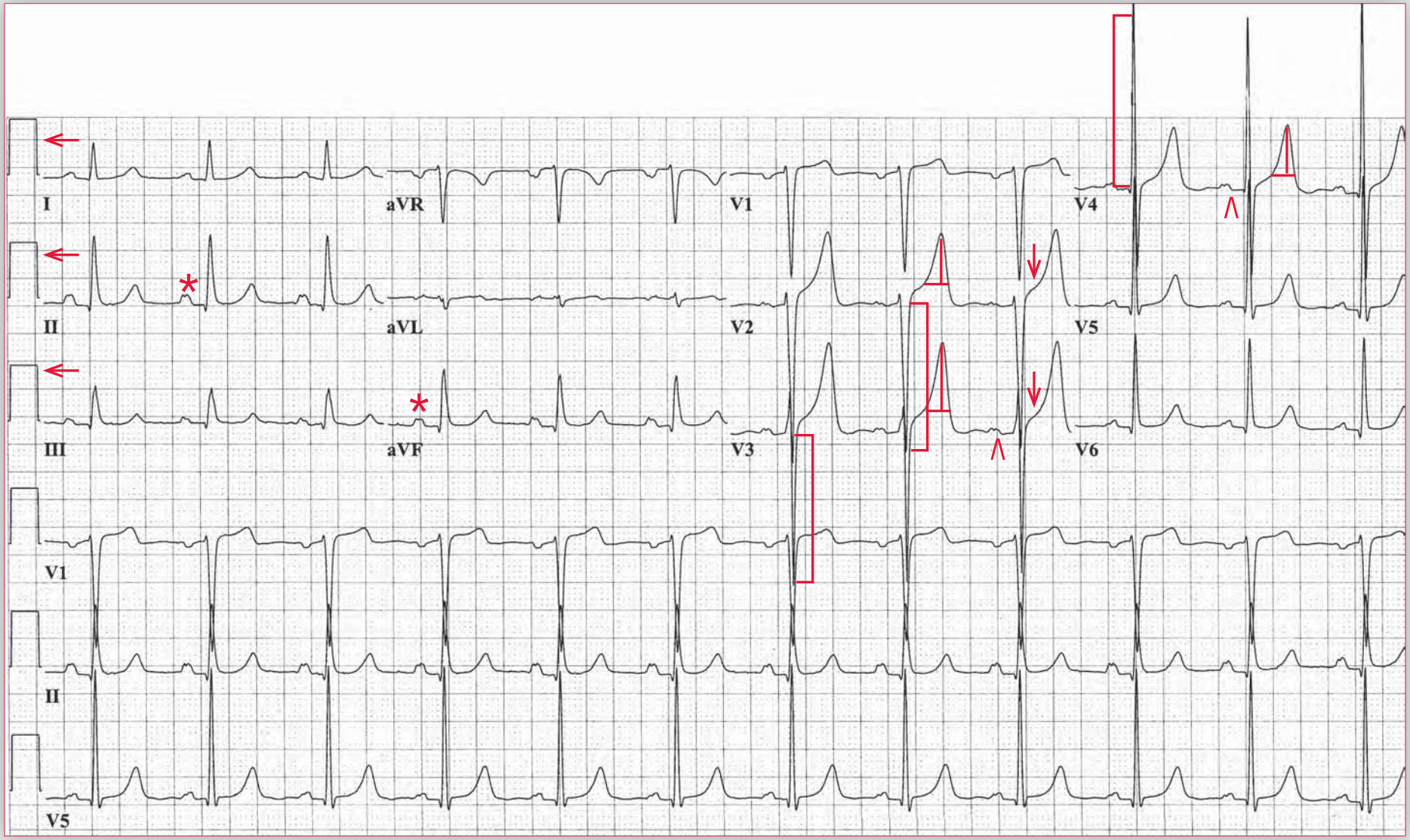

ECG 76B Analysis: ECG recorded at normal standard, left ventricular hypertrophy, left atrial hypertrophy, early repolarization

ECG 76B is recorded at normal standardization (←). The R-wave amplitude in leads V4-V5 ([ ) is in fact increased (35 mm), and the S-wave depth in leads V2-V3 ( ]) is increased (25 mm) (S-wave depth in lead V2 + R-wave amplitude in lead V5 = 60 mm). Left ventricular hypertrophy is indeed present (*ie*, S-wave depth in lead V2 + R-wave amplitude in lead V5 ≥ 35 mm). While the T waves are tall and prominent, they are asymmetric and prominent as a result of left ventricular hypertrophy. There is also evidence of early repolarization (↓) in leads V2-V3. In addition, the P waves (*) in leads II and aVF are notched and they are notched in leads V3-V4 (^), suggesting the presence of left atrial hypertrophy. ■

Notes

Practice Case 77

You are asked to review an ECG obtained in a 55-year-old woman who was evaluated at a medical walk-in unit. The patient has known longstanding hypertension. The treating physician asks you to comment on the ECG, which he thinks is abnormal.

What does the ECG show?

What is the likely explanation?

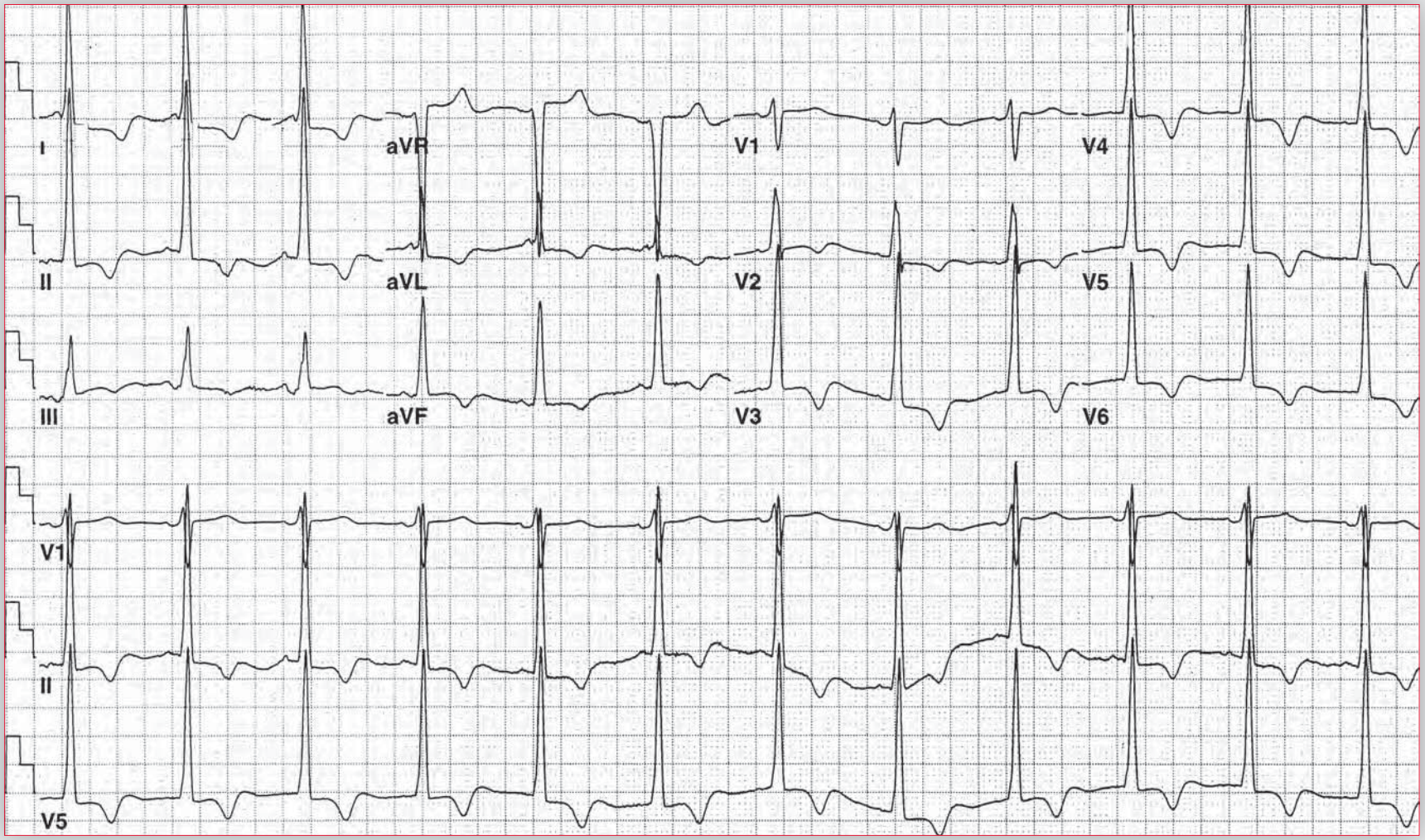

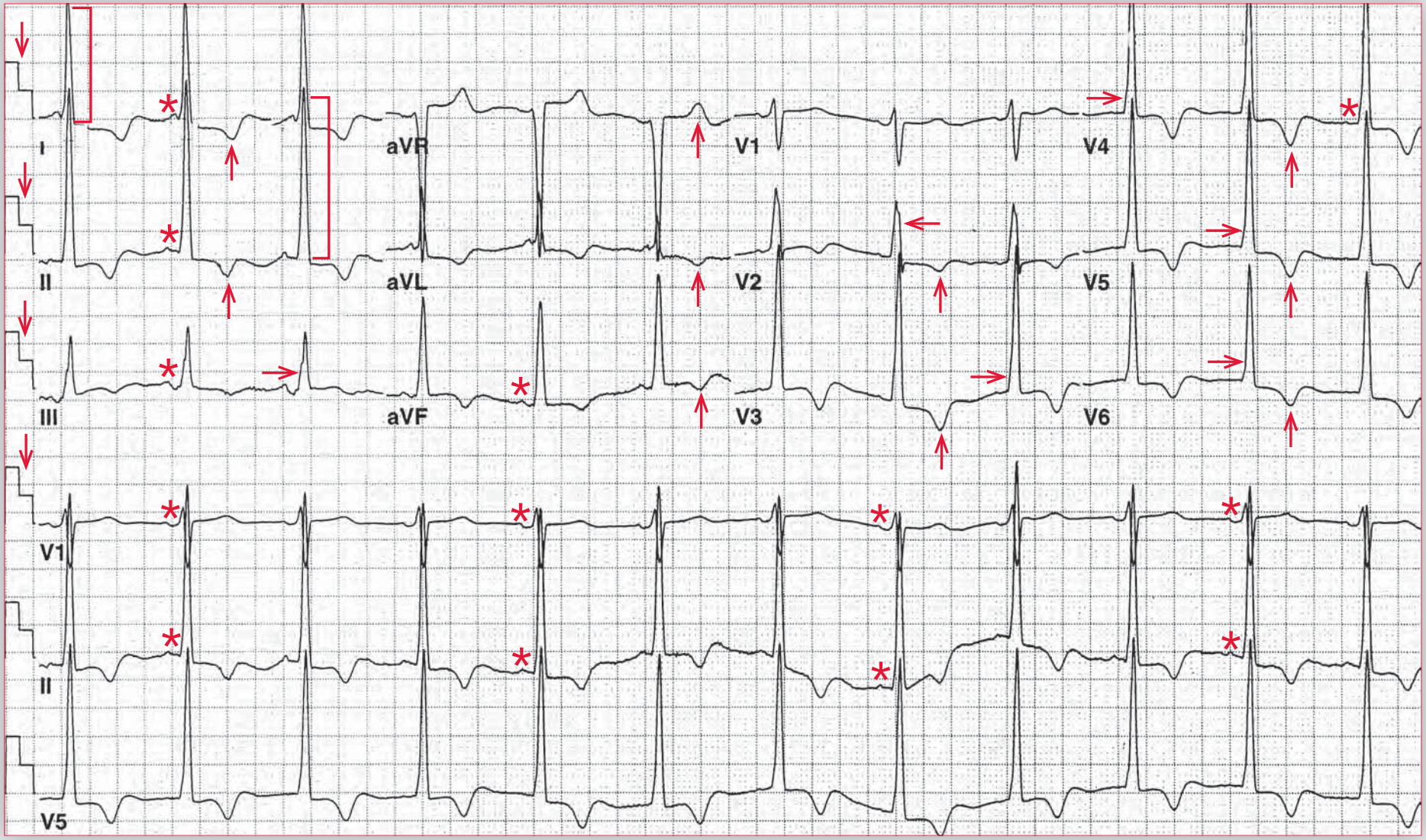

ECG 77 Analysis: Normal sinus rhythm, intraventricular conduction delay, counterclockwise rotation, left ventricular hypertrophy, ECG recorded at half-standard, ST-T wave changes

There is a regular rhythm at a rate of 70 bpm. There is a P wave (*) before each QRS complex, with a stable PR interval (0.14 sec). The P waves are upright in leads I, II, aVF, and V4; they are not obvious in leads V5-V6. The P-wave morphology is normal. This is most likely a normal sinus rhythm.

The QRS complex duration is prolonged (0.12 sec), but the morphology is normal; hence this is an intraventricular conduction delay. In addition, there is a slight slowing in the upstroke of the R wave, which is termed a delayed intrinsicoid deflection (→). The R-wave upstroke is measured from the beginning of the QRS complex to the peak of the R wave, and when the duration is longer than 0.05 second the intrinsicoid deflection is delayed. The axis is normal, between 0° and +90° (positive QRS complex in leads I and aVF). The QT/QTc intervals are normal (400/430 msec and 360/390 msec when corrected for the prolonged QRS complex duration). Also noted is a tall R wave in lead V2 (←), which is termed early transition or counterclockwise rotation and is related to the electrical axis in the horizontal plane as determined by imagining the heart as viewed from under the diaphragm. When there is counterclockwise electrical rotation, left ventricular forces develop early and are seen in the right precordial leads; this causes the tall R wave in lead V2, or early transition.

The amplitude of the QRS complex is increased in leads I and II (30 mm) ( ]), which meets criteria for left ventricular hypertrophy (*ie*, R-wave amplitude in any limb lead ≥ 20 mm). However, the measured amplitude of the R waves in the precordial or chest leads is not increased. However, the standardization (↓) noted at the beginning of the ECG tracing indicates that the limb leads were recorded at normal standard (1 mV = 10 mm or 10 small boxes) while the precordial or chest leads were recorded at half-standard (1 mV = 5 mm or five small boxes). Hence the measured R-wave amplitude in the precordial leads must be doubled to obtain their actual height. Therefore, the actual R-wave amplitude (voltage) in lead V5 is 50 mm, which meets one of the criteria for left ventricular hypertrophy (S-wave depth or R-wave amplitude in any one precordial lead ≥ 25 mm). Also noted are diffuse ST-T wave abnormalities (↑) in each lead. These are repolarization abnormalities that reflect chronic subendocardial ischemia resulting from reduced perfusion and oxygen supply to the endocardial layer of the hypertrophied myocardium. LVH would also be present based on the Romhilt-Estes criteria (*ie*, 7 points). ■

Notes

Practice Case 78

A 56-year-old woman is awakened from sleep with severe, crushing retrosternal chest discomfort. The discomfort is unrelenting, and after 5 minutes she calls emergency medical services. The ECG obtained on arrival is shown. She is given aspirin and sublingual nitroglycerin, and her discomfort and ECG changes resolve almost immediately.

What does her initial ECG show?

What is the likely diagnosis?

What are the likely findings on coronary angiography?

How should this condition be treated?

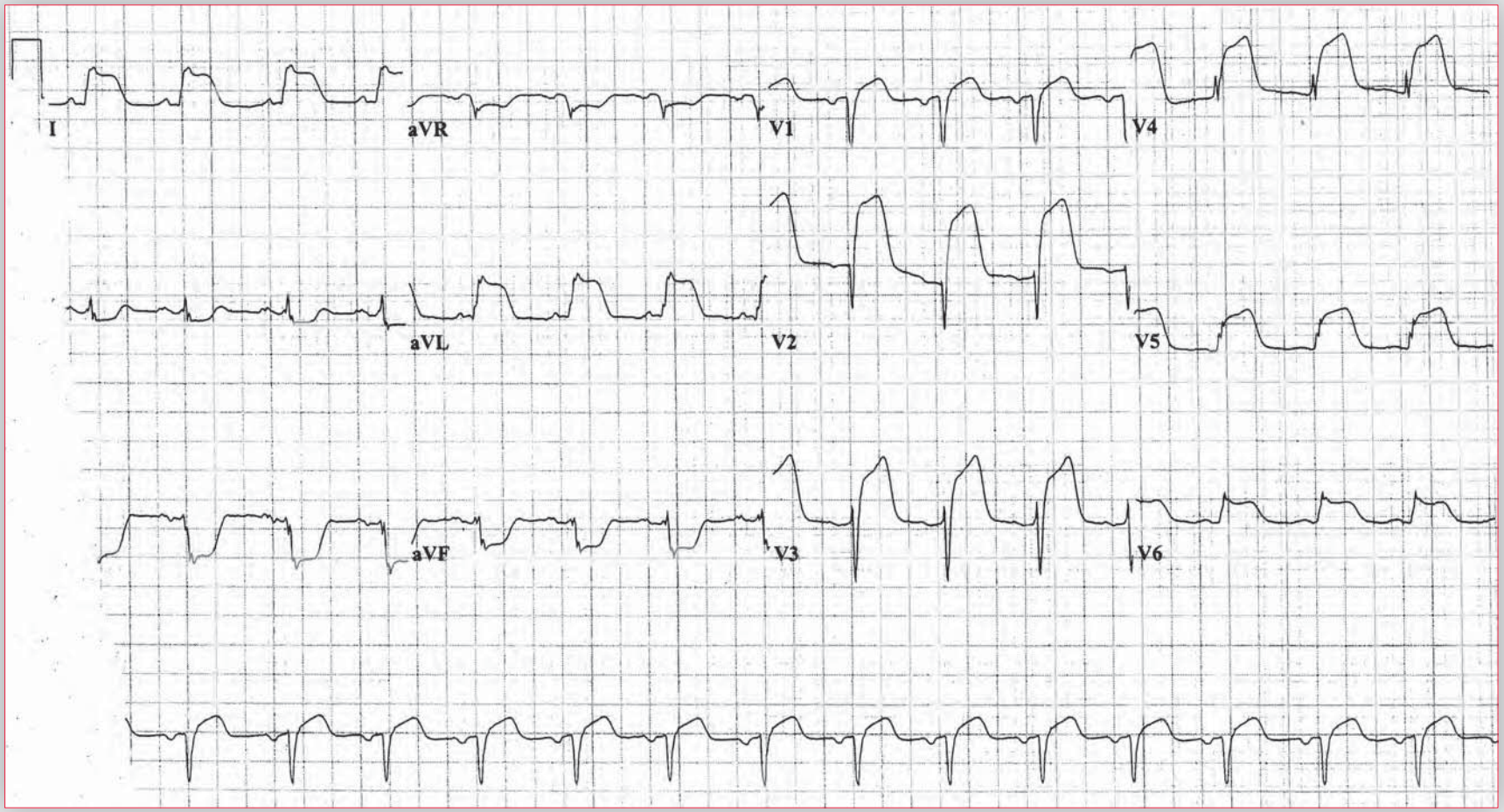

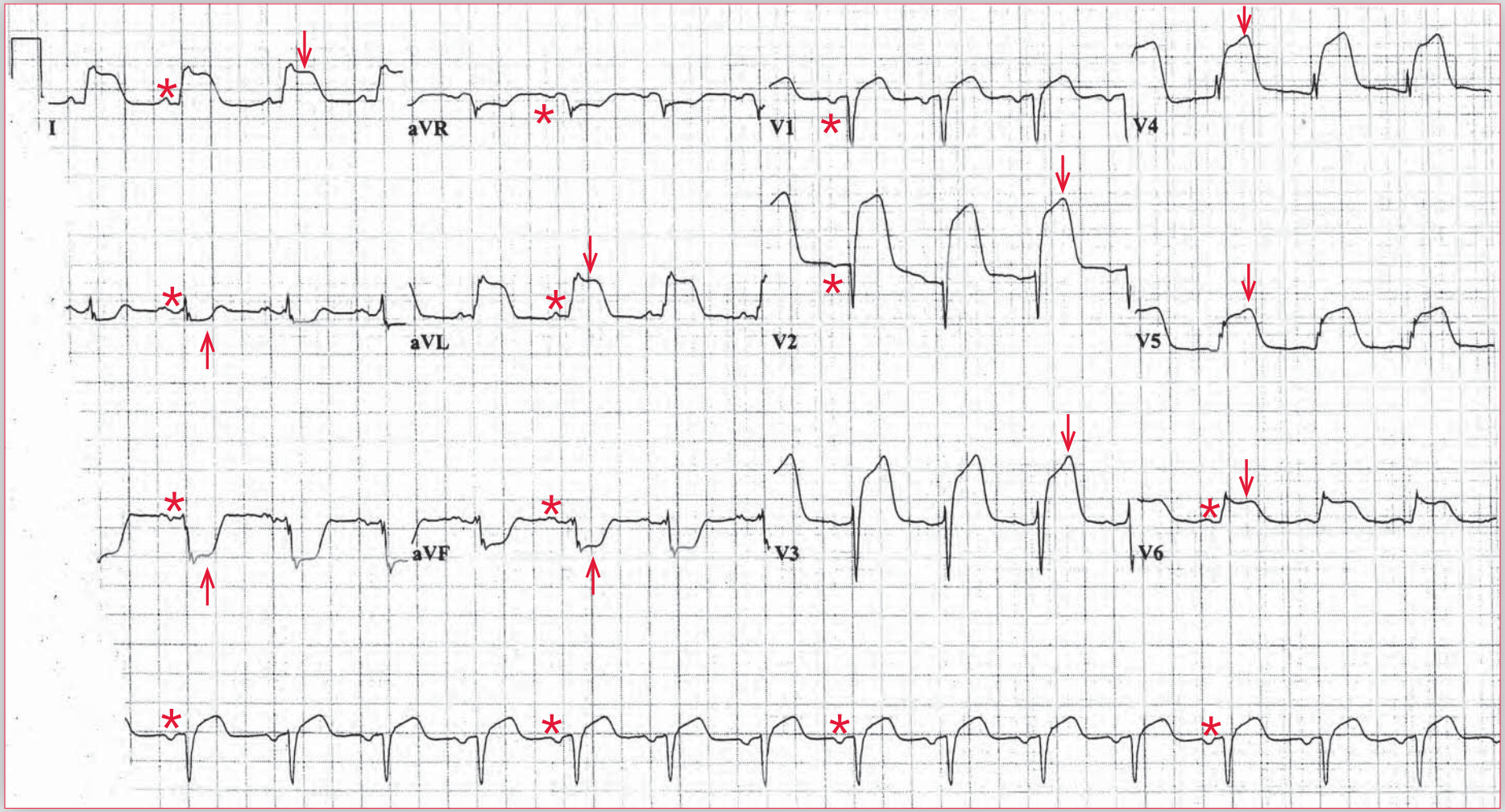

ECG 78 Analysis: Normal sinus rhythm, acute anterior wall ST-segment elevation myocardial infarction (STEMI) or transmural ischemia, acute lateral wall STEMI or transmural ischemia, left atrial hypertrophy

There is a regular rhythm at a rate of 90 bpm. There is a P wave (*) before each QRS complex, with a stable PR interval (0.16 sec). The P wave is upright in leads I, II, aVF, and V4-V6. The P wave is negative in leads V1-V2, suggesting left atrial hypertrophy. This is a normal sinus rhythm.

The QRS complex duration is normal (0.08 sec). It is difficult to establish the QRS morphology and axis because of the significant ST-segment elevations (↓) in leads I, aVL, and V2-V6. This is an extensive acute anterior wall ST-segment elevation myocardial infarction (STEMI) involving the apex and anterolateral and lateral walls. The ST-segment morphology is convex, and it merges with the T wave. There is loss of R-wave amplitude, especially obvious in leads I, aVL, and V5-V6. The complex is said to show a current of injury, and it resembles the fast action potential that is generated by the ventricular myocardium as a result of the rapid influx of sodium ion. This is, therefore, a monophasic action potential. Also noted is significant ST-segment depression (↑) in leads II, III, and aVF; these are reciprocal changes.

An acute MI is identified by the presence of localized ST-segment elevation, hyperacute T waves (tall, peaked, and symmetric), and reciprocal ST-segment depressions (due to the same ST-segment elevations viewed from another angle). The location of these ST-segment elevations identifies the region of the myocardium involved.

This ECG is typical for an acute anterior STEMI, but the rapid resolution of the chest pain and ECG abnormalities is not typical. This patient most likely has variant angina (also called Prinzmetal's angina), which is believed to be caused by coronary artery vasospasm and transient transmural myocardial ischemia. Most often, these patients have minimal or no demonstrable coronary artery disease on angiography. Provocative testing with intracoronary acetylcholine or ergonovine may induce vasospasm (and the resulting ECG changes) and can be used to establish the diagnosis. These patients should be treated with vasodilators such as nitroglycerin with each episode. There is a role for calcium-channel blockers and long-acting nitrates in the long-term control of symptoms when episodes are frequent. ■

Notes

Practice Case 79

A 64-year-old man is admitted to the emergency department with chest pressure that occurred 1 hour earlier while doing yard work. Although the pain decreased initially with rest, it continues to wax and wane. He is treated with aspirin and nitroglycerin with moderate relief. His presenting ECG is shown.

What does his ECG show?

What is the likely diagnosis?

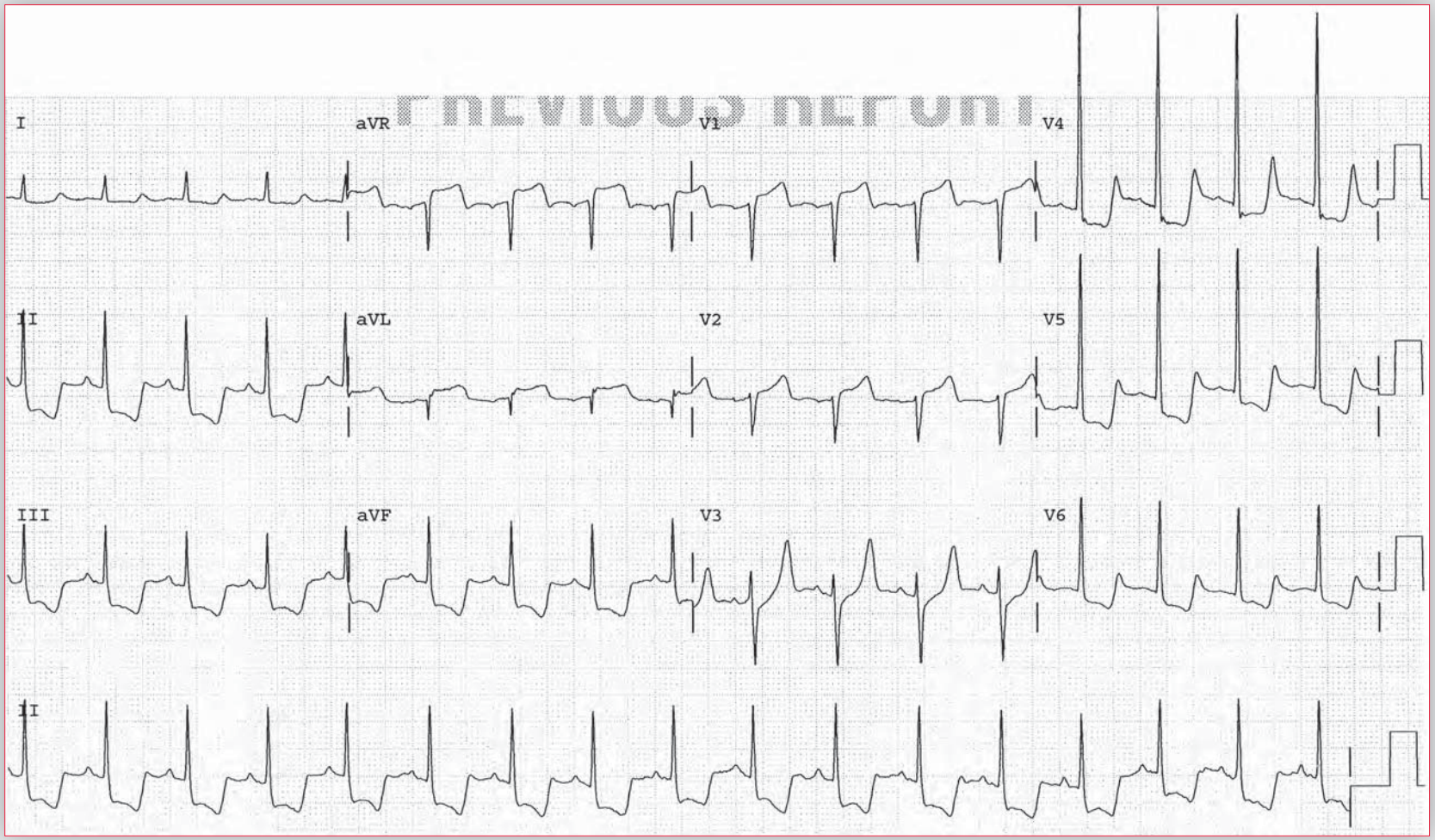

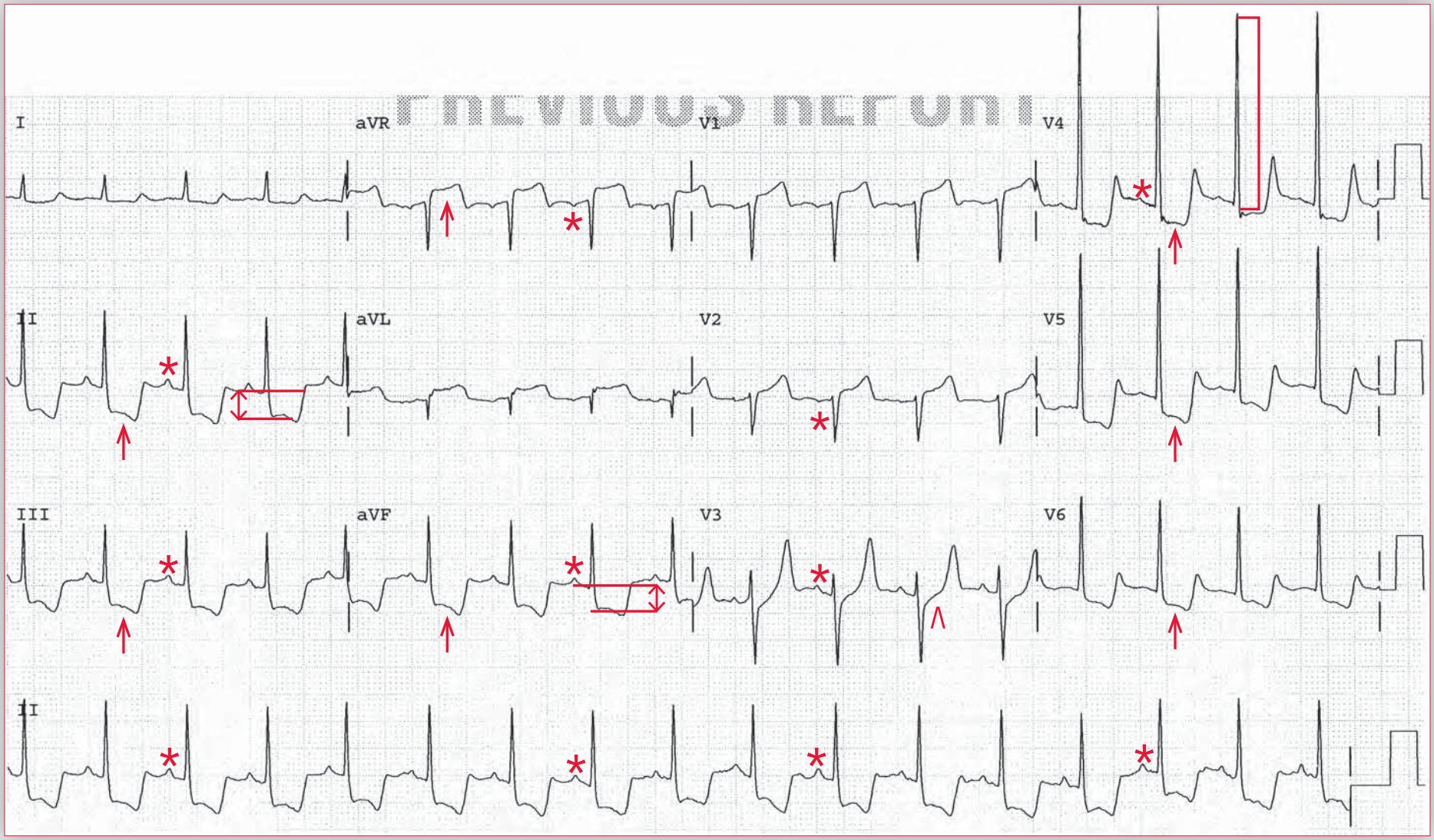

ECG 79 Analysis: Sinus tachycardia, left ventricular hypertrophy, downsloping ST-segment depression

There is a regular rhythm at a rate of 100 bpm. There is a P wave (*) before each QRS complex, with a stable PR interval (0.16 sec). The P wave is upright in leads I, II, III, and V4-V6 and negative in lead aVR. The P-wave morphology is normal. This is a sinus tachycardia.

The QRS complex duration is normal (0.08 sec), and there is a normal QRS morphology with normal R-wave progression from leads V1 to V6. The QRS axis is normal, between 0° and +90° (positive QRS complex in leads I and aVF). The QT/QTc intervals are normal (340/440 msec). The QRS amplitude (voltage) in lead V4 is 38 mm ( ]), meeting one of the criteria for left ventricular hypertrophy (S-wave depth or R-wave amplitude in any precordial lead ≥ 25 mm).

There is significant 2- to 3-mm (↕) downsloping ST-segment depression (↑) in leads II, III, aVF, and V4-V6. The ST-segment elevation in lead aVR is actually ST-segment depression. In lead V3 there are upsloping ST-segment depressions (^). The ST-segment depression indicates myocardial ischemia, which may be the result of left ventricular hypertrophy or coronary artery disease.

This patient is experiencing an acute coronary syndrome. Although similar ECG changes can be seen with hypertension and left ventricular hypertrophy, in the context of the clinical scenario this patient requires immediate therapy for an acute coronary syndrome and an unstable coronary plaque. He should be treated with antiplatelet agents, nitroglycerin, anticoagulation, a statin, and β-adrenergic blocking agents depending on blood pressure and heart rate. Biomarkers such as creatine kinase (CK and CK-MB) and troponin are useful in determining whether there has been any myocardial necrosis. If there is evidence of infarction (*ie*, non–ST-segment elevation myocardial infarction or NSTEMI), patients most often undergo early invasive coronary intervention to restore adequate blood flow. If cardiac biomarkers are negative (*ie*, unstable angina) and the patient responds to medical therapy with resolution of the ST-segment changes, medical therapy can be continued with assessment of anginal control using exercise testing. ■

Notes

Practice Case 80

A 66-year-old woman presents with 2 hours of intermittent retrosternal chest pain. She was working in her garden when she became faint and diaphoretic and developed substernal chest discomfort. The pain lasted about 10 minutes, abated when she rested, and recurred shortly after she began working again. Eventually, she had a family member drive her to the emergency department, where an ECG was obtained.

What does her ECG show?

What is the likely diagnosis?

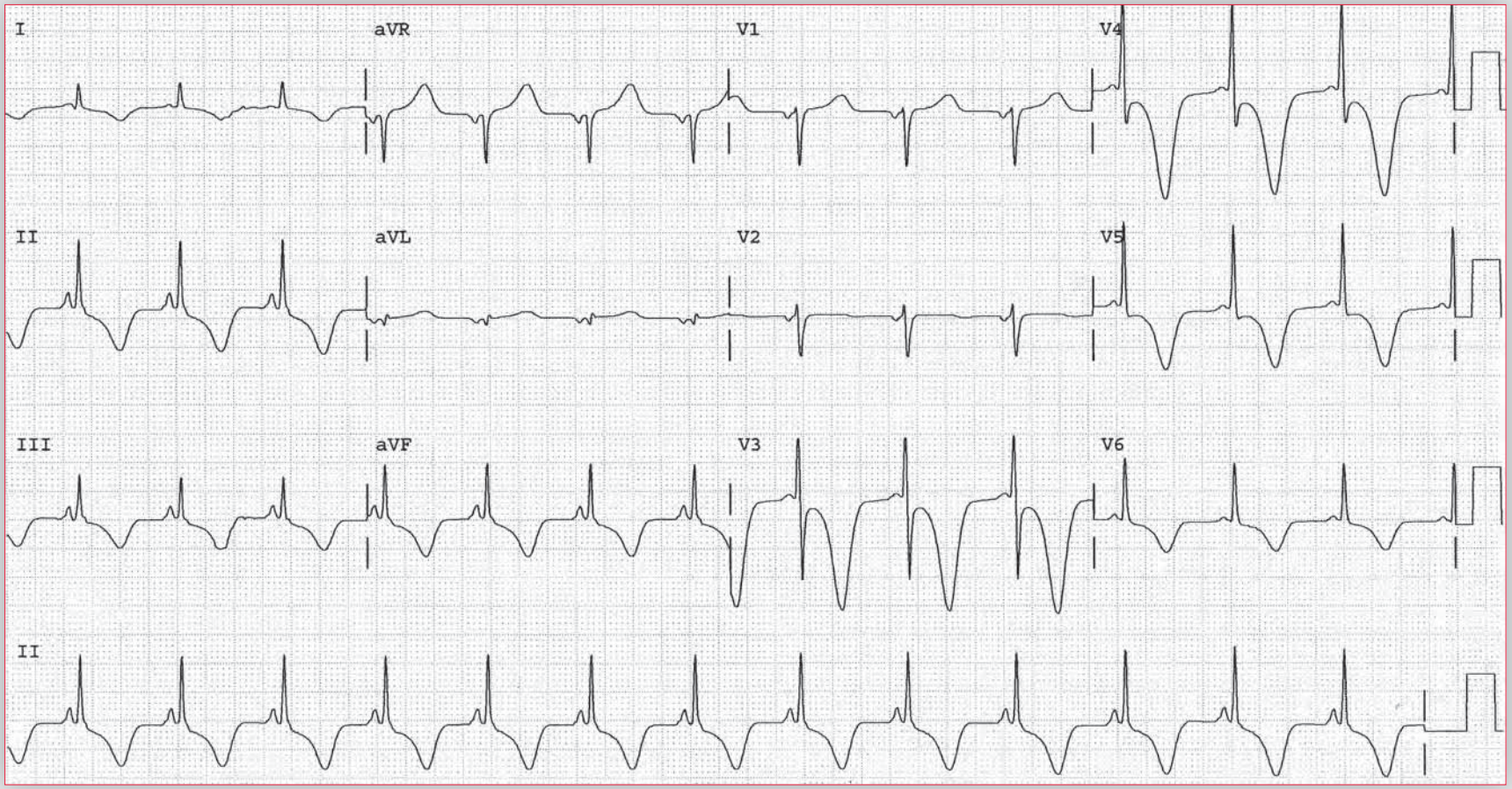

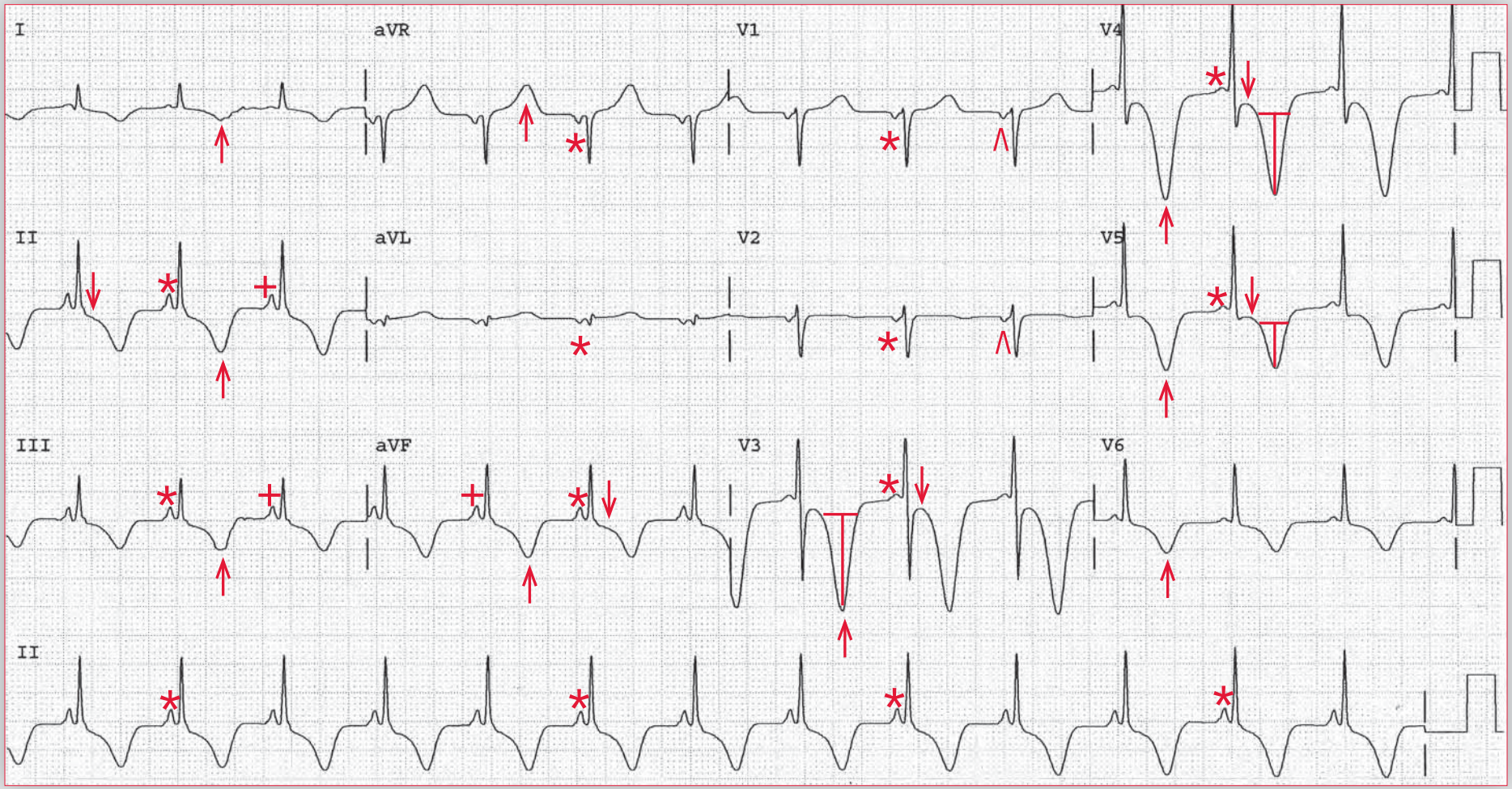

ECG 80 Analysis: Normal sinus rhythm, short PR interval (enhanced AV nodal conduction or Lown-Ganong-Levine pattern), right atrial hypertrophy (abnormality), left atrial hypertrophy (abnormality), biatrial hypertrophy, ST-segment depression (ischemia), T-wave inversions, prolonged QT interval

There is a regular rhythm at a rate of 80 bpm. There is a P wave (*) before each QRS complex, with a stable but very short PR interval (0.12 sec). The P waves are positive in leads I, II, aVF, and V4-V6 and negative in lead aVR. This is a normal sinus rhythm.

The short PR interval (with a normal QRS complex) may be the result of enhanced AV nodal conduction or a preexcitation syndrome, known as Lown-Ganong-Levine, in which there is a bypass of the AV node due to an accessory pathway (known as a bundle of James). This accessory pathway links the atrium with the bundle of His, producing a short PR interval with a normal QRS complex morphology. The P waves are narrow and peaked in leads II, III, and aVF (+) (consistent with right atrial hypertrophy or abnormality), and they are negative in leads V1-V2 (^) (consistent with left atrial hypertrophy or abnormality). Therefore, there is evidence of biatrial hypertrophy.

The QRS complex duration is normal (0.08 sec), and the morphology is normal. There is a normal axis, between 0° and +90° (positive QRS complex in leads I and aVF). The QT/QTc intervals are prolonged (460/530 msec). Deeply inverted T waves (↑) can be seen in most leads. The inverted T waves are symmetric. More importantly, there is ST-segment depression (↓) in leads II, aVF, and V3-V5. The T-wave changes, along with the ST-segment depression and QT interval prolongation, is strongly suggestive of ischemia.

Although this patient does not have the typical ST-segment elevations associated with myocardial infarction or the isolated downsloping ST-segment depression of myocardial ischemia, her ECG (*ie,* symmetrically inverted T waves) and the clinical history are consistent with myocardial ischemia. The diagnosis is an acute coronary syndrome, the result of an acute plaque rupture with subtotal occlusion of the vessel by active thrombus. If cardiac biomarkers are negative, consistent with a diagnosis of unstable angina, aggressive treatment of her symptoms (with anticoagulation, antiplatelet therapy, β-blocker, nitrates, and statins) would be the initial step. Depending on the patient's response to medical therapy, the next step might be either a noninvasive ischemic evaluation (if she has stabilized) or proceeding directly to coronary angiography (if she remains unstable or has refractory symptoms). If cardiac biomarkers are positive, consistent with a diagnosis of a non–ST-segment myocardial infarction, aggressive therapy as above is often followed by cardiac catheterization within 48 to 72 hours along with percutaneous coronary intervention if indicated. ■

Notes

Practice Case 81

A 36-year-old woman presents to a cardiologist for the first time as an adult. She was followed for a heart murmur as a child but was lost to follow-up during her late teens. She feels well and has no complaints. Examination is notable for a jugular venous pressure of 12 cm H_2O, a systolic murmur at the left upper sternal border, a right-sided S4, and a widely split S2.

What does her ECG show?

What is the likely diagnosis?

What treatment is indicated?

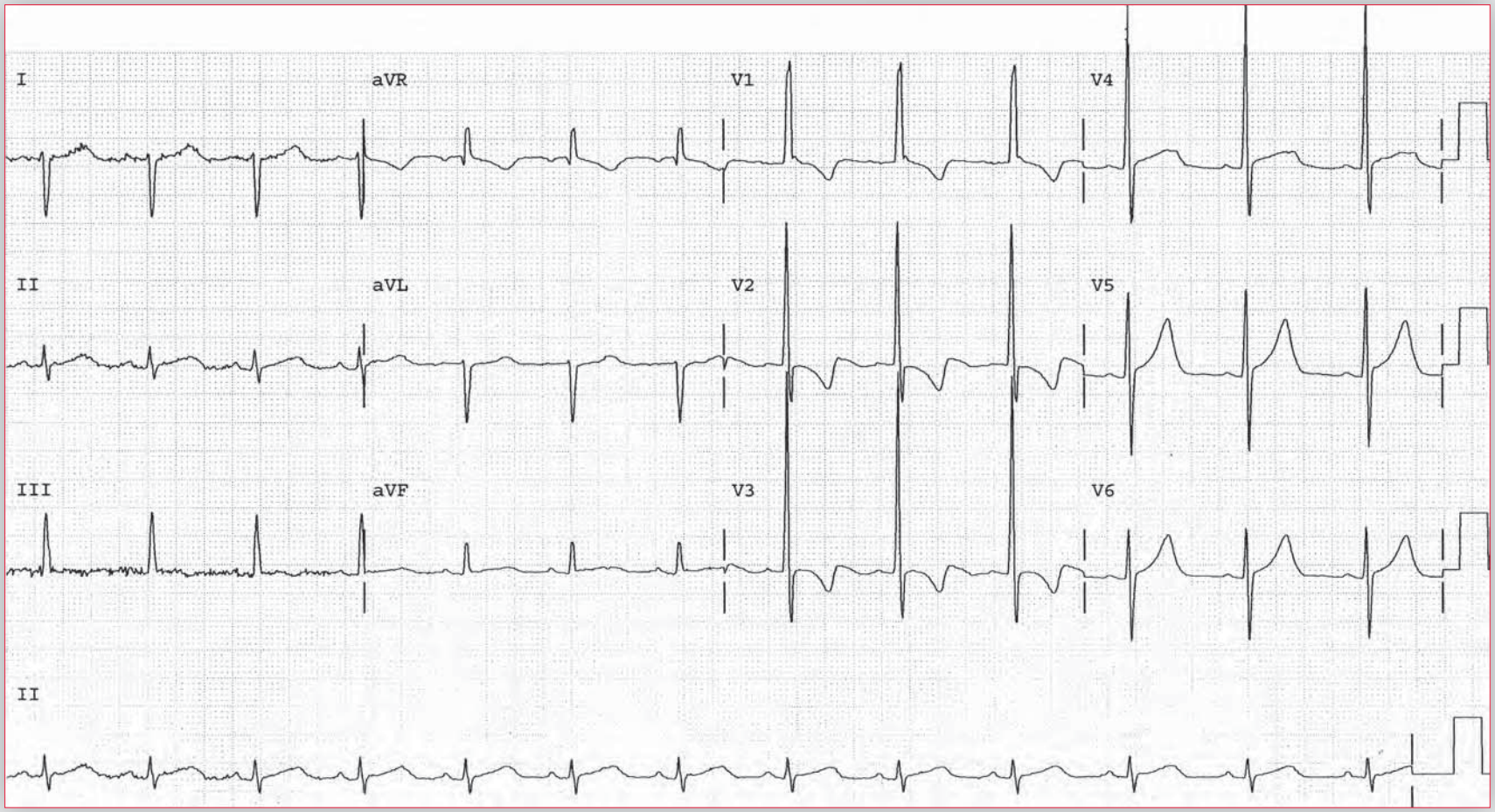

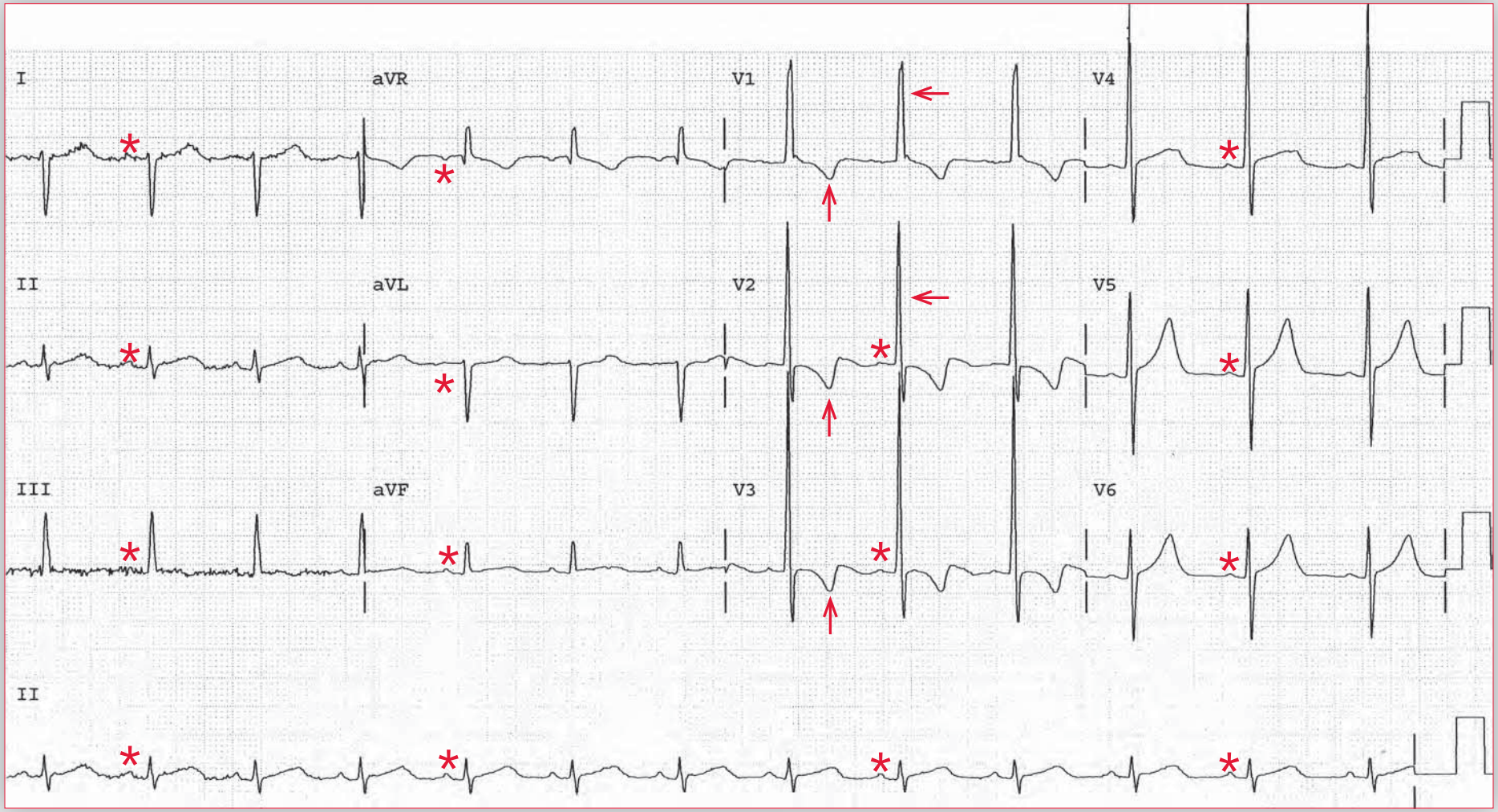

ECG 81 Analysis: Normal sinus rhythm, right ventricular hypertrophy (RVH) with associated ST-T wave abnormalities, right axis deviation

There is a regular rhythm at a rate of 78 bpm. There is a P wave (*) before each QRS complex, and the PR interval is stable (0.16 sec). The P wave is positive in leads I, II, aVF, and V4-V6 and negative in lead aVR. This is a normal sinus rhythm. The P-wave morphology is normal.

The QRS complex duration is normal (0.08 sec), and there is a right axis deviation, between +90° and +180° (negative QRS complex in lead I and positive QRS complex in lead aVF). There are a number of causes for a right axis deviation that should be considered. These include right ventricular hypertrophy (RVH; associated with a tall R wave in lead V1 and right atrial hypertrophy or abnormality), a lateral wall myocardial infarction (MI; a deep Q wave in leads I and aVL), right–left arm lead switch (associated with a negative P wave and T wave in leads I and aVL), dextrocardia (which resembles right–left arm lead switch and also has reverse R-wave progression across the precordium), Wolff-Parkinson-White pattern (with a prolonged QRS complex duration due to a delta wave and a short PR interval), and a left posterior fascicular block (a diagnosis of exclusion when there are no other causes for the right axis deviation). The QT/QTc intervals are normal (400/450 msec).

There is a tall R wave in leads V1 (17 mm) and V2 (←). There are a number of causes for a tall R wave in lead V1, including RVH, posterior wall MI (usually with evidence of an inferior wall MI), Wolff-Parkinson-White pattern (with a prolonged QRS complex duration due to a delta wave and short PR interval), Duchenne muscular dystrophy (with a posterolateral MI pattern), hypertrophic cardiomyopathy (also with prominent septal Q waves in other leads), dextrocardia (reverse R-wave progression, right axis deviation, negative P and T waves in leads I and aVL), V1-V3 lead switch, recording of right-sided leads (reverse R-wave progression), and counterclockwise rotation. In this case, the tall R wave in lead V1 in conjunction with the right axis deviation is characteristic of RVH. The marked amplitude of the R wave in lead V1 is suggestive of more severe RVH and is often seen with congenital heart disease. In addition, there are ST-T wave changes (↑) in leads V1-V3; these are repolarization abnormalities associated with RVH and represent chronic subendocardial ischemia resulting from a reduction in perfusion and blood supply to the endocardial layer of the hypertrophied right ventricular myocardium.

This patient has evidence of marked RVH. This degree of RVH is usually associated with congenital heart disease. In this case it is due to congenital pulmonic stenosis. People with mild pulmonic stenosis can remain asymptomatic for many years. These patients are generally believed to have a benign disease with little risk for progression. However, if the obstruction is moderate it often leads to an inability to augment pulmonary blood flow during exertion, causing exercise intolerance, fatigue, or syncope. In such cases, balloon valvotomy is recommended to reduce the degree of obstruction. Pulmonic stenosis responds well to balloon valvotomy and rarely requires surgical correction. ■

Notes

Practice Case 82

A 54-year-old man presents for follow-up 6 weeks after suffering a myocardial infarction (MI). The treatment for his heart attack was delayed because the infarction occurred when he was traveling in a rural area. Since his MI he has been free of further symptoms.

What does his ECG show?

Which region of myocardium was affected?

Involvement of which vessel likely explains this pattern?

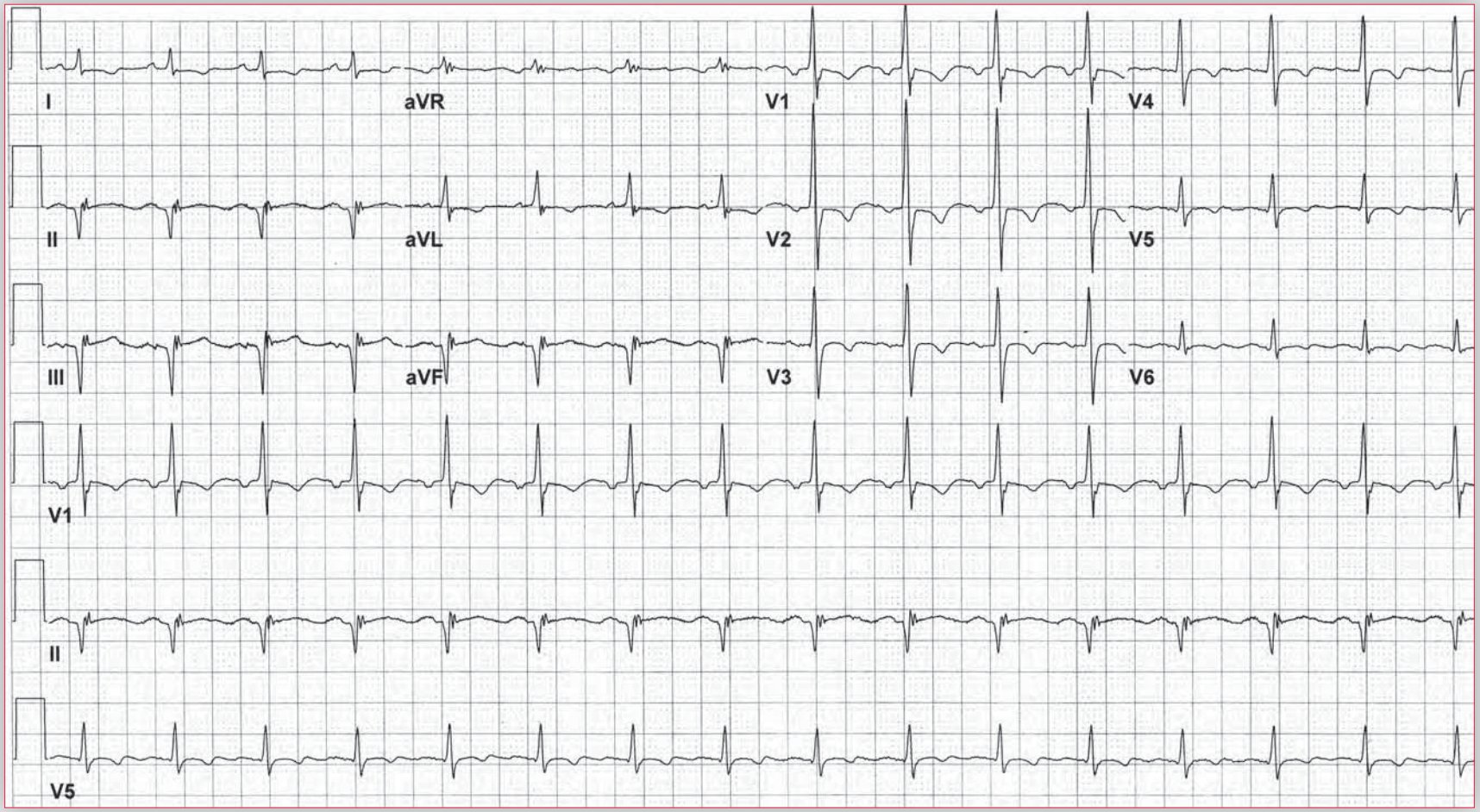

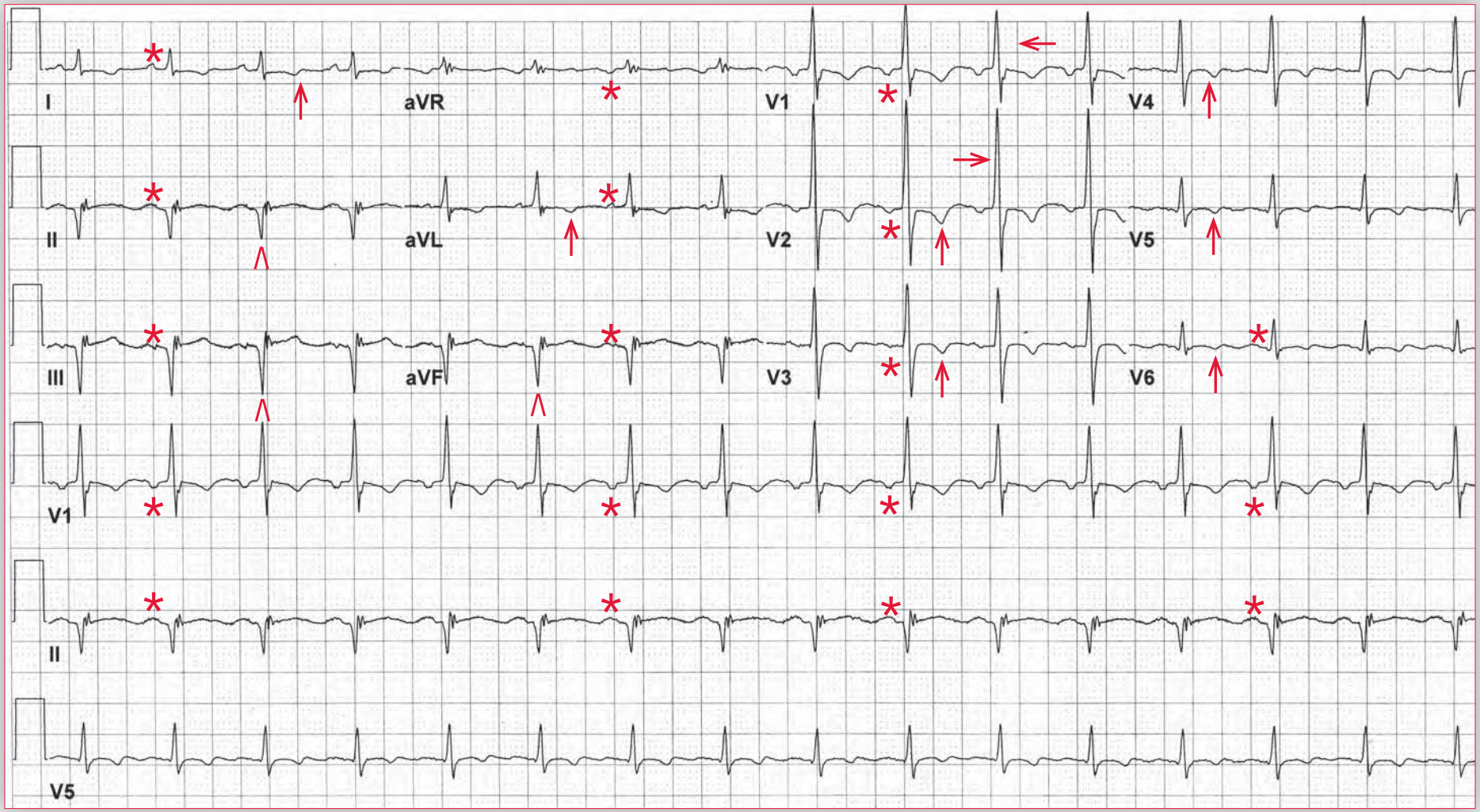

ECG 82 Analysis: Normal sinus rhythm, old inferior wall MI, old posterior wall MI, counterclockwise rotation (early transition), nonspecific T-wave abnormalities, left axis deviation due to an old inferior wall MI, left atrial hypertrophy or abnormality

There is a regular rhythm at a rate of 94 bpm. There is a P wave (*) before each QRS complex, with a stable PR interval (0.16 sec). The P wave is positive in leads I, II, aVF, and V4-V6 and negative in lead aVR. This is a normal sinus rhythm. The P wave is very negative in leads V1-V2, consistent with left atrial hypertrophy (or abnormality).

The QRS complex duration is normal (0.10 sec). The QT/QTc intervals are normal (320/400 msec). There are Q waves (^) in leads II, III, and aVF, diagnostic for an old inferior wall myocardial infarction (MI). As a result of the inferior Q waves, the axis appears to be extremely leftward (between –30° and –90°). An extreme left axis deviation is also characteristic of a left anterior fascicular block (positive QRS complex in lead I and negative QRS complex in leads II and aVF with an rS morphology). However, the left axis deviation in this case is a result of the inferior wall MI (QRS complexes have a Qr morphology) and is not a morphology of a fascicular block.

There is also a tall R wave in lead V1 (←), which, along with the inferior wall MI, is characteristic of posterior wall infarction; hence there is an inferoposterior wall MI. Simultaneous infarction of the posterior and inferior walls is most often caused by infarction of a large dominant right coronary artery (with posterolateral ventricular extension), although it can also occur from circumflex occlusion in the setting of a left dominant circulation.

The tall R wave in lead V2 (→) may be from the posterior wall infarction, but it is also likely the result of counterclockwise rotation or early transition. This is due to a shift of the electrical axis in the horizontal plane and is established by imagining the heart as viewed from under the diaphragm. When the electrical axis is shifted in a counterclockwise direction, left ventricular forces occur early and are prominent in the right precordial leads (*ie*, a tall R wave in lead V2).

Lastly, there are T-wave inversions (↑) present in leads I, aVL, and V2-V6. In the absence of any clinical history or data, these are considered nonspecific. ■

Notes

Practice Case 83

A 48-year-old African-American man presents to his primary care physician with epigastric discomfort for 3 weeks. The pain often occurs when he lies down to go to bed. It has not occurred with eating. His physician obtains an ECG.

What does his ECG show?

What is the likely diagnosis?

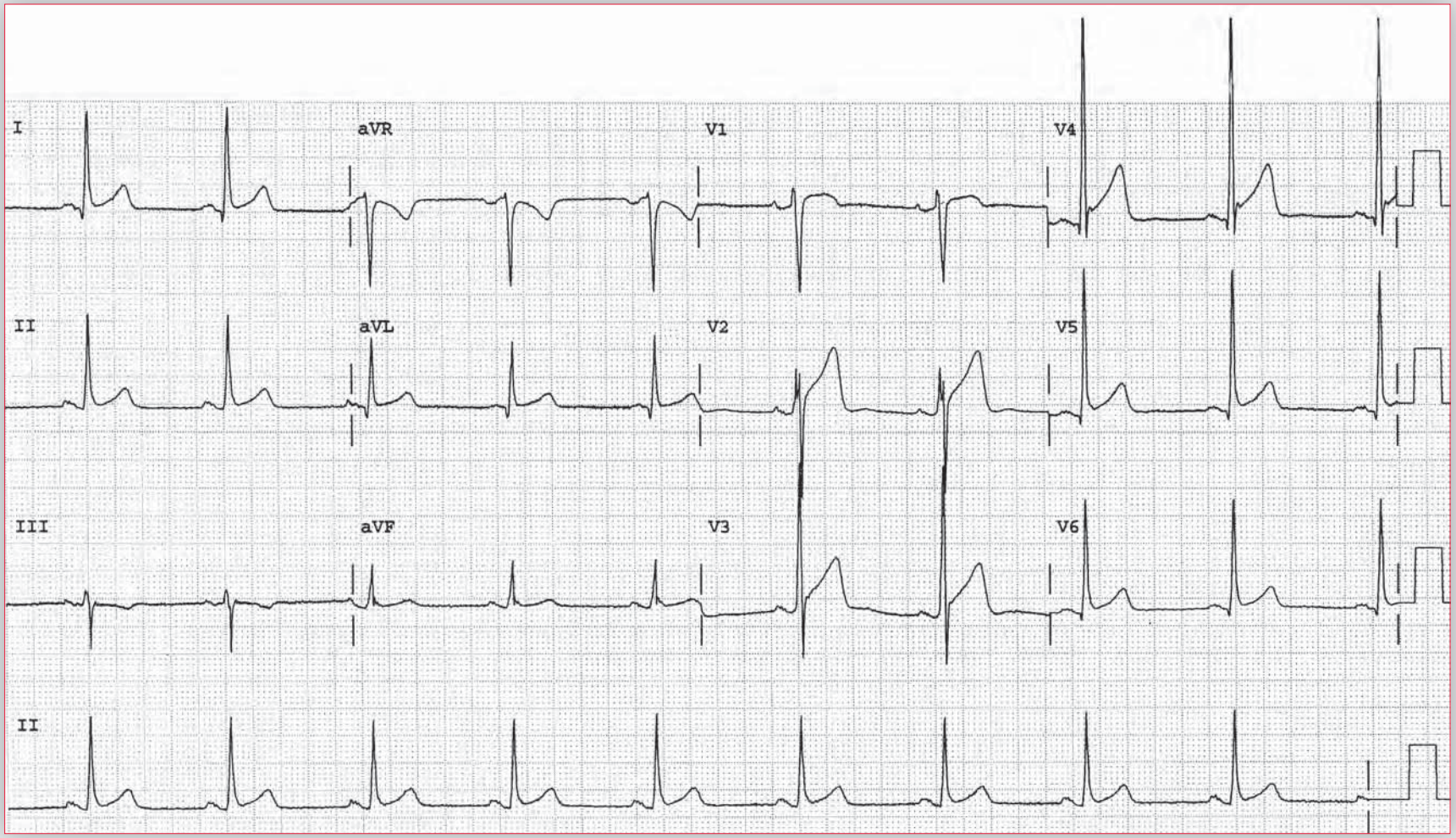

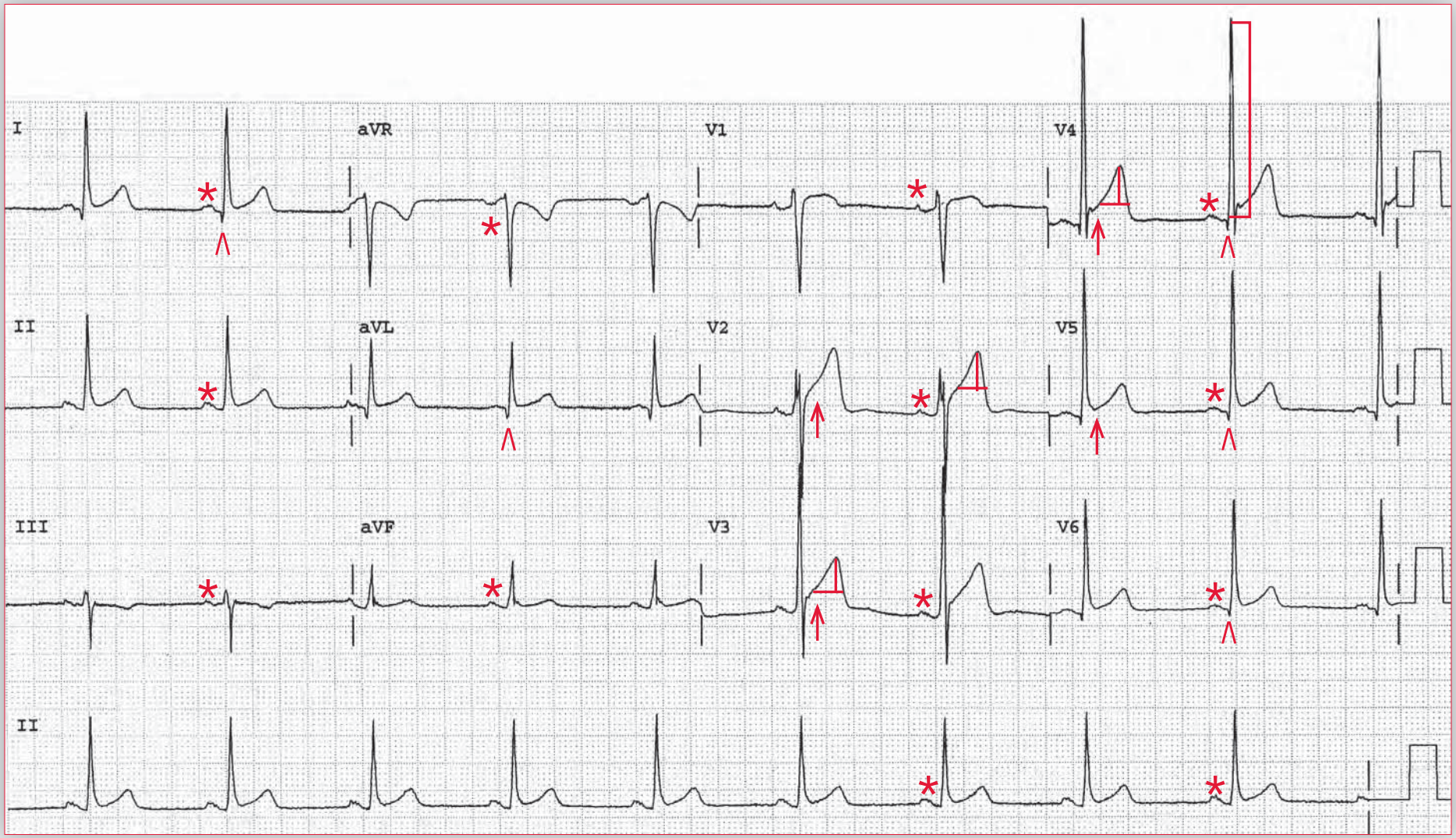

ECG 83 Analysis: Sinus bradycardia, left ventricular hypertrophy, early repolarization

There is a regular rhythm at a rate of 58 bpm. There is a P wave (*) before each QRS complex, with a stable PR interval (0.16 sec). The P waves are positive in leads I, II, aVF, and V4-V6, and they have a normal morphology. This is sinus bradycardia.

The QRS complex duration is normal (0.08 sec), and the complexes have a normal morphology. The axis is normal, between 0° and +90° (positive QRS complex in leads I and aVF). The QT/QTc intervals are normal (400/390 msec). The amplitude of the R wave in lead V4 is increased (38 mm) ( ]), meeting one of the criteria for left ventricular hypertrophy (*ie*, S-wave depth or R-wave amplitude in any precordial lead ≥ 25 mm). However, this voltage might be normal if this were a thin-chested, healthy man free of lung disease. There are small Q waves (^) in leads I, aVL, and V4-V6, representing septal activation (septal Q waves). Although the T waves are prominent, especially in leads V2-V4, they are asymmetric and prominent as a result of left ventricular hypertrophy. J-point and ST-segment elevation (↑) are noted above the baseline (TP segment) in leads V2-V5. This is early repolarization, which is a normal finding often seen in association with left ventricular hypertrophy as well as in young patients with or without prominent R-wave amplitude. This pattern is more common among African Americans but is seen in people of all races. The T waves are asymmetric and are normal in morphology.

No changes on the ECG are suggestive of a cardiac cause for his abdominal discomfort. Indeed, the symptoms are not typical for myocardial ischemia or angina. The symptoms are more likely gastrointestinal and hence a gastrointestinal workup is indicated. ■

Notes

Practice Case 84

A 54-year-old man presents to the emergency department with fever, cough, and pleuritic chest pain. On exam he is noted to be tachycardic and has bronchial breath sounds in the left lower lung zone. An ECG is obtained.

What does his ECG show?

What is the likely diagnosis?

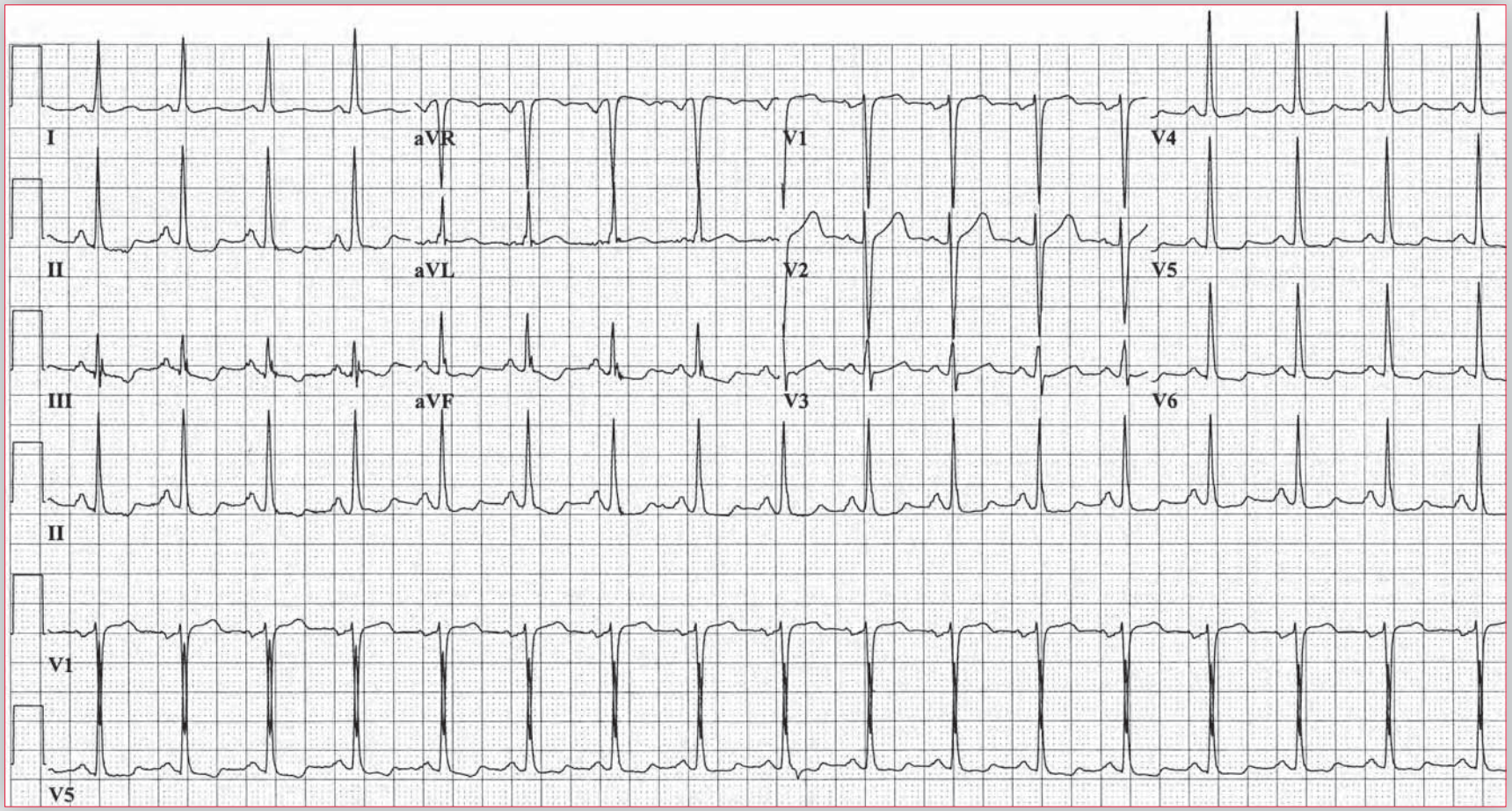

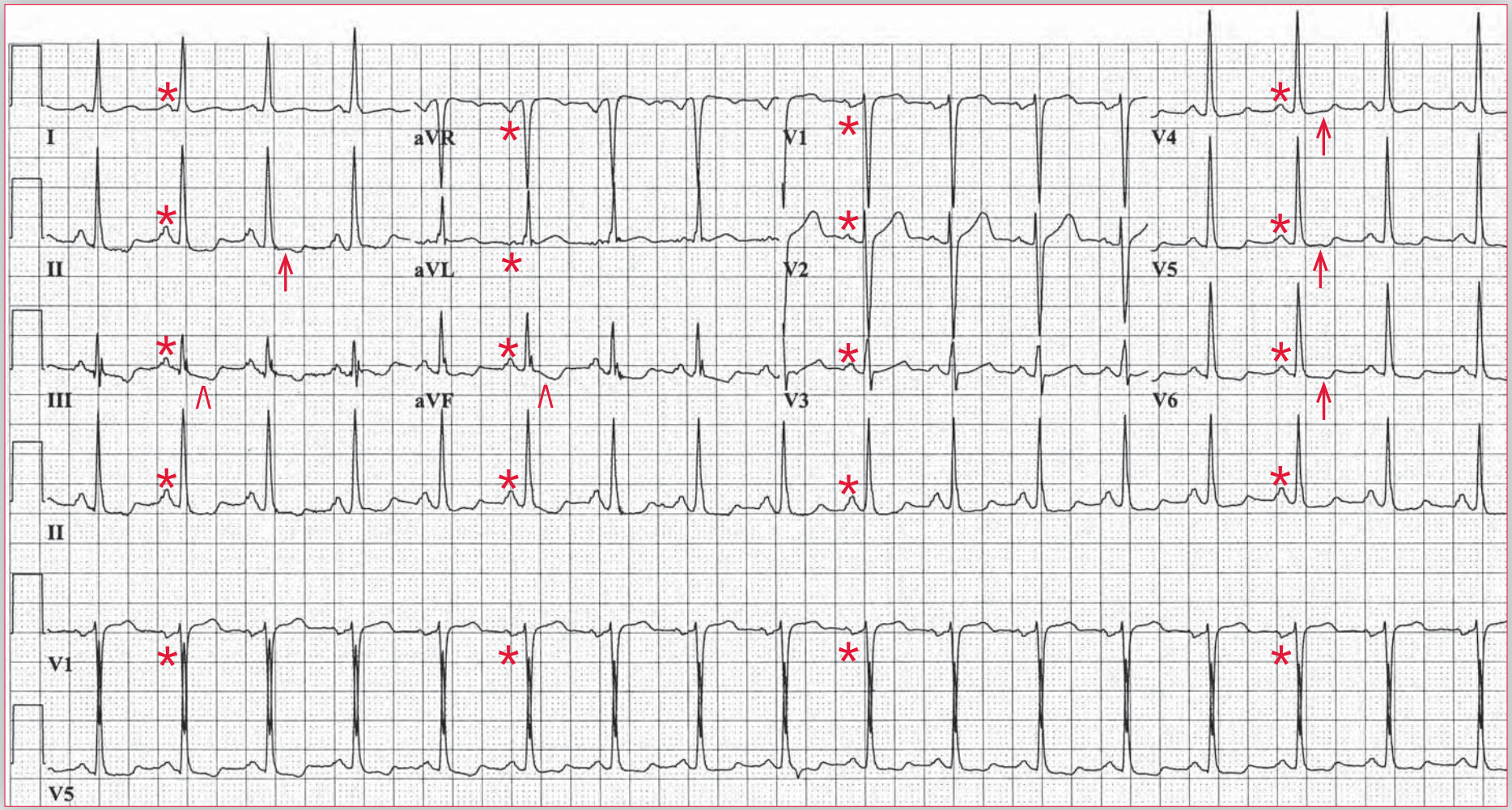

ECG 84 Analysis: Sinus tachycardia, nonspecific ST-segment changes

There is a regular rhythm at a rate of 110 bpm. There is a P wave (*) before each QRS complex, and the P wave is positive in leads I, II, aVF, and V4-V6 and negative in lead aVR. The P-wave morphology is normal. This is a sinus tachycardia.

The QRS complex duration is normal (0.08 sec), and it has a normal morphology. The axis is normal, between 0° and +90° (positive QRS complex in leads I and aVF). There is normal R-wave progression from leads V1 to V6. The QT/QTc intervals are normal (320/430 msec). ST-segment flattening (↑) is noted in leads II and V4-V6. This is a nonspecific ST-segment change. The ST segments in leads III and aVF (^) are downsloping but are less than 1 mm below baseline (the TP segment). These are also nonspecific ST-segment changes.

There is no definitive evidence of myocardial ischemia on this ECG, suggesting that the patient's pleuritic chest pain is noncardiac in nature. There is no clinical or ECG evidence for an acute coronary syndrome. The presence of fever, tachycardia, and bronchial breath sounds makes a pulmonary infection a more likely diagnosis. Nonspecific ST-segment changes are common in patients with concomitant medical illnesses. ■

Notes

Practice Case 85

A 76-year-old woman with hypertension and diabetes develops lightheadedness and diaphoresis while sitting at the dinner table with her family. She begins to feel nauseated and vomits. Her family calls emergency medical services, who find her appearing fatigued and diaphoretic. She complains of mild chest discomfort and is given one tablet of sublingual nitroglycerin, after which she transiently loses consciousness.

What does her ECG show?

What is the likely diagnosis?

What coronary artery is likely to be involved?

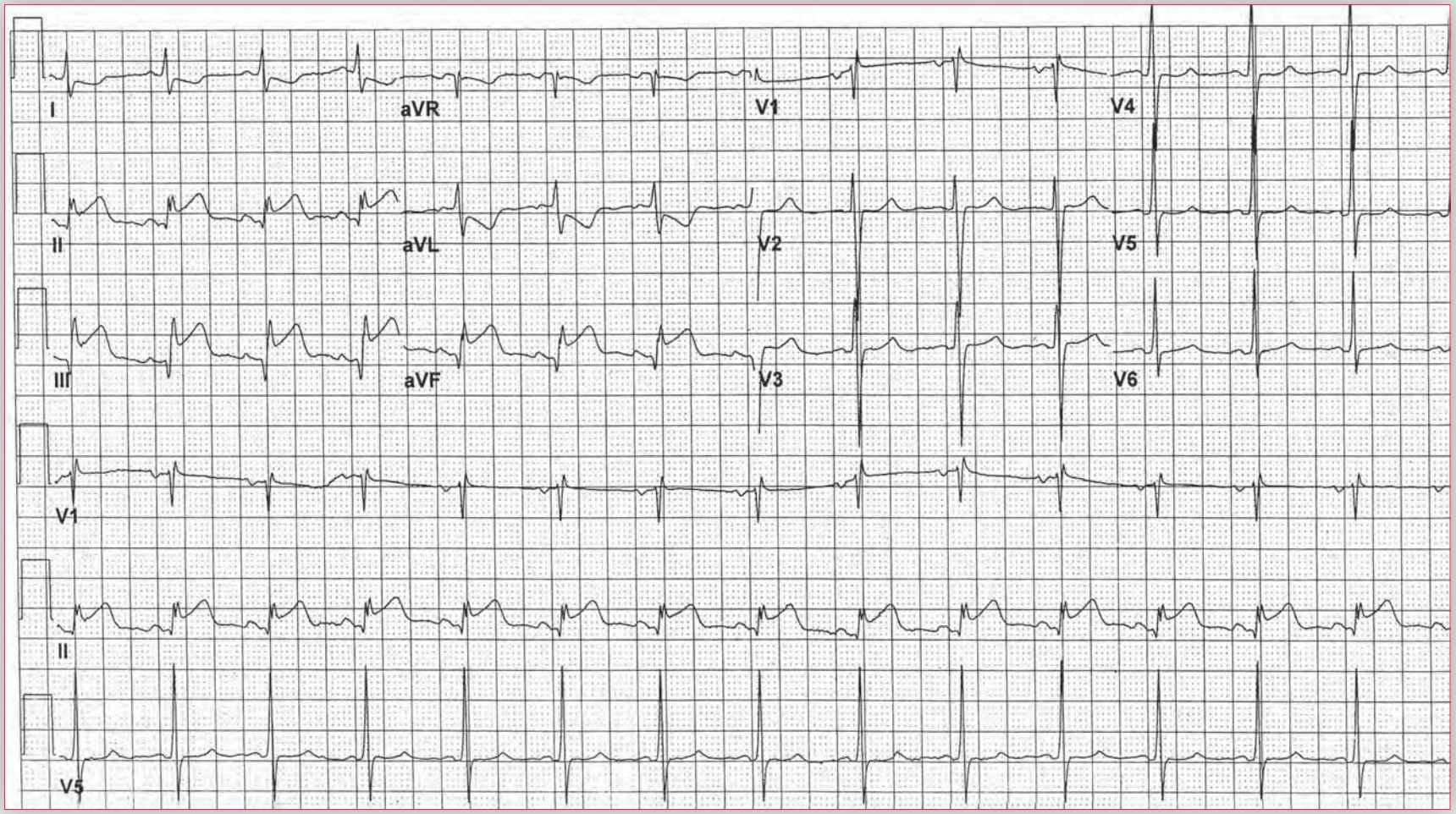

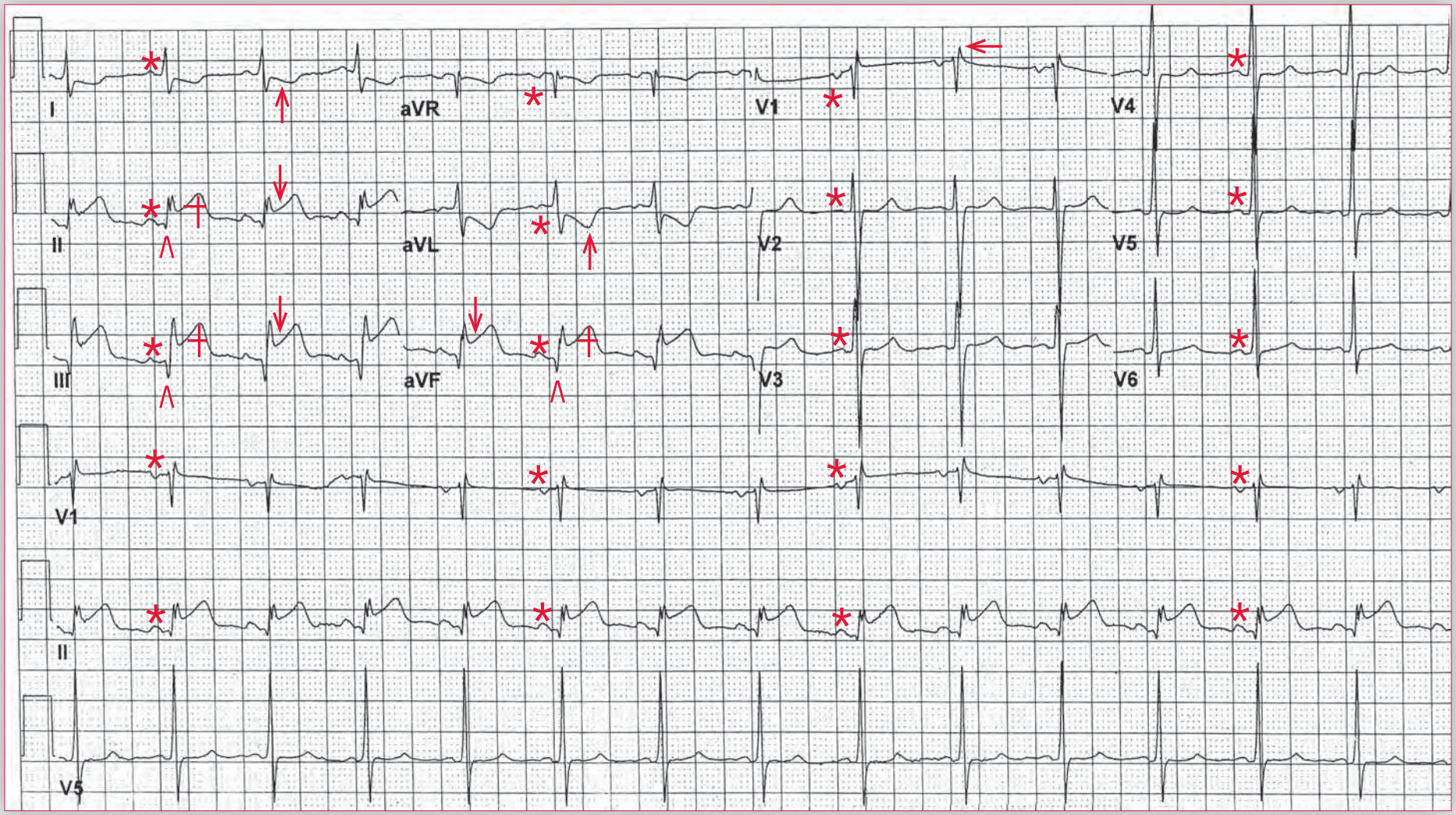

ECG 85 Analysis: Normal sinus rhythm, intraventricular conduction delay, acute inferior wall ST-segment elevation myocardial infarction (STEMI)

There is a regular rhythm at a rate of 86 bpm. There is a P wave (*) before each QRS complex, with a stable PR interval (0.16 sec). The P wave is positive in leads I, II, aVF, and V4-V6 and negative in lead aVR. The P-wave morphology is normal. This is a normal sinus rhythm.

The QRS complex duration is normal (0.10 sec), as is the axis, which is between 0° and +90° (positive QRS complex in leads I and aVF). There is an RSR′ morphology (←) in lead V1, which represents a conduction delay to the right ventricle (intraventricular conduction delay). The QT/QTc intervals are normal (340/410 msec).

ST-segment elevation (↓) with symmetric T waves is noted in leads II, III, and aVF. The ST segments still have a concave morphology. This is, therefore, an acute inferior wall ST-segment elevation myocardial infarction (STEMI). Q waves (^) are present in leads III and aVF. Also noted are ST-segment depressions (↑) in leads I and aVL; these are reciprocal changes.

This patient demonstrates marked sensitivity to nitroglycerin. The action of nitroglycerin is venodilation and a reduction in venous return. Hypotension with this medication can occur in the setting of volume depletion. Another situation in which hypotension can occur with nitroglycerin is infarction of the free wall of the right ventricle, which may be associated with an inferior wall STEMI. With a right ventricular infarction the left ventricle may be underfilled due to poor right ventricular output and a situation that resembles venous pooling of blood. Administration of venodilators, such as sublingual nitroglycerin, can augment this effect by reducing right ventricular filling and hence right ventricular stroke volume and left ventricular filling. This may produce profound hypotension as was observed in this case. The treatment is fluids to maintain right ventricular pressure and hence left ventricular filling. Another cause for hypotension is enhanced vagal tone, which often occurs with an inferior wall STEMI. The hypotension may be enhanced with the use of nitroglycerin. Right ventricular infarction can occur in the setting of a very proximal right coronary artery occlusion. ■

Notes

Practice Case 86

A 55-year-old man is seen in clinic for a preoperative evaluation before undergoing elective surgery for an abdominal aortic aneurysm. He has hypertension, dyslipidemia, and a 40 pack-year smoking history. As he walks into the clinic, he complains of substernal chest discomfort and an ECG is quickly obtained. Blood pressure at the time is 190/90 mm Hg.

What does his ECG show?

What is the likely diagnosis?

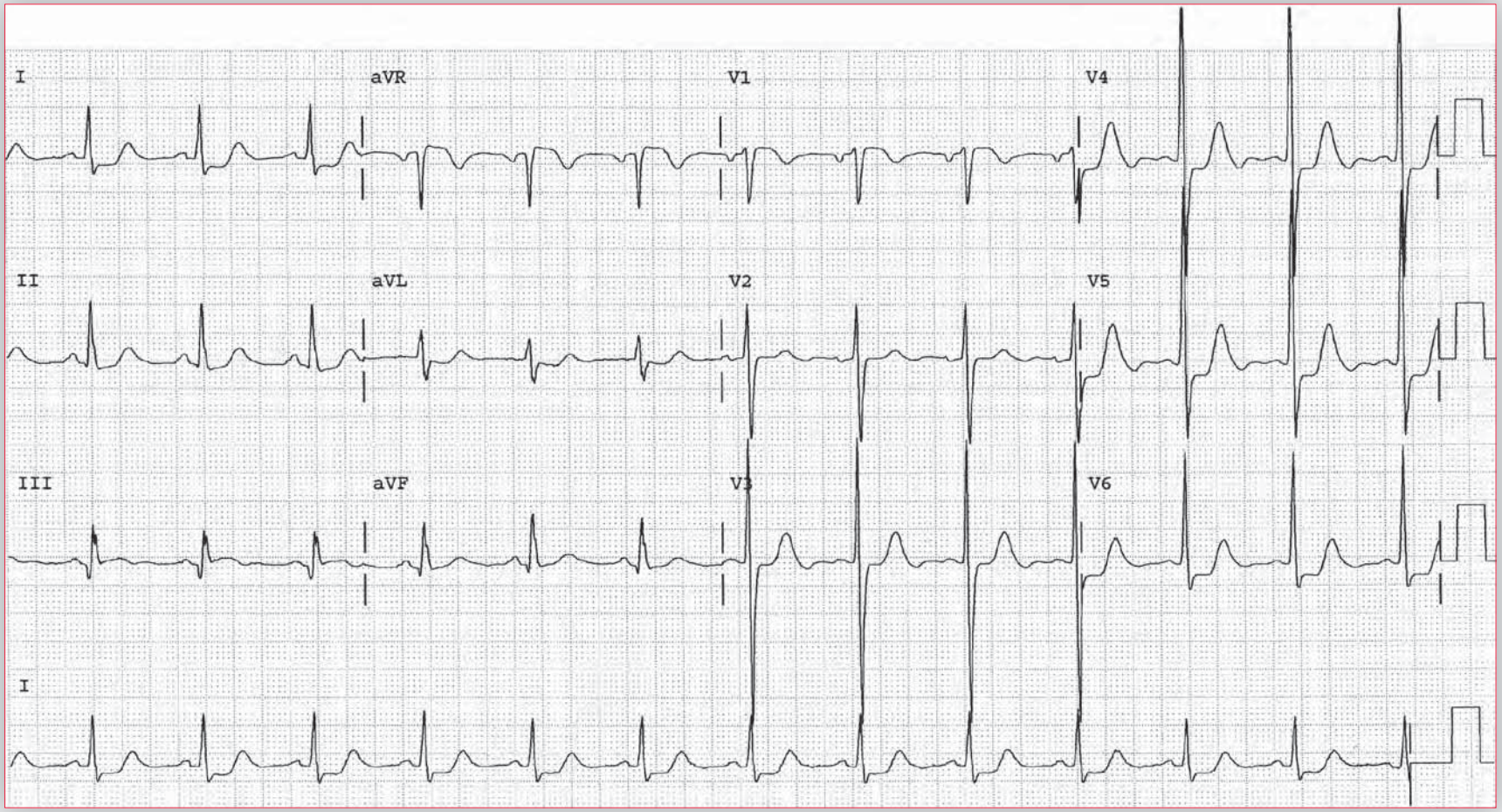

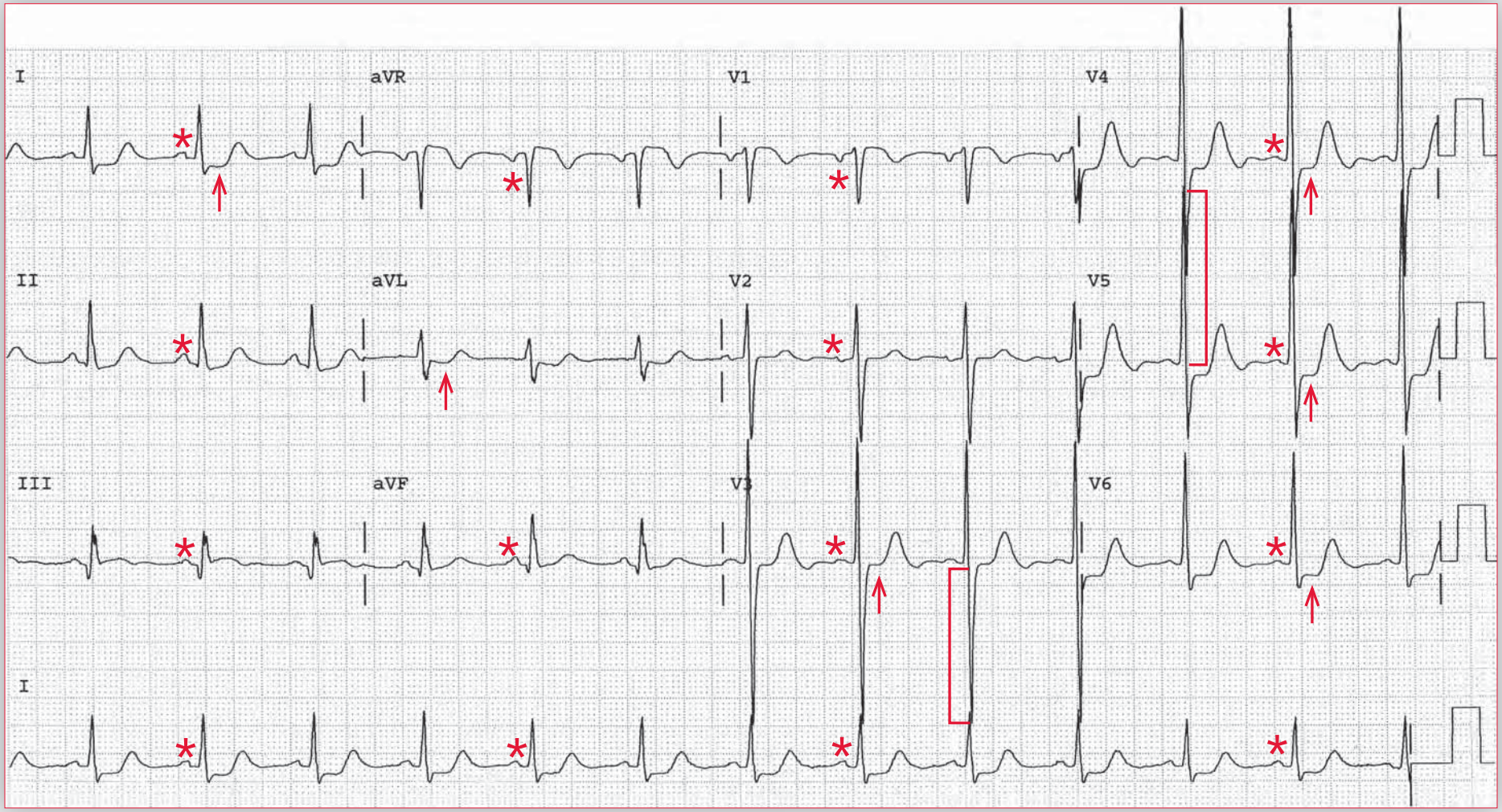

ECG 86 Analysis: Normal sinus rhythm, left ventricular hypertrophy (LVH), horizontal ST-segment depression, left atrial hypertrophy or abnormality

There is a regular rhythm at a rate of 78 bpm. There is a P wave (*) before each QRS complex, with a stable PR interval (0.16 sec). The P wave is positive in leads I, II, aVF, and V4-V6 and negative in lead aVR. This is a normal sinus rhythm. The P wave is primarily negative in lead V1, suggesting left atrial hypertrophy or abnormality.

The QRS complex duration (0.10 sec) and morphology are normal. The axis is normal, between 0° and +90° (positive QRS complex in lead I and aVF). The QT/QTc intervals are normal. There is normal R-wave wave progression from leads V1 to V6. However, the R-wave amplitude (voltage) in lead V5 is increased (30 mm) ( ]) as is the S-wave depth (voltage) in lead V3 (28 mm) ([ ) (S-wave depth in lead V3 + R-wave amplitude in lead V5 = 58 mm). Criteria for left ventricular hypertrophy (LVH) are present (*ie*, S-wave depth in any precordial lead + R-wave amplitude in any precordial lead ≥ 35 mm). There is J-point and 1- to 2-mm horizontal ST-segment depression (↑) noted in leads I, aVL, and V3-V6. This represents subendocardial ischemia, which may be the result of coronary artery disease or underlying LVH.

This patient has LVH on the basis of longstanding hypertension. The ECG changes could be related to subendocardial ischemia caused by increased wall stress occurring as a result of markedly elevated blood pressure. However, the chest pain and ECG changes may also represent epicardial coronary artery disease and exertional angina as it is common for angina due to coronary artery disease to be associated with a hypertensive response. This patient should undergo further evaluation. The chest discomfort and markedly elevated blood pressure should be treated immediately, and a repeat ECG should be obtained. Once blood pressure is controlled, the patient should undergo further coronary risk stratification, likely with some form of noninvasive evaluation, such as a treadmill exercise test or exercise echocardiogram. The exercise test would also be important to document the blood pressure response and evaluate the adequacy of antihypertensive therapy. If there is evidence of provoked ischemia, further therapy with anti-ischemic medications would be important.

The diagnosis of coronary artery disease before a major surgery poses a difficult problem. If the patient presents with an acute coronary syndrome, he or she should undergo revascularization before surgery not only to get through the surgery but also for clinical reasons. Elective revascularization prior to noncardiac surgery (especially high-risk vascular surgery) in the absence of an acute coronary syndrome or a clinical indication is not necessary; the outcome with medical therapy is the same as with revascularization (CARP trial). ■

Notes

Practice Case 87

A 78-year-old man develops chest discomfort while on an international flight. The discomfort started shortly after takeoff and persisted despite taking sublingual nitroglycerin. Three hours into the flight, he alerts the flight staff, who divert the plane to land urgently. The plane lands about 1 hour later, and the patient is rushed to the emergency department. Upon questioning, he recalls that he had a myocardial infarction (MI) 10 years earlier. The heart attack was treated with an angioplasty and medical therapy.

What does his ECG show?

What is the likely diagnosis?

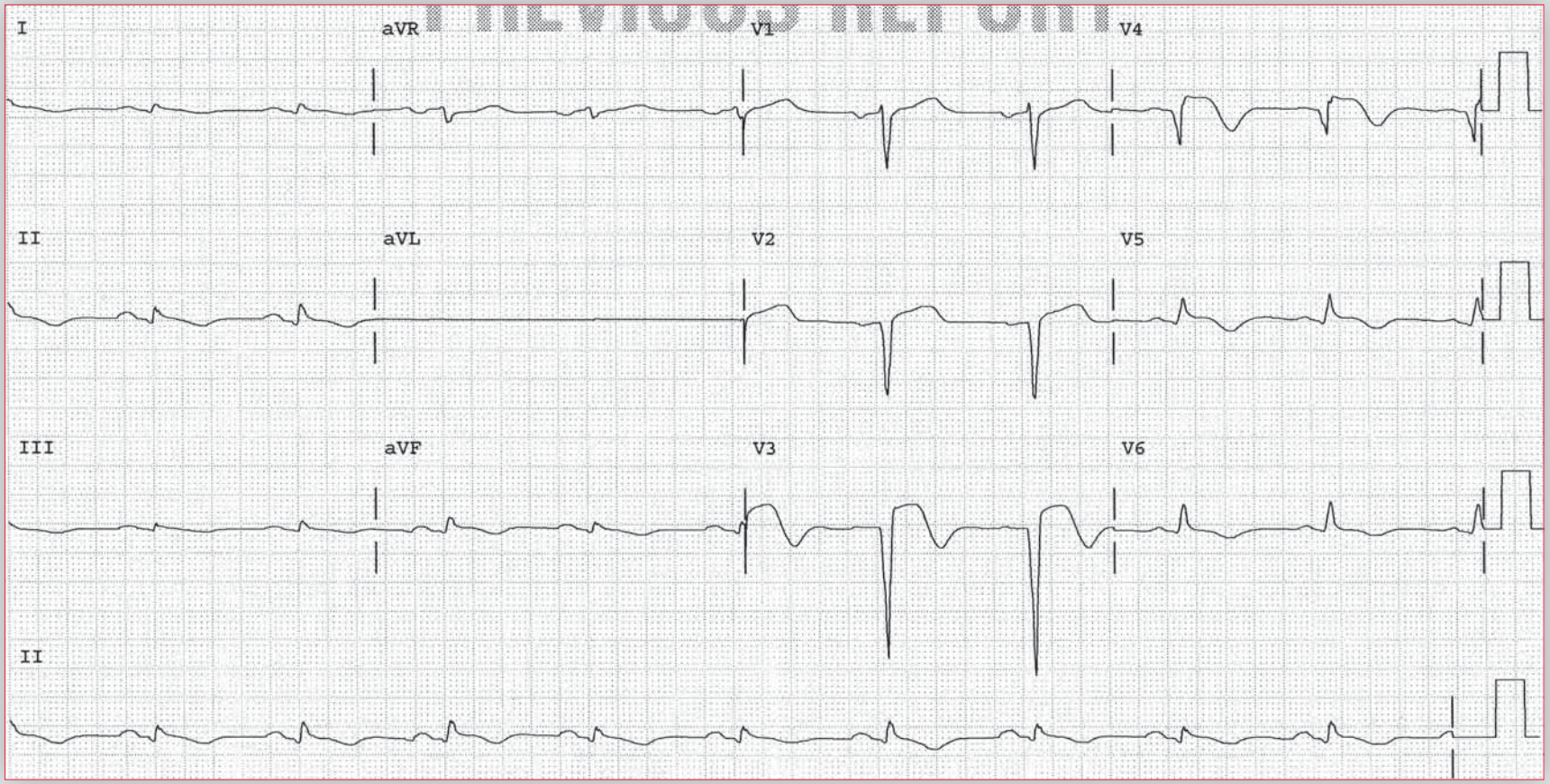

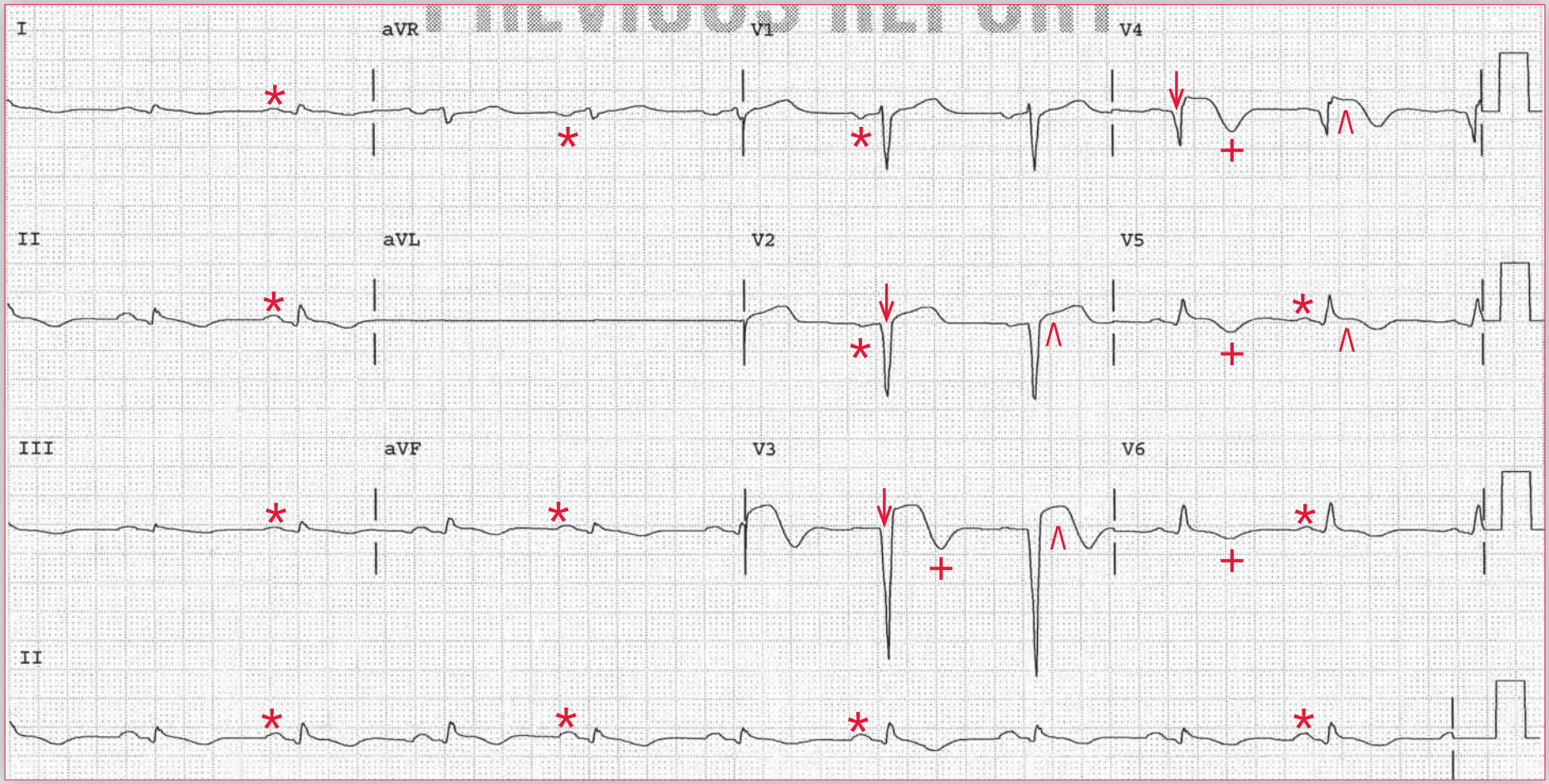

ECG 87 Analysis: Normal sinus rhythm, first-degree AV block, anteroapical MI, low-voltage limb leads

There is a regular rhythm at a rate of 60 bpm. There is a P wave (*) before each QRS complex, and the PR interval is stable (0.24 sec). The P wave is upright in leads I, II, aVF, and V4-V6 and negative in lead aVR. The P-wave morphology is normal. This is a normal sinus rhythm with a first-degree AV block.

The QRS complex duration is borderline normal (0.10 sec), and the axis is normal, between 0° and +90° (positive QRS complex in leads I and aVF). The QRS complex amplitude (voltage) is low in the limb leads (defined as a QRS amplitude ≤ 5 mm in each limb lead), and hence there is low voltage. The QRS complex morphology is abnormal, and there are QS complexes (↓) in leads V2-V4, diagnostic for an antero-apical myocardial infarction (MI). The QT/QTc intervals are normal (440/440 msec and 420/420 msec when corrected for the prolonged QRS complex duration).

The ST segments (^) are still elevated, and the T waves (+) have become inverted. Therefore, this might be a later stage of an acute ST-segment elevation MI (STEMI) that is evolving. It could, however, represent an old MI with the presence of an aneurysm. To establish whether these findings represent evolutionary changes or an aneurysm, it would be important to know the patient's history, prior ECGs, and cardiac biomarkers. If the event were recent, cardiac biomarkers would be elevated and prior ECGs would not show any evidence of a previous MI in the same leads. The ECG abnormalities would therefore represent an acute MI in evolution. In contrast, if a prior ECG showed evidence of an infarction in the same location and if cardiac biomarkers were not elevated, then the ECG would represent an aneurysm. ■

Notes

Practice Case 88

A 72-year-old man presents to the emergency department with chest pain. The attending physician asks the resident if there is any evidence of ischemia or infarction on his ECG. The resident replies that there is a left bundle branch block and hence acute changes cannot be established.

Can one assess for ischemia on this ECG?

What does his ECG show?

What is the likely diagnosis?

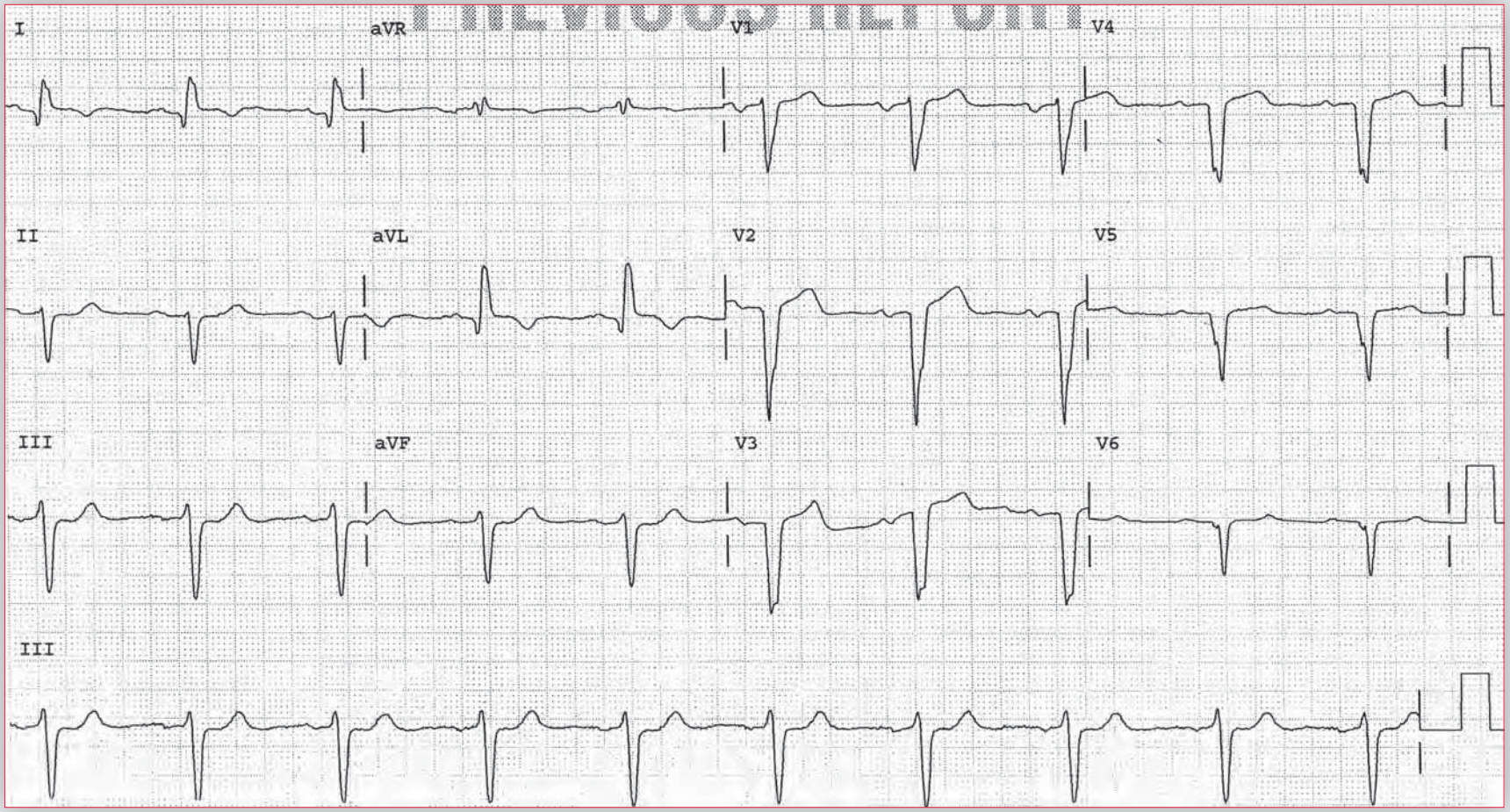

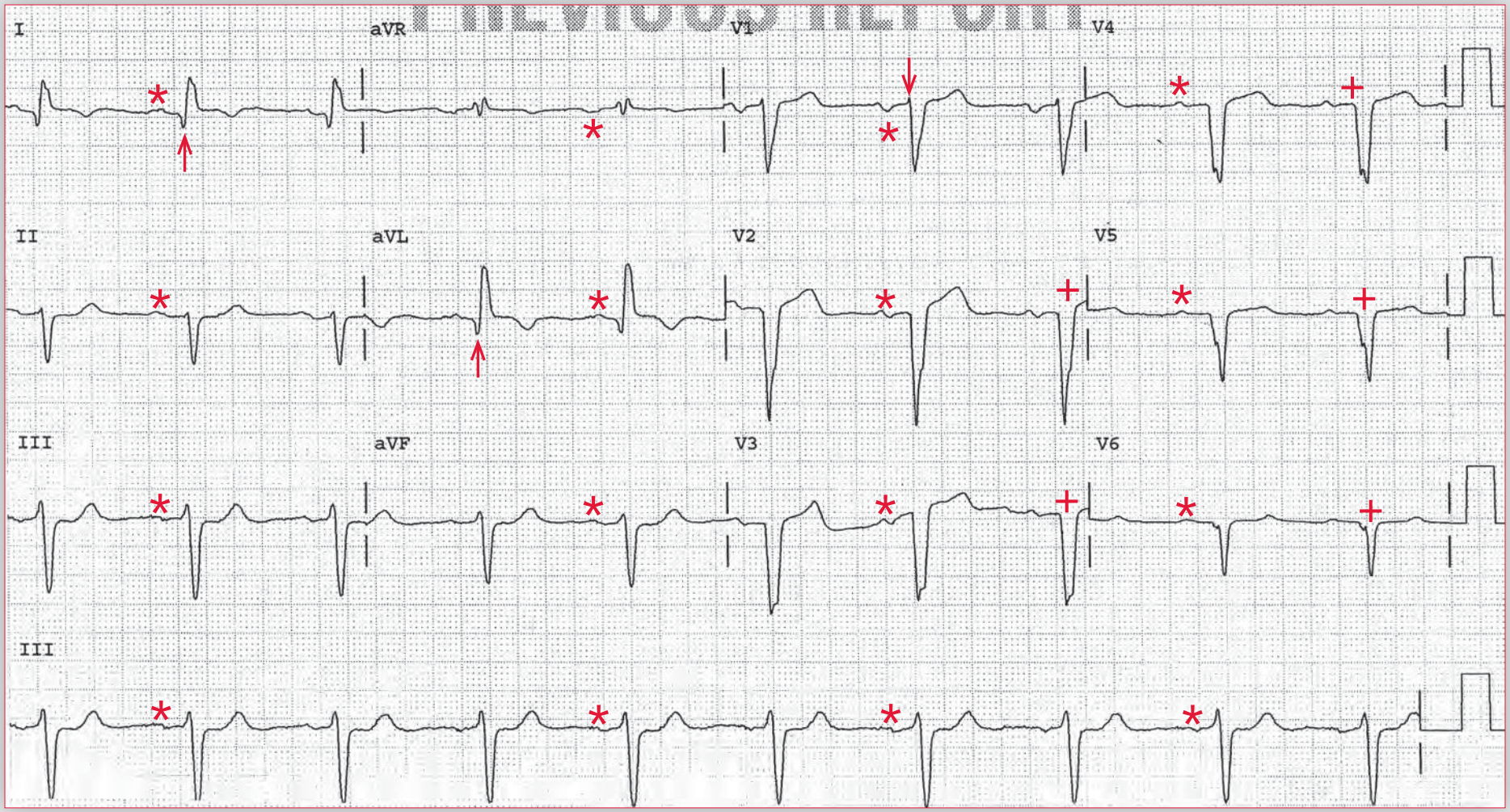

ECG 88 Analysis: Sinus bradycardia, intraventricular conduction delay, old lateral wall myocardial infarction (MI), old anterior wall MI, left anterior fascicular block, first-degree AV block

There is a regular rhythm at a rate of 58 bpm. There are P waves (*) before each QRS complex, with a stable PR interval (0.26 sec). The P waves are upright in leads I, II, aVF, and V4-V6 and negative in lead aVR. The P-wave morphology is normal. This is a normal sinus rhythm with first-degree AV block or prolonged AV conduction.

The QRS complex duration is prolonged (0.14 sec). There is a pattern resembling a left bundle branch block (LBBB), with a broad R wave in lead I and a deep, broad S wave in lead V1. However, there is an initial R wave in lead V1 (↓), indicating an initial septal force, as well as Q waves (↑) in leads I and aVL. In addition, there are broad QS complexes in leads V4-V6. Although this can be seen with an LBBB, the QS complexes in leads V4-V6 generally mean that the electrical impulse is going in a left-to-right direction, which does not occur with an LBBB (in which all the ventricular forces travel in a right-to-left direction only). The rightward-directed forces, when associated with the presence of a septal R wave in lead V1 and lateral Q waves, means that this is not an LBBB but rather an intraventricular conduction delay. In this situation the Q waves in leads I and aVL are diagnostic for an old lateral wall myocardial infarction (MI). There are also QS complexes (+) in leads V2-V6, diagnostic for an extensive anterior wall MI. The axis is extremely leftward, between –30° and –90° (positive QRS complex in lead I and negative QRS complex in leads II and aVF, with an rS morphology), a result of a left anterior fascicular block. The QT/QTc intervals are normal (440/430 msec and 380/370 msec when corrected for the prolonged QRS complex duration).

Although it is difficult to make the diagnosis of myocardial ischemia in the context of an LBBB, physicians must be careful not to confuse an anterior MI with an LBBB as the QRS complex morphology can be similar (*ie*, a QS complex in the precordial leads). As the ECG shows intact septal forces, resulting from septal activation that occurs via a septal branch arising from the left bundle, the left bundle cannot be blocked. Therefore, this patient does not have an LBBB but has an intraventricular conduction delay associated with a prior lateral and anterior MI. Hence in this situation the ECG can be evaluated with regard to ischemic changes or other abnormalities of the left ventricular myocardium. Axis can also be determined. With an LBBB, left ventricular activation is not via the normal His-Purkinje system but rather by direct myocardial activation. Hence, abnormalities of the left ventricle cannot be reliably diagnosed. In contrast, an intraventricular conduction delay is slowed conduction through the normal His-Purkinje system. Hence left ventricular activation is via the normal conduction system and left ventricular abnormalities can be diagnosed. ■

Notes

Practice Case 89

A 72-year-old woman with chronic kidney disease on hemodialysis presents to her primary care physician for evaluation of chest discomfort. She has missed two successive hemodialysis sessions due to a family emergency. She reported worsening of the discomfort with inspiration and supine positioning.

What does her ECG show?

What is the likely diagnosis?

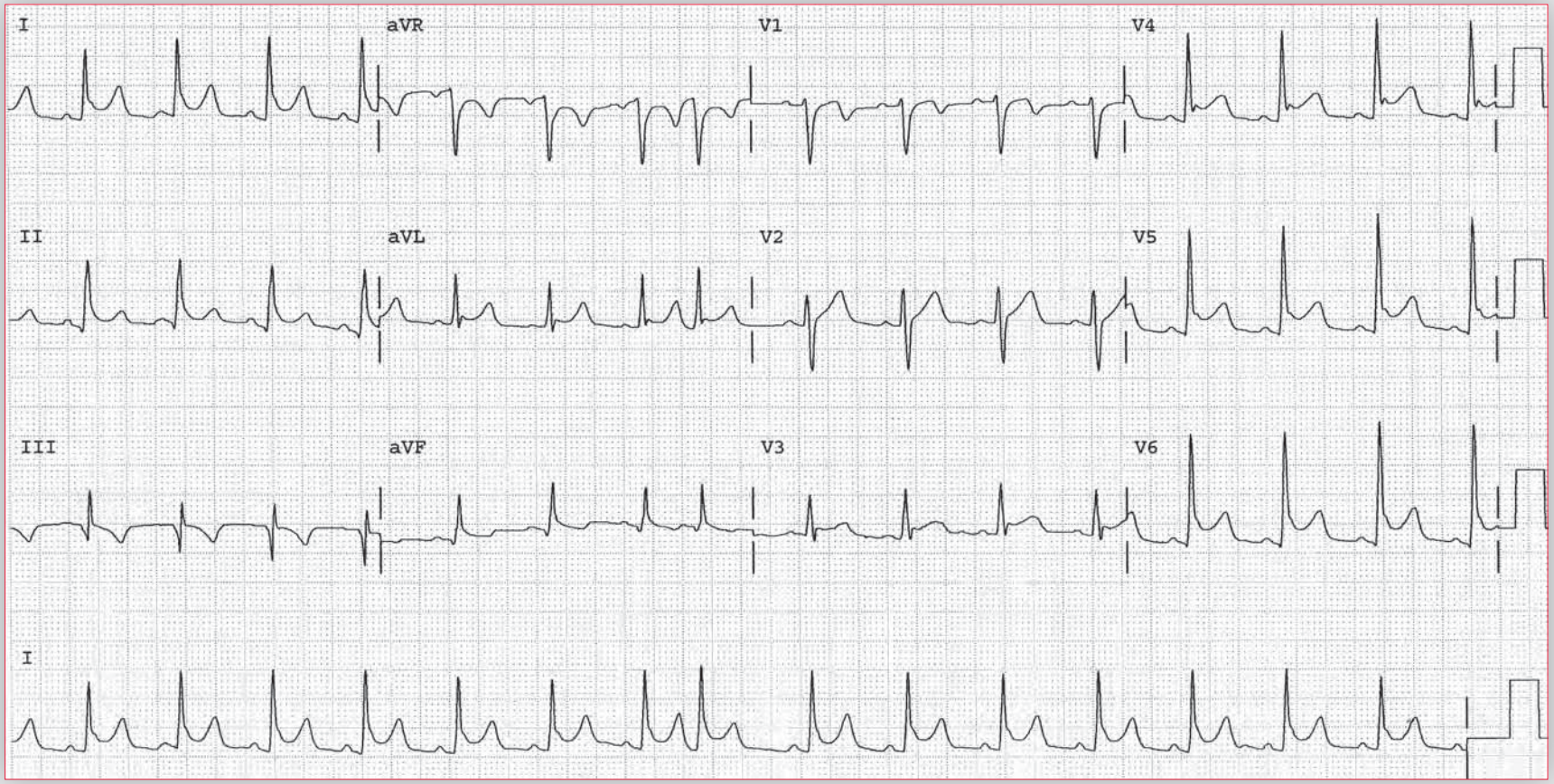

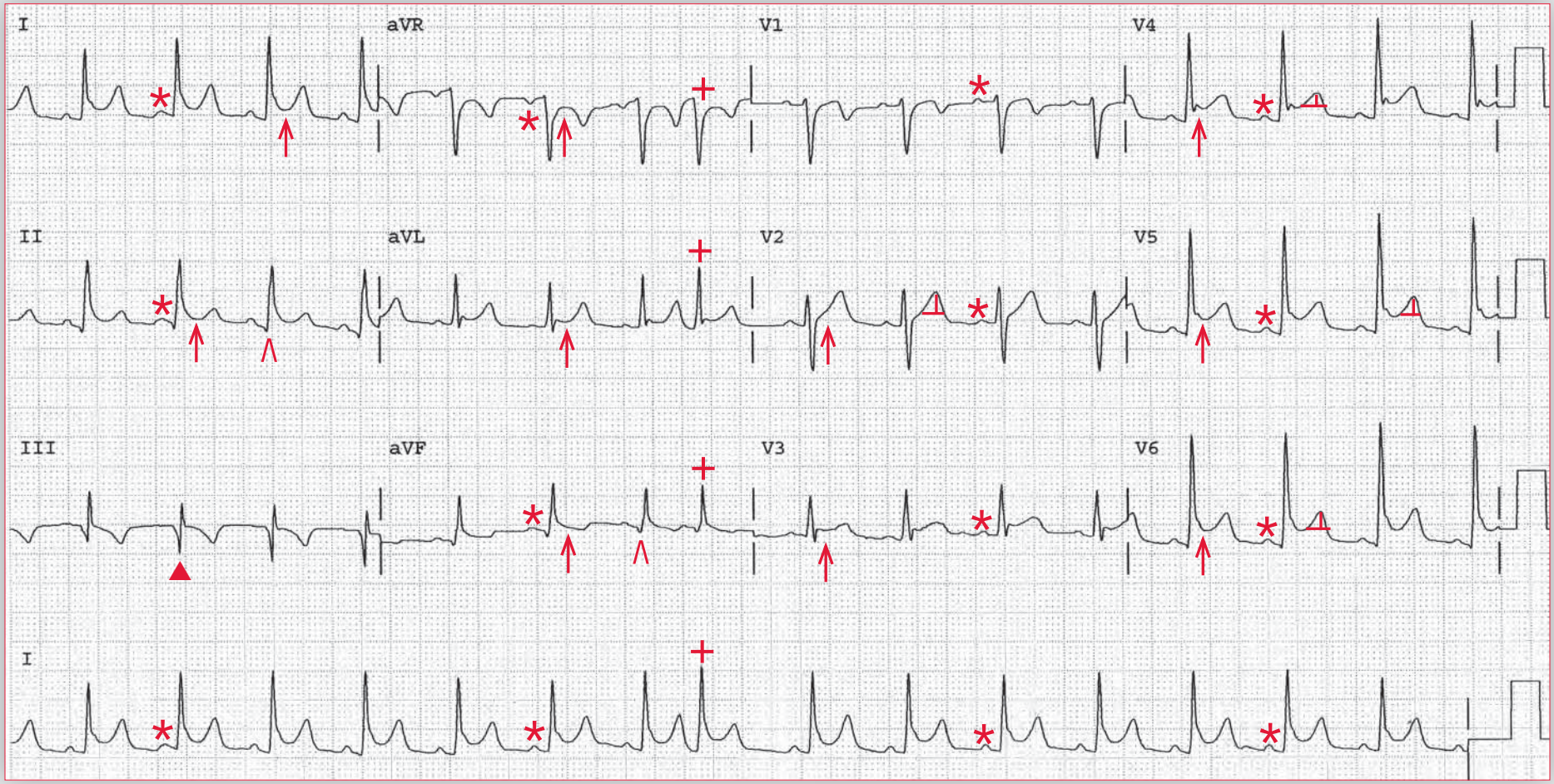

ECG 89 Analysis: Normal sinus rhythm, premature junctional complex, pericarditis

There is a regular rhythm at a rate of 94 bpm. There is a P wave (*) before each QRS complex, with a stable PR interval (0.14 sec). The P-wave morphology is normal. This is a normal sinus rhythm.

The QRS complex duration is normal (0.10 sec), and there is a normal axis, between 0° and +90° (positive QRS complex in leads I and aVF). The QT/QTc intervals are normal (320/400 msec). The QRS complex morphology is normal, although there are small and narrow Q waves (^) in leads II and aVF and a wider and deeper Q wave in lead III (▲). Lead III is an indeterminate lead, and the Q waves in leads II and aVF do not meet criteria for an old myocardial infarction (*ie*, > 0.04 sec and >1 mm deep) and therefore represent septal forces.

The eighth QRS complex is early or premature (+). It has the same QRS morphology as the other complexes. There is no apparent P wave before this early complex. Therefore, this is a premature supraventricular complex and is likely a premature junctional complex.

There is diffuse J-point and ST-segment elevation (↑) above the baseline (TP segment) in leads I, II, aVR (ST-segment depression in this lead is actually elevation), aVL, aVF, and V3-V6. The ST segments have a concave morphology. The T waves are normal and asymmetric. The ECG shows pericarditis.

This patient likely has acute uremic pericarditis as a consequence of having missed two successive hemodialysis sessions. Uremic pericarditis responds to initiation of hemodialysis and tends to respond poorly to anti-inflammatory medications. ■

Notes

Practice Case 90

A 36-year-old man with type 1 diabetes mellitus is found collapsed on the floor of his apartment. He has been drinking heavily and has not been seen by any of his family members for 48 hours. He is intubated in the field and brought to the nearest emergency department. There he is found to have a blood glucose level of 780 mg/dl, potassium level of 6.7 mmol/L, creatinine level of 4.8 mg/dl, and an anion gap of 28.

What does his ECG show?

What is the likely diagnosis?

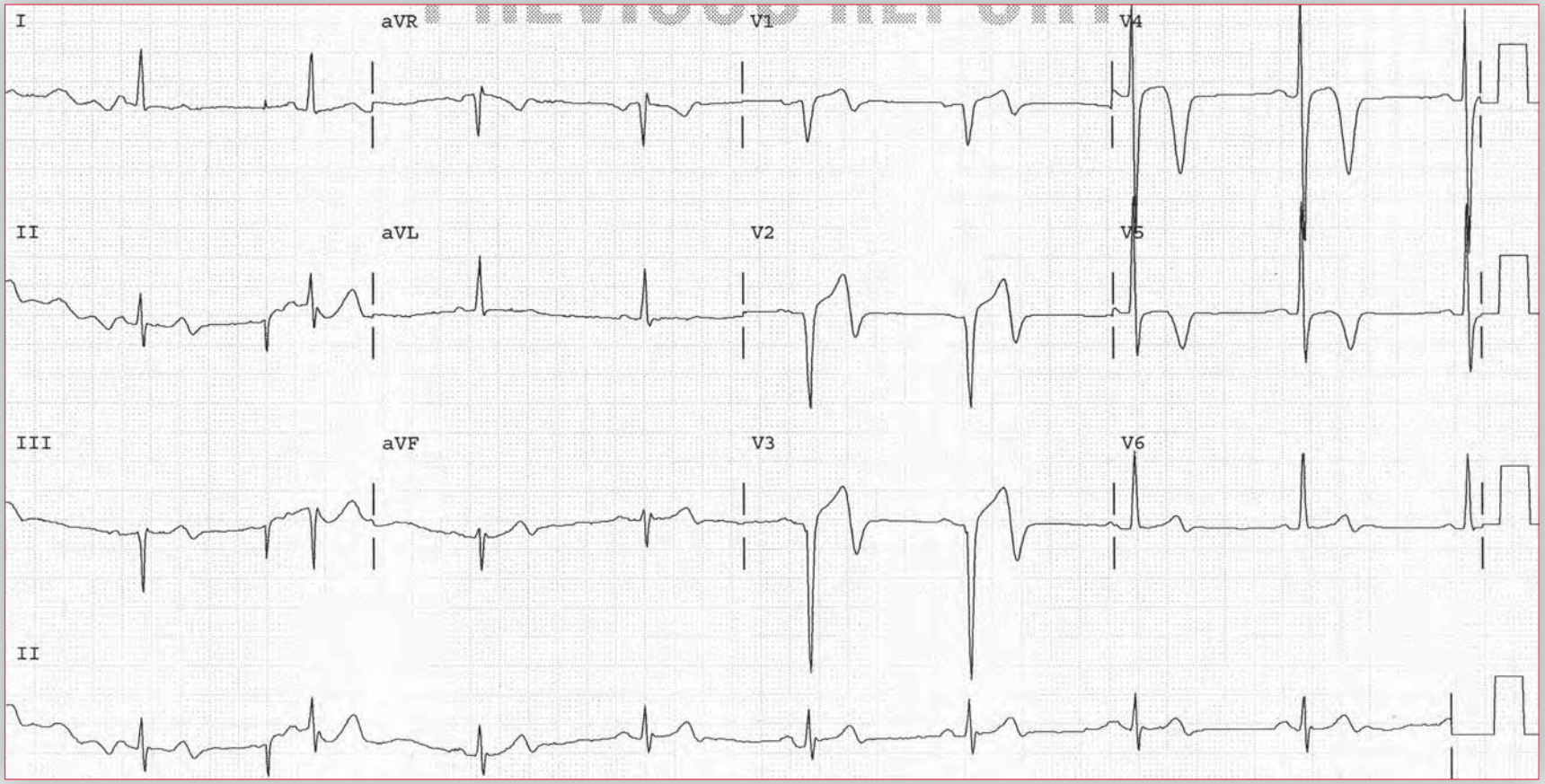

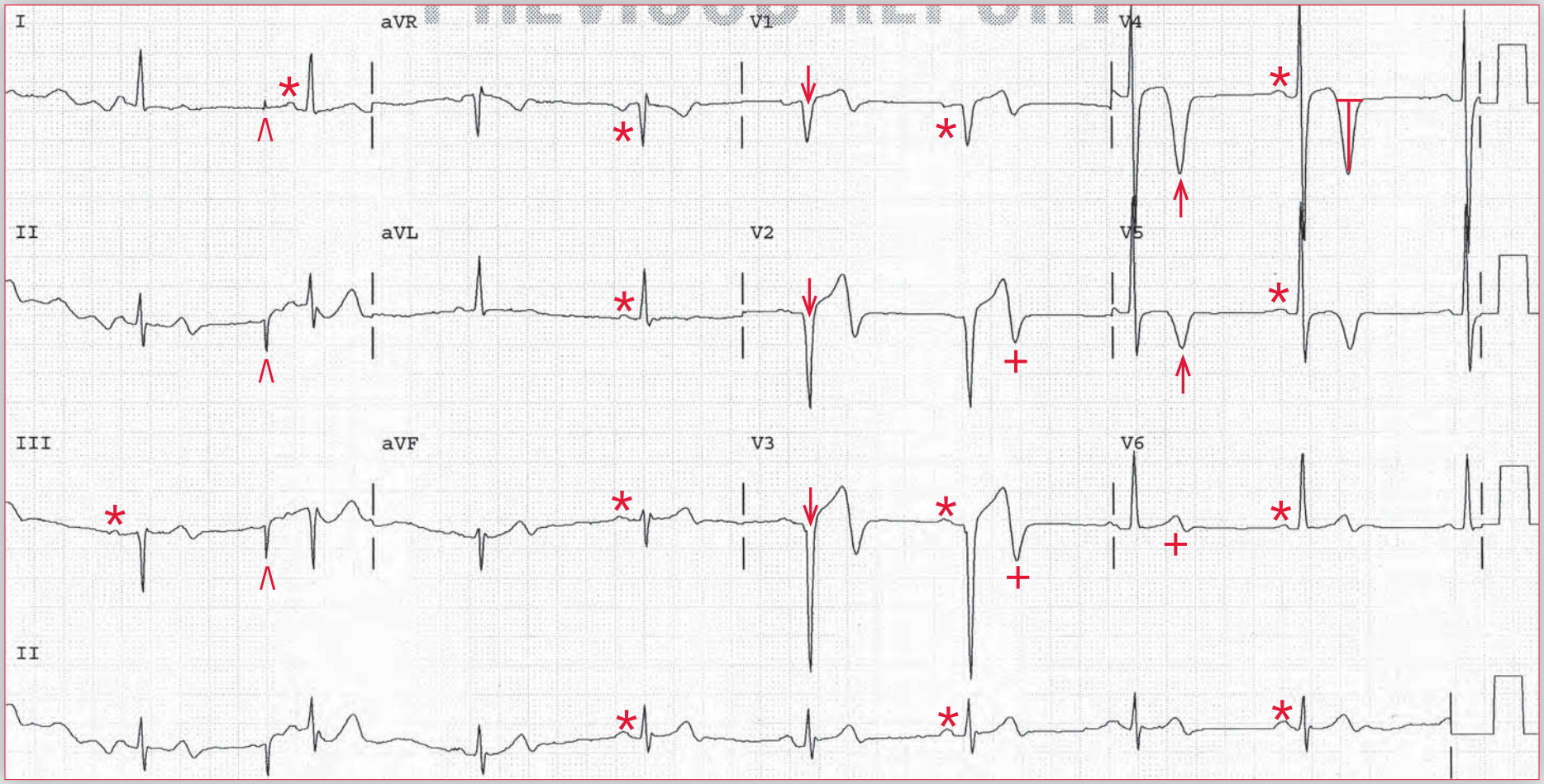

ECG 90 Analysis: Sinus bradycardia, old anteroseptal myocardial infarction (MI), nonspecific T-wave abnormalities

There is a regular rhythm at a rate of 54 bpm. The "waveform" seen between the first and second QRS complexes is artifact (^). There is a P wave (*) before each QRS complex, with a stable PR interval (0.18 sec). The P waves are positive in leads I, II, aVF, and V4-V6 and negative in lead aVR. The P-wave morphology is normal. This is sinus bradycardia.

The QRS complex duration is normal (0.10 sec), and the axis is physiologically leftward, between 0° and –30° (positive QRS complex in leads I and II and negative QRS complex in lead aVF). The QT/QTc intervals are normal (470/440 msec). There are no R waves (↓) in leads V1-V3 (hence QS complexes), diagnostic for an old anteroseptal myocardial infarction (MI).

The T waves are abnormal and are biphasic in leads V1-V3 and V6 (+), while they are inverted in leads V4-V5 (↑). The T waves are asymmetric in morphology. These are, therefore, nonspecific T-wave abnormalities and they may be seen in various conditions, including ischemia, myocarditis/pericarditis, metabolic or pH abnormalities, old MI, or left ventricular hypertrophy; they may also be seen in healthy subjects as a normal variant. T-wave abnormalities must be considered along with a clinical history. In this case of diabetic ketoacidosis, these T-wave abnormalities are likely due to profound metabolic disarray and acidosis. With several days of supportive care and resolution of the metabolic disturbance, these ECG changes will likely resolve. ■

Notes

Practice Case 91

A 38-year-old man is involved in a high-speed motor vehicle accident. He suffered a chest contusion against the steering wheel and blunt head trauma. Upon arrival to the emergency department he is somnolent and hypotensive.

What does his ECG show?

What is the likely diagnosis?

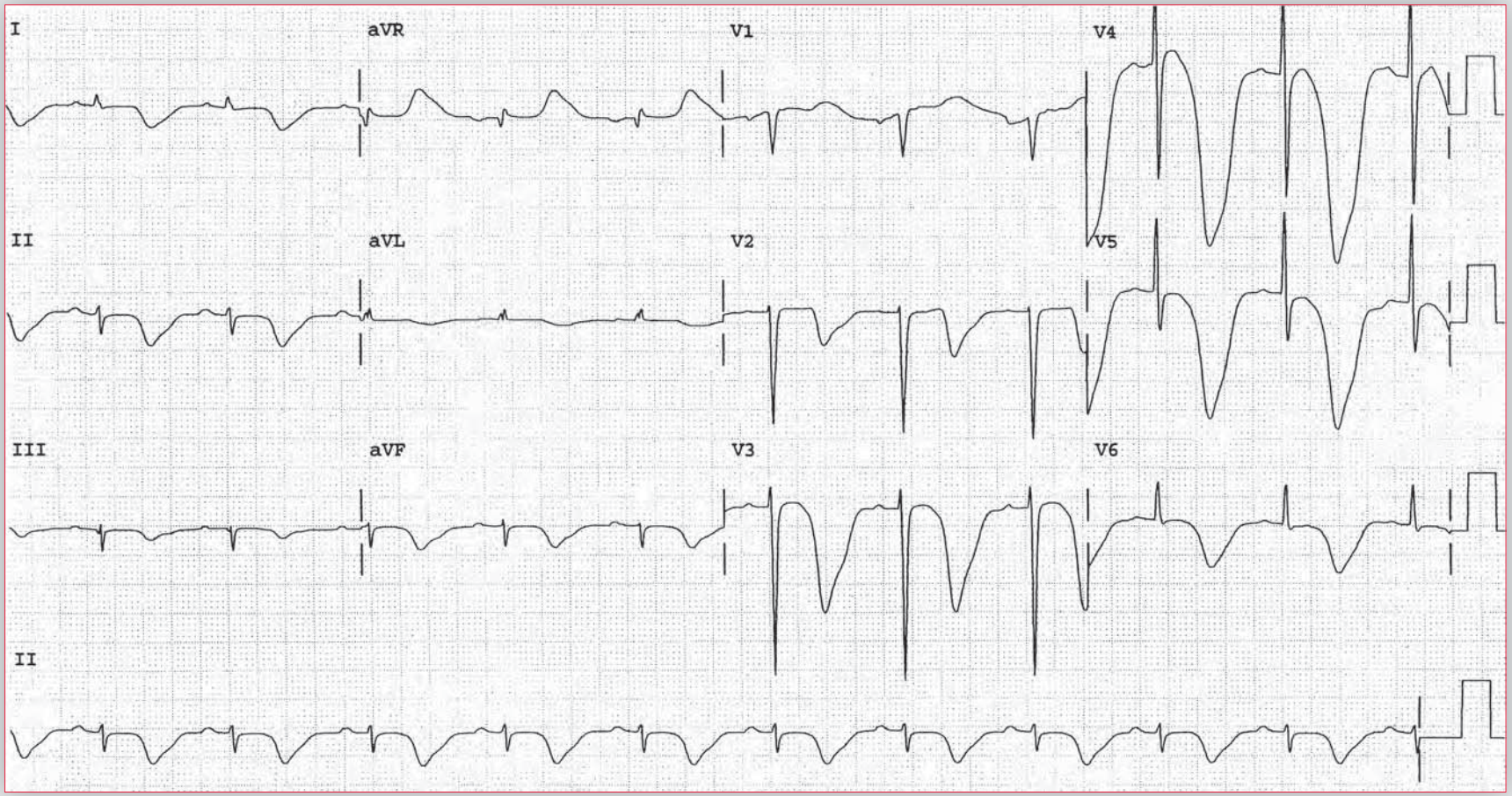

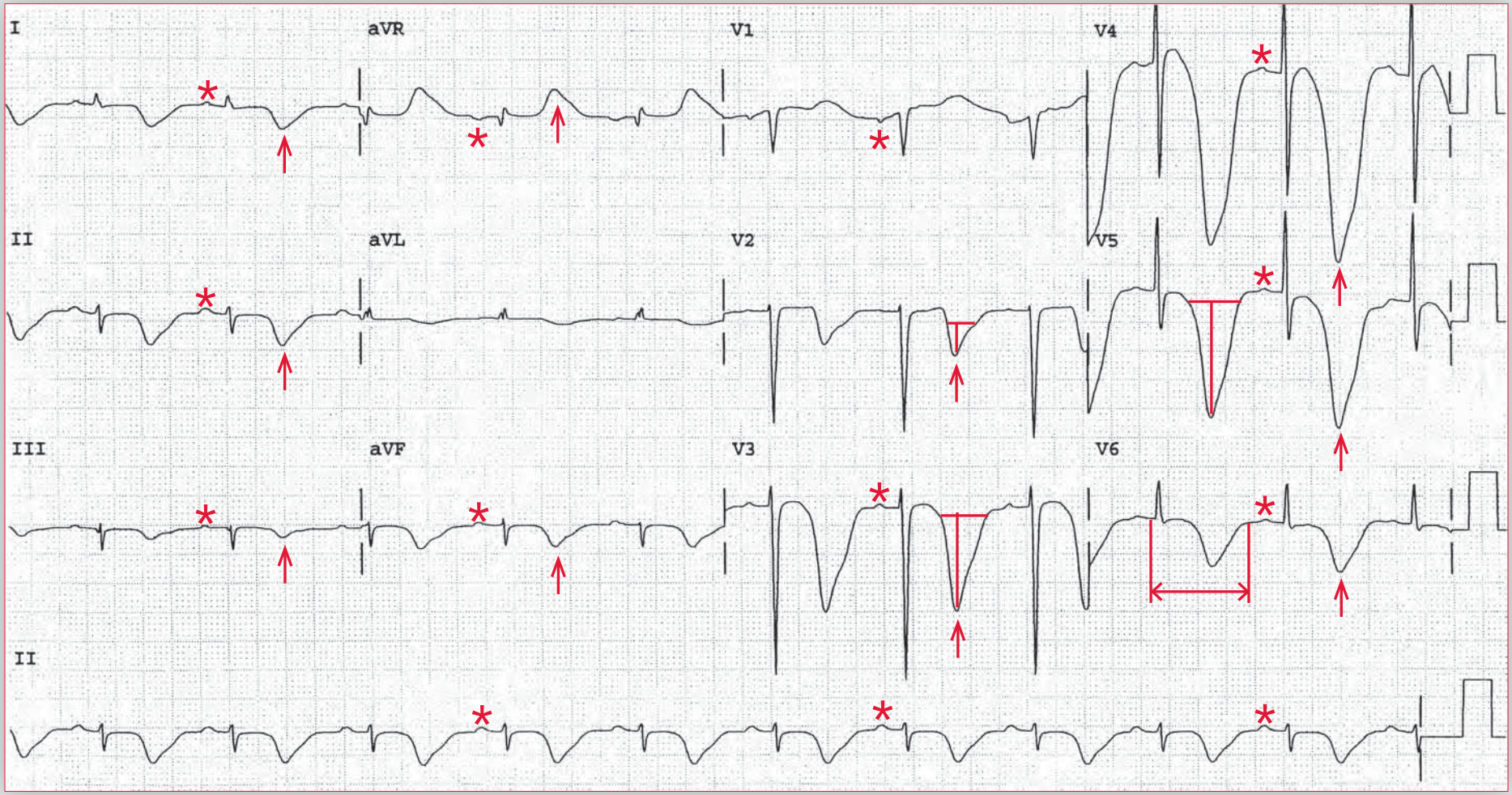

ECG 91 Analysis: Normal sinus rhythm, left anterior fascicular block, prolonged QT interval, cerebral T waves

There is a regular rhythm at a rate of 66 bpm. There are P waves (*) before each QRS complex, and the P waves are positive in leads I, II, aVF, and V4-V6 and negative in lead aVR. The P-wave morphology is normal. This is a normal sinus rhythm.

The QRS complex duration is normal (0.08 sec), and there is an extremely left axis deviation, between –30° and –90° (positive QRS complex in lead I and negative QRS complex in leads II and aVF, with an rS morphology). This is a left anterior fascicular block. An inferior wall myocardial infarction may also be associated with an extreme left axis deviation; however, the QRS complexes would have a deep initial Q wave. The QRS morphology is normal. Deeply inverted and asymmetric T waves (↑) are seen in most leads (the T wave in lead aVR should be negative). Unlike the normal T wave, which has a slower initial portion or upstroke (ascent) and a faster terminal portion or downstroke (descent), the initial portion (descent) of the T wave is more rapid than the terminal portion (ascent) of the T wave. The ST segment is not depressed, and the QT/QTc intervals are prolonged (↔) (620/650 msec). These T-wave abnormalities, associated with the QT interval prolongation, are suggestive of cerebral T waves, a result of a central nervous system process such as a subarachnoid hemorrhage, cerebral hemorrhage, tumor, head injury, or infection.

This patient likely has these ECG changes on the basis of his head injury and possible intracranial bleed. He will require therapy to lower his intracranial pressure, including elevation of the head of the bed, mannitol infusion, hyperventilation, and possible surgical evacuation. The clinician should also be mindful of the possibility of traumatic injury to the heart or coronary arteries. Aortic dissection, coronary artery dissection, or cardiac contusion could be caused by blunt chest trauma and could produce a similar ECG pattern, although if this were the result of myocardial ischemia, the ST segments would be depressed and the T waves would be symmetric. ■

Practice Case 92

A 56-year-old man with hypertension but no cardiac history has been treated with lisinopril and hydrochlorothiazide for the past 4 years. He states that his blood pressure has been well controlled whenever measured. He presents with a complaint of headache

ECG 92A

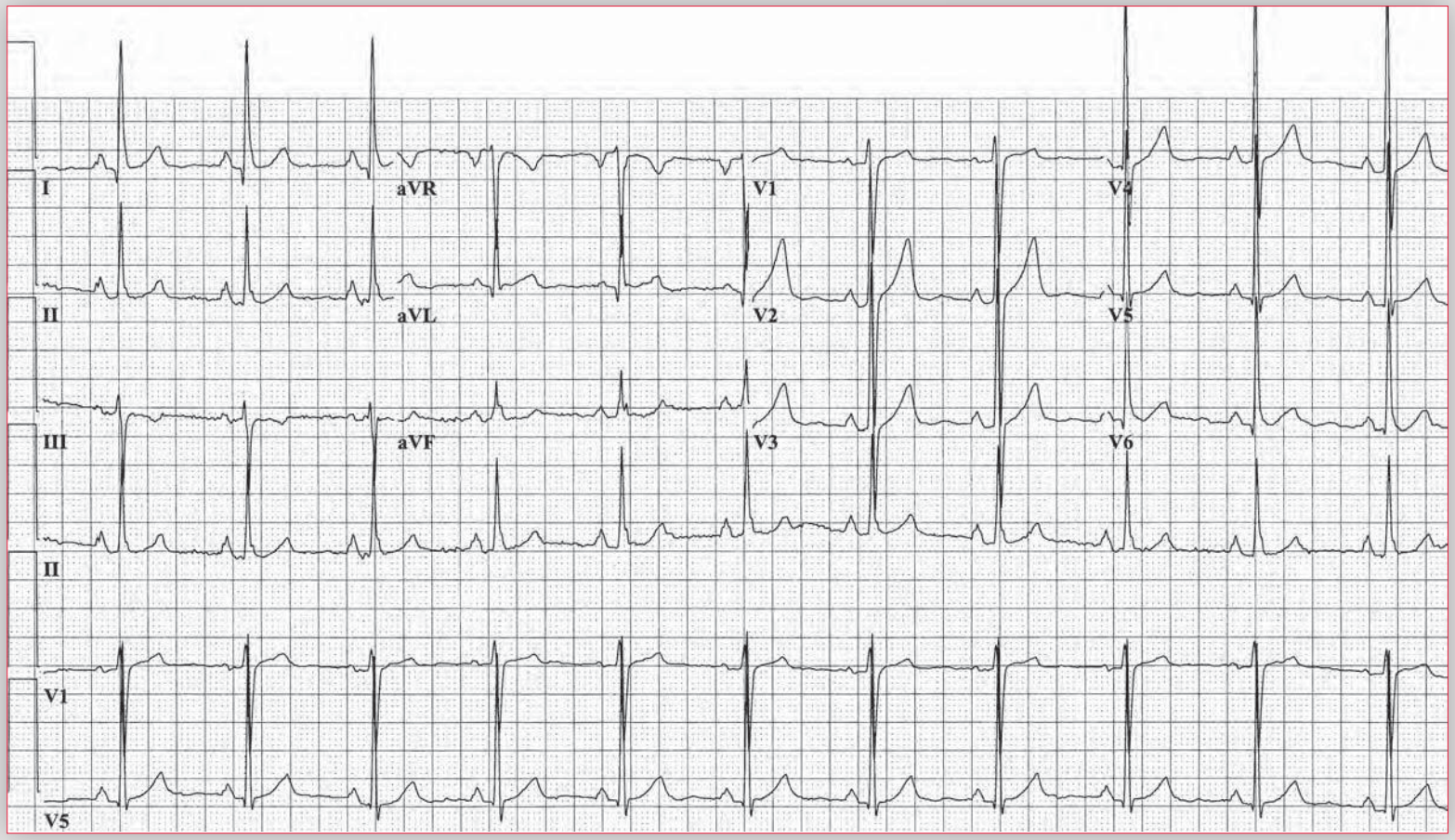

associated with sinus congestion and a productive cough associated with chest pain. His physical examination is unremarkable, with a blood pressure of 160/80 mm Hg. The ECG (92A) that is obtained during this visit is found to be different from that obtained 1 year earlier (ECG 92B).

What abnormality on the current ECG is a cause for concern?

What is the change between the two ECGs?

Is any additional evaluation necessary?

ECG 92B

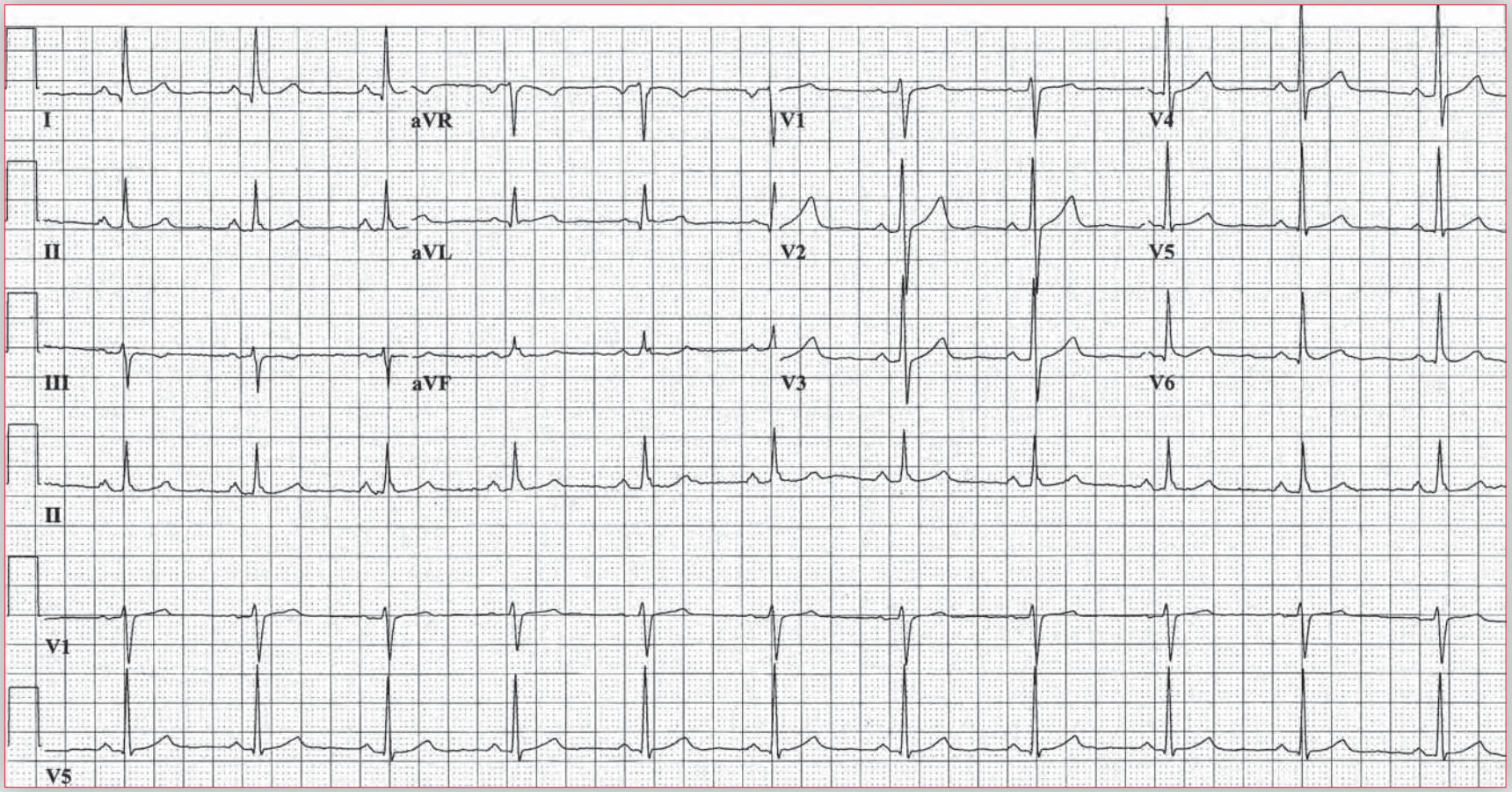

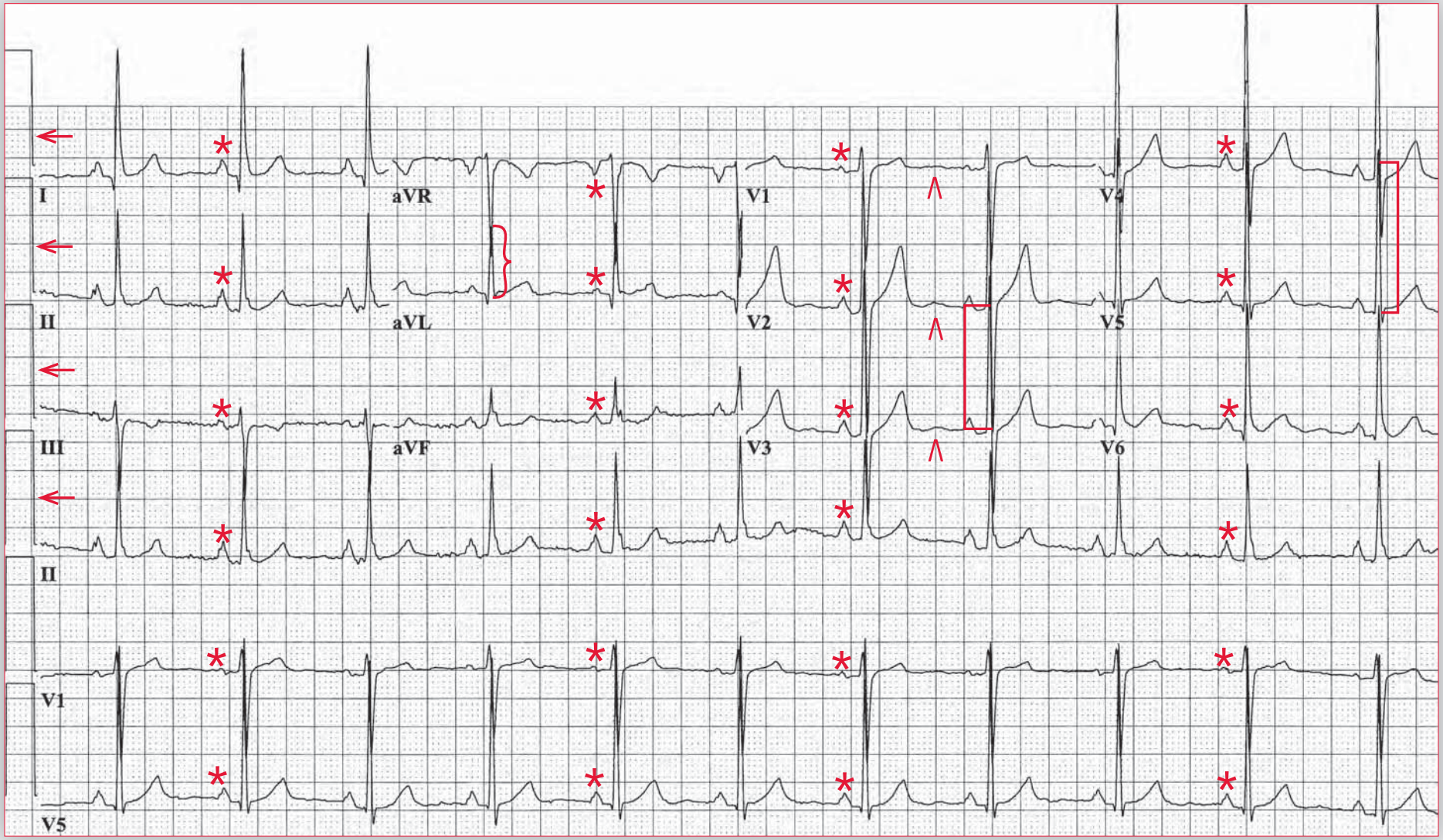

ECG 92A Analysis: Normal sinus rhythm, tall QRS voltage, ECG recorded at double standard

ECG 92A shows a regular rhythm at a rate of 66 bpm. There are P waves (*) before each QRS complex, with a stable PR interval (0.20 sec). The P waves are positive in leads I, II, aVF, and V4-V6. The P-wave morphology is normal. This is a normal sinus rhythm. The axis is normal, between 0° and +90° (positive QRS complex in leads I and aVF). The QT/QTc intervals are normal (380/400 msec). U waves (^) are seen in leads V1-V3.

The QRS complex duration (0.08 sec) and morphology are normal. However, the QRS complex amplitude is increased; the R-wave amplitude is 28 mm in lead V5 ( ]), and the S-wave depth is 22 mm in lead V2 ([ ). This meets a criterion for left ventricular hypertrophy (*ie*, S-wave depth in lead V2 + R-wave amplitude in lead V5 ≥ 35 mm). In addition, the R-wave amplitude (voltage) in lead aVL (}) is 13 mm, also a criterion for left ventricular hypertrophy (*ie*, R-wave amplitude ≥ 11 mm).

continues

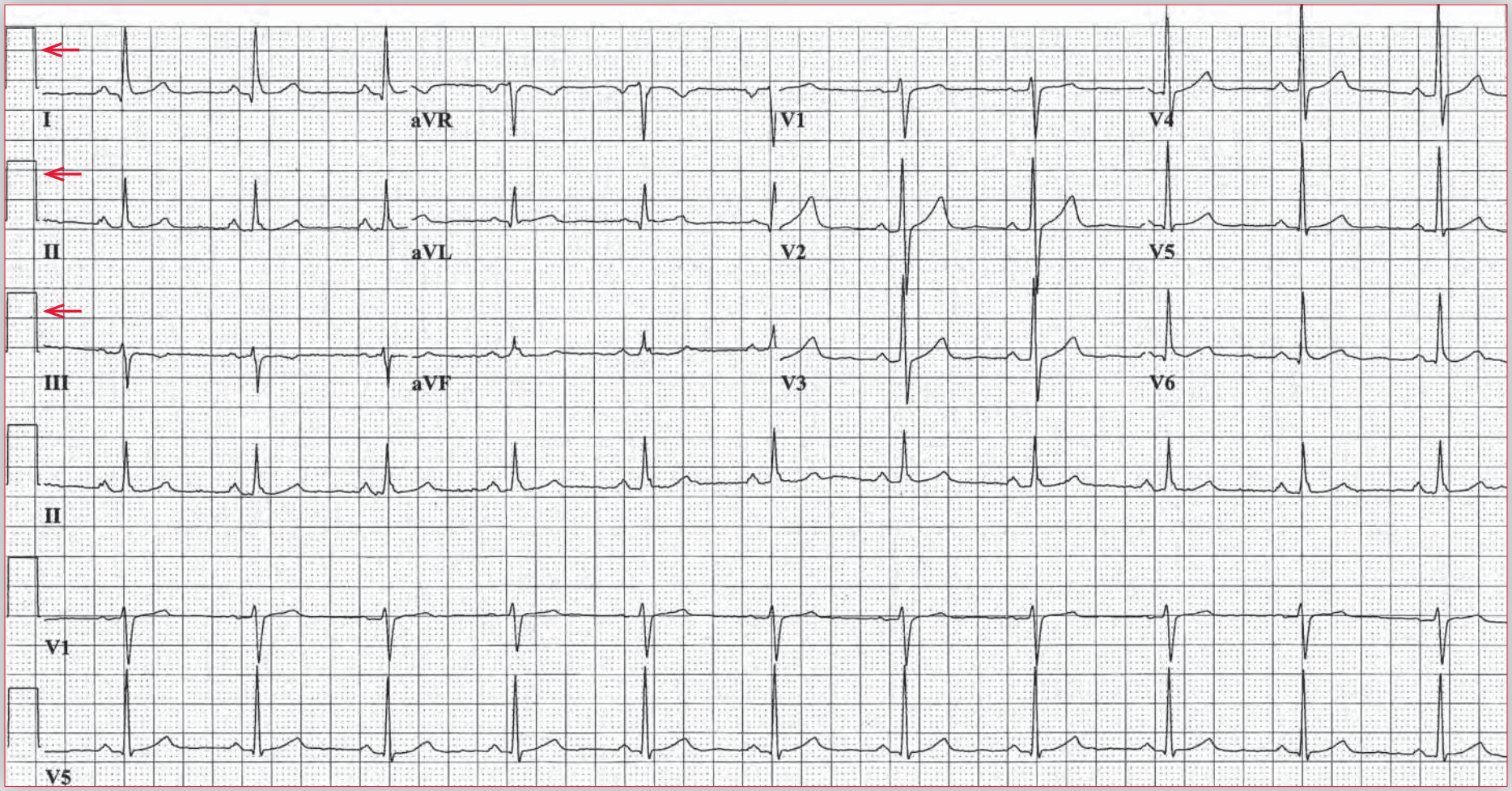

ECG 92B Analysis: Normal

When compared with **ECG 92B**, which was obtained 1 year earlier, the P waves, PR interval, QRS complex duration, QRS complex morphology, and axis are the same. However, there is a marked difference in the QRS complex amplitude, which was a cause for concern as it was believed that the patient's blood pressure was not well controlled and that he had developed left ventricular hypertrophy. However, closer examination of **ECG 92A** reveals that it was recorded at double standard (←). Therefore, the QRS amplitude is only half of what is measured. When this is taken into account, it can be seen that the QRS amplitude is normal and is identical to that noted in **ECG 92B**, which was recorded using normal standardization (←).

ECGs are generally recorded using normal standardization, that is, 1 mV of electrical current produces a signal that measures 10 mm in amplitude (or 10 small boxes). On occasion, however, the ECG will be recorded using double standard. This may be the case when the waveforms are very small and difficult to interpret or if waveforms are not clearly seen and may become more apparent with an increased amplitude. Not uncommonly, the ECG is recorded using double standard by mistake, as appears to be the situation with this patient. Once recognized, it is clear that there has not been any change in the ECG compared with 1 year earlier. Hence there is no left ventricular hypertrophy and no additional evaluation or therapy is necessary. An ECG recorded at normal standardization could be obtained in order avoid confusion in the future. ■

Notes

Index

A

acute anterior wall myocardial infarction, 112–113
acute anterior wall ST-segment elevation myocardial infarction, 120–121, 124–125, 128–129, 236–237, 240–241, 292–293, 350–351
acute anteroapical ST-segment elevation myocardial infarction, 121, 386–387
acute coronary syndrome, 39, 51, 307, 355, 359
acute inferior wall ST-segment elevation myocardial infarction, 136–137, 140–141, 146–147, 148–149, 313–314, 330–331, 378–379
acute inferior wall transmural ischemia caused by vasospasm, 152–153
acute lateral wall ST-segment elevation myocardial infarction, 158–159, 350–351
acute myocardial infarction, 73
  in left bundle branch block, 159
amyloid cardiomyopathy, 27
aneurysm
  anteroapical, 175
  ST-segment elevation caused by, 132–133
angina
  left ventricular hypertrophy and, 24
  Prinzmetal's, 152, 155, 351
  variant, 152, 155
  vasospastic, 155
antegrade conduction, 225
anterior wall myocardial infarction, 112–114, 132–133, 163, 186–187, 264–265, 276–277, 296–297, 390–391
anteroapical aneurysm, 175
anteroapical myocardial infarction, 9–10, 106–107, 114, 163, 166–167, 174–175, 178–179, 182–183, 306–307
anterolateral myocardial infarction, 9–10, 106–107, 114, 163, 166–167, 322–323
anteroseptal myocardial infarction, 9–10, 114, 125, 163, 166–167, 174–175, 252–253, 284–285, 306–307, 398–399
atrial arrhythmias, 77
atrial fibrillation, 200–201

B

biatrial hypertrophy, 34–35, 64–65, 296–297, 358–359
bifascicular block, 174–175
biphasic T waves, 141, 220–221

C

cardiac ischemia, 51, 87, 91, 102–103
cerebral T waves, 230–231, 402–403
chronic hypoxia, 32
clockwise rotation (late transition), 26–27
complete heart block, 35, 285
conduction disease, 175
cor pulmonale, 65
coronary artery disease, 91, 95, 383
coronary artery vasospasm, 155, 351
counterclockwise rotation, 140–141, 146–147, 166–167, 170–171, 190–191, 272–273, 310–311, 330–331, 346–347, 366–367

D

demand ischemia, 97
dextrocardia, 281
downsloping ST-segment depression, 7, 8, 87, 94–95, 300–301, 354–355
Dressler's syndrome, 197
drug-induced pericarditis, 249

E

early repolarization, 6, 22–23, 72–73, 204–205, 208–209, 272–273, 370–371
ECG
  at double standard, 54–55
  at normal standard, 56
exercise-induced ST-segment elevation
  ischemia as cause of, 102–103
  wall motion abnormality as cause of, 108–109

F

first-degree AV block, 26–27, 38–39, 128–129, 158–159, 166–167, 174–175, 182–183, 386–387

H

His-Purkinje system, 217, 285, 391
horizontal ST-segment depression, 7, 8, 87, 90–91, 256–257
hyperacute T waves, 112–113, 116–117, 121, 212–213, 292–293
hypercalcemia, 113
hyperkalemia, 113, 117, 121, 212–213
hypertrophic cardiomyopathy, 319
hypokalemia, 15
hypotension, 143, 379
hypoxia, 277

I

infarction pericarditis, 197
inferior wall myocardial infarction, 9–10, 106–107, 114, 116–117, 136–137, 162–163, 166–167, 170–171, 186–187, 196–197, 252–253, 268–269, 296–297, 366–367
intraventricular conduction delay, 64–65, 106–107, 166–167, 224–225, 264–265, 326–327, 346–347, 378–379, 390–391
ischemia, 51, 87, 91, 102–103
  myocardial, 7–8, 43, 97, 121, 227
  subendocardial, 2, 6, 8, 24, 97, 109
ischemic cardiomyopathy, 167
ischemic T-wave abnormalities, 226–227

J

J point, 2, 7-8, 84, 95, 197
junctional tachycardia, 154–155, 248–249

L

lateral myocardial infarction, 9, 114, 128–129, 163, 182–183, 240–241, 322–323, 390–391
left anterior fascicular block, 26–27, 42–43, 132–133, 174–175, 244–245, 367, 390–391, 402–403
left atrial hypertrophy
causes of, 19
diagnostic criteria for, 4–5
ECG findings, 18–19, 22–23, 26–27, 34–35, 38–39, 50–51, 64–65, 100–101, 128–129, 140–141, 182–183, 224–225, 240–241, 244–245, 252–253, 268–269, 296–297, 342–343, 350–351, 358–359
Romhilt-Estes criteria for, 3, 19, 23, 39, 347
left bundle branch block, 159, 391
left posterior fascicular block, 31, 183, 281
left ventricular aneurysm, 133, 264–265, 276–277
left ventricular hypertrophy
angina associated with, 24
concentric, 23
diagnostic criteria for, 1–2
ECG findings, 1–2, 18–19, 22–23, 38–39, 42–43, 46–47, 50–51, 64–65, 205, 208–209, 244–245, 310–311, 326–327, 336–337, 340–343, 346–347, 354–355, 370–371, 382–383
pathologic, 209
physiologic, 209
repolarization abnormalities associated with, 51
with ST-T wave changes, 50–51
left axis deviation, 90–91, 200–201, 230–231, 264–265, 276–277, 288–289
limb leads, low-voltage, 26–27, 90–91, 386–387
Lown-Ganong-Levine pattern, 358–359

M

multivessel coronary artery disease, 91
myocardial fibrosis, 175
myocardial infarction
acute, 6, 8–9
aneurysm and, 113
anterior wall, 112–114, 132–133, 163, 186–187, 264–265, 276–277, 296–297
anteroapical, 9–10, 106–107, 114, 163, 166–167, 174–175, 178–179, 182–183, 306–307
anterolateral, 9–10, 106–107, 114, 163, 166–167, 322–323
anteroseptal, 9–10, 114, 125, 163, 174–175, 252–253, 284–285, 306–307
chronic, 9–10
diagnostic criteria for, 8–10
inferior wall, 9–10, 106–107, 114, 116–117, 136–137, 162–163, 166–167, 170–171, 186–187, 196–197, 252–253, 268–269, 296–297, 366–367
inferoposterior, 171
lateral, 9–10, 114, 128–129, 163, 166–167, 182–183, 240–241, 322–323
old, 106–107, 132–133, 162–163, 166–167, 170–171, 174–175, 240–241, 252–253, 268–269, 322–323, 366–367
pericarditis associated with, 197
posterior, 9, 10, 164, 166–167, 170–171, 192–193
Q-wave, 6
ST-segment elevation, 114
transmural, 113, 117
myocardial ischemia, 7–8, 43, 97, 121, 227
myocardial necrosis, 179
myocarditis, 10
myonecrosis, 125

N

nonspecific ST-segment abnormalities, 224–225, 374–375
nonspecific ST-T wave abnormalities, 244–245, 252–253, 284–285
nonspecific T-wave abnormalities, 178–179, 182–183, 216–217, 220–221, 366–367, 398–399
non–ST-segment elevation myocardial infarction, 97

O

old myocardial infarction, 106–107, 132–133, 162–163, 166–167, 170–171, 174–175, 240–241, 252–253, 268–269, 322–323, 366–367

P

P mitrale, 2, 4, 5
P pulmonale, 4, 5, 31, 69, 281
P wave
in left atrial hypertrophy, 19, 23
normal, 4
in sinus bradycardia, 23
pacemaker cells, 83
parasympathetic nervous system, 83
pericarditis, 6, 10, 73, 196–197, 200–201, 248–249, 260–261, 310–311, 394–395
postcardiac injury syndrome, 197
postcardiotomy syndrome, 197
posterior wall myocardial infarction, 9, 10, 166–167, 170–171, 192–193
PP interval, 225
PR depression, 261
PR interval, short, 358–359
premature atrial complexes
ECG findings, 76–77, 146–147, 158–159, 330–331
premature junctional complexes, 394–395
premature ventricular complexes, 158–159, 224–225, 230–231
Prinzmetal's angina, 152, 155, 351
pulmonary arterial hypertension, 32

Q

Q wave
abnormal, 163, 253
inferior, 197
septal, 213
QRS complex
low voltage, 6
normal, 15
right bundle branch block effects on, 125
in sinus bradycardia, 23
QT interval
normal, 15
prolonged, 212–213, 226–227, 230–231, 280–281, 288–289, 330–331, 358–359
QTc interval, 15

R

retrograde conduction, 225
right atrial hypertrophy
diagnostic criteria for, 5–6
ECG findings, 30–32, 34–35, 60–61, 64–65, 68–69, 280–281, 296–297, 306–307, 358–359
right axis deviation, 30–32, 68–69, 280–281
right bundle branch block
ECG findings, 124–125, 174–175, 322–323
QRS complex affected by, 125
right ventricular hypertrophy, 3–4, 30–32, 60–61, 64–65, 68–69, 245, 280–281, 362–363
right ventricular infarction, 142–143, 148–149, 332–333, 379

right-sided leads, 148–149, 332–333
right axis deviation
  causes of, 61, 65, 69, 183
  ECG findings, 60–61, 362–363
Romhilt-Estes criteria, 3, 19, 23, 39, 347

S

Sgarbossa criteria, 159
short PR interval, 358–359
sinus bradycardia
  definition of, 73
  ECG findings, 22–23, 72–73, 120–121, 166–167, 186–187, 204–205, 212–213, 230–231, 272–273, 336–337, 390–391, 398–399
sinus node, 83
sinus rhythm, normal, 14–15, 18
sinus tachycardia, 30–32, 34–35, 82–84, 90–91, 124–125, 152–153, 354–355, 374–375
sodium–potassium–ATPase pump, 8, 113
ST segment
  changes in, 6–7
  nonspecific, 76–77, 224–225, 374–375
  normal, 15
Stokes-Adams attacks, 285
ST-segment alternans, 152–153
ST-segment depression
  downsloping, 7, 8, 87, 94–95, 300–301, 354–355
  ECG findings, 50–51, 346–347
  horizontal, 8, 87, 90–91, 256–257, 382–383
  ischemia, 306–307, 358–359
  reciprocal, 117
  subendocardial ischemia and, 6
  upsloping, 7, 82–84, 86–87, 256–257
ST-segment elevation
  aneurysm as cause of, 132–133, 264–265
  exercise-induced, 102–103
  persistent, 276–277
ST-segment elevation myocardial infarction, 114
  acute anterior wall, 120–121, 124–125, 128–129, 236–237, 240–241, 292–293, 350–351
  acute anteroapical, 121
  acute inferior wall, 136–137, 140–141, 146–147, 148–149, 313–314, 330–331, 378–379
  acute lateral wall, 158–159, 350–351
  diagnostic criteria, 9
  left ventricular aneurysms associated with, 133
ST-T wave abnormalities, 100–101, 162–163, 284–285, 346–347
subendocardial ischemia, 2, 6, 7, 8, 24, 97, 109
sympathetic nervous system, 83

T

T wave
  asymmetric, 209
  biphasic, 141, 220–221
  cerebral, 230–231, 402–403
  hyperacute, 112–113, 116–117, 121, 212–213, 292–293
  ischemic abnormalities, 226–227
  nonspecific abnormalities, 178–179, 182–183, 216–217, 220–221, 366–367
  normal, 15, 209, 213
  prominent, 208–209
  Wellens', 226–227
tall QRS voltage, 204–205, 406–407
third-degree AV block, 35
"tombstone," 8, 129
transmural ischemia, 6, 103, 109, 121, 152–153, 155
transmural myocardial infarction, 113, 117
T-wave inversions
  description of, 163
  ECG findings, 102–103, 288–289, 318–319, 358–359
  ischemia, 102–103, 288–289

U

U wave
  description of, 54, 217
  ECG findings, 336–337
  normal, 15
  prominent, 72–73
upsloping ST-segment depression, 7, 82–84, 86–87, 256–257

V

variant angina, 152, 155
vasospasm
  acute inferior wall transmural ischemia caused by, 152–153
  coronary artery, 155, 351
vasospastic angina, 155
ventricular tachycardia, 35

W

wall motion abnormality, exercise-induced ST-segment elevation caused by, 108–109
Wellens' T waves, 226–227
Wolff-Parkinson-White pattern, 4, 10, 31, 61, 65, 69, 183, 281, 363

Notes

Notes

Podrid's Real-World ECGs combines traditional case-based workbooks with a versatile Web-based program to offer students and physicians an indispensable resource for developing the technical skills and systematic approach needed to interpret ECGs with confidence.

ECGs from real patient cases offer an in-depth learning experience by focusing on fundamental electrophysiologic properties and clinical concepts as well as detailed discussion of important diagnostic findings and relevant management decisions.

Six volumes encompass more than 600 individual cases—plus an online repository of hundreds more interactive case studies that include feedback and discussion about the important waveforms and clinical decision-making involved.

Volume 2, Myocardial Abnormalities breaks down the essential skills necessary for diagnosing acute myocardial ischemia as well as acute and chronic myocardial infarction—arguably the most important component of the ECG armamentarium across the spectrum of health care professions. It also demonstrates the skills needed for the diagnosis of myocardial hypertrophy, atrial abnormality, and pericarditis.

Philip Podrid, MD
Boston University School of Medicine
Harvard Medical School
Boston, Massachusetts
West Roxbury VA Hospital
West Roxbury, Massachusetts

Rajeev Malhotra, MD, MS
Rahul Kakkar, MD
Peter A. Noseworthy, MD
Massachusetts General Hospital
Harvard Medical School
Boston, Massachusetts

Includes free 1-year access to additional practice cases at www.realworldECGs.com

Podrid's Real-World ECGs:
A Master's Approach to the Art and Practice of Clinical ECG Interpretation

Volume 1	The Basics
Volume 2	Myocardial Abnormalities
Volume 3	Conduction Abnormalities
Volume 4	Arrhythmias
Volume 5	Narrow and Wide Complex Tachycardias
Volume 6	Paced Rhythms, Congenital Abnormalities, Electrolyte Disturbances, and More

Dr. Philip Podrid is known worldwide as an expert in electrocardiography. He is also a superb teacher. When you combine his input with beautiful ECGs, not surprisingly, you will have a series of "Real-World ECGs" that demonstrate the art and practice of clinical ECG interpretation as only a real master can.

—From the Foreword by *Hein J. Wellens, MD*

ISBN: 978-1-935395-03-4
9 0000
9 781935 395034

cardiotext PUBLISHING
3405 W. 44th Street
Minneapolis, Minnesota 55410
www.cardiotextpublishing.com
(888) 999-9174

uploaded by [stormrg]